## RENAL AND MESENTERIC ARTERIAL DISEASE

The following is one of three extracted sections—lower extremity, renal/mesenteric, and abdominal aortic—of the ACC/AHA 2005 Guidelines for the Management of Patients With Peripheral Arterial Disease (Lower Extremity, Renal, Mesenteric, and Abdominal Aortic): A Collaborative Report from the American Association for Vascular Surgery/Society for Vascular Surgery, Society for Cardiovascular Angiography and Interventions, Society for Vascular Medicine and Biology, Society of Interventional Radiology, and the ACC/AHA Task Force on Practice Guidelines (Writing Committee to Develop Guidelines for the Management of Patients With Peripheral Arterial Disease). We have separated and posted each section online to facilitate easy downloading by specialists interested in a specific portion of the guideline; however, it is important that when citing the guidelines, the full-text document of record be cited as Hirsch AT, Haskal ZJ, Hertzer NR, et al. Peripheral Arterial Disease: ACC/AHA 2005 Guidelines for the Management of Patients With Peripheral Arterial Disease (Lower Extremity, Renal, Mesenteric, and Abdominal Aortic): A Collaborative Report From the American Association for Vascular Surgery/Society for Vascular Surgery, Society for Cardiovascular Angiography and Interventions, Society for Vascular Medicine and Biology, Society of Interventional Radiology, and the ACC/AHA Task Force on Practice Guidelines (Writing Committee to Develop Guidelines for the Management of Patients With Peripheral Arterial Disease). J Am Coll Cardiol 2006;47:1239-312. The full-text guidelines are available at http://www.acc.org/clinical/guidelines/pad/index.pdf, and an executive summary is available at http://www.acc.org/clinical/guidelines/pad/index.pdf. Please note that these sections were not written as stand-alone documents and therefore may reference tables and figures not appearing in this section. Readers should make a concerted effort to ensure that they have reviewed any pertinent information related to this subject that may be located in another section.

A classification of recommendation and a level of evidence have been assigned to each recommendation. Classifications of recommendations and levels of evidence are expressed in the ACC/AHA format as follows.

### Classification of Recommendations

**Class I: Conditions for which there is evidence for and/or general agreement that a given procedure or treatment is beneficial, useful, and effective.**

**Class II: Conditions for which there is conflicting evidence and/or a divergence of opinion about the usefulness/efficacy of a procedure or treatment.**

**Class IIa: Weight of evidence/opinion is in favor of usefulness/efficacy.**

**Class IIb: Usefulness/efficacy is less well established by evidence/opinion.**

**Class III: Conditions for which there is evidence and/or general agreement that a procedure/treatment is not useful/effective and in some cases may be harmful.**

### Level of Evidence

- Level of Evidence A: Data derived from multiple randomized clinical trials or meta-analyses.
- Level of Evidence B: Data derived from a single randomized trial or nonrandomized studies.
- Level of Evidence C: Only consensus opinion of experts, case studies, or standard-of-care.

The ACC/AHA Task Force on Practice Guidelines makes every effort to avoid any actual, potential, or perceived conflicts of interest that might arise as a result of an outside relationship or personal interest of a member of the writing panel. Specifically, all members of the writing panel are asked to provide disclosure statements of all such relationships that might be perceived as real or potential conflicts of interest. These statements are reviewed by the parent task force, reported orally to all members of the writing panel at each meeting, and updated and reviewed by the writing committee yearly and as changes occur. Appendixes 1 and 2 contain information on author relationships with industry for authors and peer reviewers, respectively, and are attached to this extracted section for the convenience of the reader. The complete reference list of the full-text guidelines is also included in this document.

The Committee to Develop Guidelines for Peripheral Arterial Disease conducted comprehensive searching of the scientific and medical literature relevant to peripheral arterial disease (PAD). Please see the Preamble to the full-text guidelines for information on the ACC/AHA methodology specific to this guideline.

These guidelines were approved for publication by the governing bodies of the American College of Cardiology (ACC) and the American Heart Association (AHA) and have been officially endorsed by the following collaborating organizations: Society for Cardiovascular Angiography and Interventions; Society for Vascular Medicine and Biology; Society for Vascular Surgery; and Society of Interventional Radiology; as well as by the American Association of Cardiovascular and Pulmonary Rehabilitation; National Heart, Lung, and Blood Institute; Society for Vascular Nursing; TransAtlantic Inter-Society Consensus; and Vascular Disease Foundation.

## TABLE OF CONTENTS



## 3. RENAL ARTERIAL DISEASE

### *3.1. Prevalence and Natural History*

Renal artery stenosis (RAS) is both a common and a progressive disease in patients with atherosclerosis and is a relatively uncommon cause of hypertension (612-614). Although excellent prevalence data have been obtained in selected high-risk populations (e.g., patients with clinically evident coronary artery disease or PAD) (615-619), few studies have adequately assessed the prevalence of RAS in the general population (620). Hansen and associates studied prevalence by performing renal artery duplex ultrasound in individuals 65 years and older as part of their cardiovascular health study to determine the population-based prevalence of renovascular disease. Of 834 participants undergoing renal artery duplex ultrasound, the overall prevalence rate of significant renovascular disease was 6.8%. Renal artery disease was present in 5.5% of women, 9.1% of men, 6.9% of white participants, and 6.7% of black participants (620).

Renal artery stenosis is particularly notable in certain high-risk populations. Renal arterial disease has been documented to be present in 30% of patients undergoing screening renal artery angiography at the time of cardiac catheterization. In these cohorts, significant obstructive renal artery stenoses (i.e., greater than 50%) have been reported in 11% to 18% of patients (621-623). Prevalence studies have also demonstrated significant RAS in 22% to 59% of patients with PAD (616-619,624-630). In one necropsy study, RAS greater than 50% was found in 53% of 295 unselected, consecutive examinations (631). This high prevalence increased to 74% when a subpopulation of individuals 70 years and older was evaluated postmortem. A second autopsy series evaluated 297 patients with proven MI to document atherosclerotic RAS of greater than 75% in 12% (615). Bilateral RAS involvement is common. In 6 different studies, bilateral RAS was found in 44% of 319 patients (632). Overall, these data suggest that if 1 or more clinical clues to the presence of RAS are present, significant RAS can be found in up to 70% of such targeted populations (625). Despite the high prevalence of RAS in these atherosclerotic subgroups, it remains controversial as to which lesions are associated with important clinical sequelae.

Atherosclerotic RAS is a progressive disease. In 4 retrospective studies comprising 202 patients followed up for 12 to 60 months, temporal progression of the degree of stenosis occurred in 36% to 71% of patients, and renal artery occlusion occurred in 16% (633-636). Progression to occlusion is more common in renal arteries with more severe stenoses. When the RAS was greater than 75% at the time of diagnosis, occlusion occurred in 39% of cases over a 12- to 60-month follow-up period (635).

Several prospective natural history studies have described the progression of RAS. In a series published by Dean and

coworkers, RAS progressed in 29% (10 of 35) of patients and resulted in total occlusion in 11% of patients during a mean follow-up of 28 months (range 6 to 102 months) (637). Over a 3-year period, Zierler and associates found that 48% of patients had progression of RAS from less than 60% to greater than or equal to 60% stenosis (638). The renal arteries that progressed to occlusion were each characterized by a stenosis greater than or equal to 60% at baseline (study entry). Progression of RAS occurred at an average rate of approximately 7% per year. Using sonography, Caps et al. monitored 295 kidneys in 170 patients for a mean of 33 months (639). Disease progression, based on sonographic determination, was 35% at 3 years and 51% at 5 years. Nine renal artery occlusions (3%) occurred over the course of the study. All occlusions developed in patients with greater than 60% stenosis in the study that preceded the occlusion. Occlusion occurred most often in patients with diabetes, high-grade stenoses, and severe hypertension (639).

### 3.1.1. Clinical End Points of Renal Artery Disease

The exact contribution of atherosclerotic renal arterial disease to the development of end-stage renal disease (ESRD) is not well-defined by current data. It is unclear how many patients enter dialysis secondary to RAS. Mailloux and colleagues reviewed the causes of ESRD in 683 patients entered into their dialysis program over a 20-year period (640). Eighty-three patients (12%) had documented RAS as a cause of ESRD. Because these investigators only performed arteriography in patients in whom RAS was highly suspected, it is possible that the true incidence was underestimated. Although the degree of global atherosclerotic risk factor control was variable in these studies, these data demonstrate that the atherosclerotic process remains dynamic and progressive in many individuals. The clinical significance of isolated anatomic progression without clinical clues or indications for intervention is still unclear.

Renal atrophy is a consequence of RAS and is associated with lesion severity and lesion progression (641,642). Several studies have documented worsening clinical outcomes (i.e., deterioration of renal function, loss of renal mass, and lower survival rates) in patients with progressive RAS (637,641,643). One prospective study evaluated renal function in 41 patients with atherosclerotic RAS treated with medical therapy (637). At a mean follow-up of 28 months (range 6 to 102 months), 19 patients (46%) had increased serum creatinine, 12 (29%) had a 25% to 50% decline in glomerular filtration rates, and 14 (37%) had a decrease in kidney size by more than 10% (637). Investigators at Duke University demonstrated progression of RAS in patients undergoing 2 sequential cardiac catheterizations separated by 2.6 plus or minus 1.6 years (643). They observed an overall rate of RAS progression of 11.1% and a significant decline in renal function in those patients who had lesion progression.

Amongst the most clinically relevant end points for individuals with chronic renal disease is the rate of progression to renal replacement therapies. Dialysis-free survival (patients alive and free of dialysis) is inversely correlated with the severity of renal ischemia. In one study, 2-year dialysis-free survival was 97.3% for patients with unilateral RAS and 82.4% for patients with bilateral RAS but only 44.7% in patients with renovascular disease in a solitary (single) functioning kidney (641).

Patients with atherosclerotic RAS who progress to ESRD and require dialysis have high mortality rates. In one study, the mean life expectancy of individuals older than 65 with RAS who had ESRD was only 2.7 years (644). The median survival for ESRD patients with renovascular disease was 25 months, compared with 55 months for patients with ESRD due to malignant hypertension and 133 months for patients with ESRD due to polycystic kidney disease (645). This is suspected to be due to the systemic atherosclerotic burden and higher rates of cardiovascular ischemic events in those individuals with atherosclerotic RAS. Two-, 5-, and 10-year survival rates were 56%, 18%, and 5%, respectively, in individuals with atherosclerotic RAS. Prospective, randomized, controlled trials will be required to determine whether the early diagnosis of RAS will provide an opportunity for the prevention of ESRD and identify individuals at high cardiovascular risk.

The presence and severity of RAS, even before the development of ESRD, imparts a poorer prognosis. In a series of almost 4000 patients undergoing screening for RAS at the time of cardiac catheterization, the 4-year survival rates for patients with and without RAS were 57% and 89%, respectively ($p$ less than 0.001) (644). The 4-year survival rates for individuals with RAS of 50%, 75%, and greater than 95% were 70%, 68%, and 48%, respectively. Bilateral RAS was associated with a 47% 4-year survival compared with 59% for unilateral RAS ($p$ less than 0.001). In the multivariate analysis, the presence of RAS conferred a hazard ratio of 2.01 (95% CI 1.51 to 2.67, $p$ less than 0.001) regardless of the treatment of the underlying coronary artery disease (644). Finally, the severity of renal function impairment has been associated with reduced survival in patients with RAS (646). In patients with serum creatinine levels less than 1.4 mg per dL, 3-year survival was 92% plus or minus 4%. For serum creatinine levels between 1.5 and 1.9 mg per dL, 3-year survival was 74% plus or minus 8%, and for creatinine greater than or equal to 2.0 mg per dL, it was only 51% plus or minus 8%. The relationship between the increase in serum creatinine and mortality is complex and multifactorial. Not only do the severity of RAS and the severity of systemic atherosclerosis serve as contributors to mortality, but the degree of proteinuria, parenchymal renal disease, and other comorbidities (such as diabetes mellitus) play an important role (12,647).

## *3.2. Clinical Clues to the Diagnosis of RAS*

**RECOMMENDATIONS**

**Class I**

1. **The performance of diagnostic studies to identify clinically significant RAS is indicated in patients with the**

**onset of hypertension before the age of 30 years.** ***(Level of Evidence: B)***

2. **The performance of diagnostic studies to identify clinically significant RAS is indicated in patients with the onset of severe hypertension [as defined in The Seventh Report of the Joint National Committee on Prevention, Detection, Evaluation, and Treatment of High Blood Pressure: the JNC-7 report (294)] after the age of 55 years.** ***(Level of Evidence: B)***
3. **The performance of diagnostic studies to identify clinically significant RAS is indicated in patients with the following characteristics: (a) accelerated hypertension (sudden and persistent worsening of previously controlled hypertension); (b) resistant hypertension (defined as the failure to achieve goal blood pressure in patients who are adhering to full doses of an appropriate 3-drug regimen that includes a diuretic); or (c) malignant hypertension (hypertension with coexistent evidence of acute end-organ damage, i.e., acute renal failure, acutely decompensated congestive heart failure, new visual or neurological disturbance, and/or advanced [grade III to IV] retinopathy).** ***(Level of Evidence: C)***
4. **The performance of diagnostic studies to identify clinically significant RAS is indicated in patients with new azotemia or worsening renal function after the administration of an ACE inhibitor or an angiotensin receptor blocking agent (see text).** ***(Level of Evidence: B)***
5. **The performance of diagnostic studies to identify clinically significant RAS is indicated in patients with an unexplained atrophic kidney or a discrepancy in size between the 2 kidneys of greater than 1.5 cm.** ***(Level of Evidence: B)***
6. **The performance of diagnostic studies to identify clinically significant RAS is indicated in patients with sudden, unexplained pulmonary edema (especially in azotemic patients).** ***(Level of Evidence: B)***

**Class IIa**

**The performance of diagnostic studies to identify clinically significant RAS is reasonable in patients with unexplained renal failure, including individuals starting renal replacement therapy (dialysis or renal transplantation).** ***(Level of Evidence: B)***

**Class IIb**

1. **The performance of arteriography to identify significant RAS may be reasonable in patients with multivessel coronary artery disease and none of the clinical clues (Figure 17) or PAD at the time of arteriography.** ***(Level of Evidence: B)***
2. **The performance of diagnostic studies to identify clinically significant RAS may be reasonable in patients with unexplained congestive heart failure or refractory angina (see Section 3.5.2.4).** ***(Level of Evidence: C)***

Several clinical features raise the suspicion of RAS and provide relative indications for application of more specific diagnostic testing strategies. One such indication is the presence of an atrophic kidney (7 to 8 cm) or discrepancy in renal sizes (648). In such cases, the atrophy should be otherwise unexplained by a prior history of pyelonephritis, reflux nephropathy, trauma, and so on. When such a history is present, there is usually not an indication for additional renal diagnostic tests to define RAS. These clinical indications are outlined in Figure 17.

### *3.3. Pathophysiology and Disease Categories*

The pathophysiology that results from RAS is mediated by the degree of renal blood flow impairment. In the acute phase, unilateral RAS causes a renin-mediated (vasoconstriction) form of hypertension, although renin increases may be moderated in the chronic phase of renal hypertension. In contrast, the effects of bilateral renal artery stenoses or stenosis to a solitary kidney are predominantly due to an increase in extracellular fluid volume. Exceptions to this include longstanding unilateral RAS and contralateral renal dysfunction (e.g., due to hypertensive nephrosclerosis or hyperfiltration injury) wherein the physiology mimics that of a patient with a single functioning kidney or those with bilateral disease. Inasmuch as renal blood flow and filtration rate are maintained, in part, by angiotensin II-induced efferent arteriolar vasoconstriction, agents that cause efferent arteriolar dilation, such as ACE inhibitors or angiotensin II receptor blockers, can cause acute renal failure. They do so by decreasing transglomerular hydrostatic pressure and thus glomerular filtration rate. In addition, because the glomerular filtration rate falls but renal blood flow changes very little, the filtration fraction decreases. Under these circumstances, blood is shunted from the afferent arteriole to the efferent arteriole because there is not an adequate hydrostatic pressure to maintain filtration. Thus, use of ACE inhibitors or angiotensin receptor-blocking medications in patients with bilateral RAS, stenosis to a solitary kidney, or decompensated congestive heart failure in a sodium-depleted state can result in acute renal failure (649-652). This pathophysiology underlies both the caution required in the therapeutic use of angiotensin-pathway antagonists in patients with RAS and the diagnostic clue to RAS provided when severe hypotension or azotemia is provoked by use of these classes of medications. It should be noted that short-term changes in renal function are often multifactorial, and that clinicians have differing thresholds for defining significant new azotemia. Clinically significant azotemia has been defined as a greater than 50% rise in serum creatinine that persists or worsens after hypoperfusion states are corrected (e.g., volume depletion, nonsteroidal anti-inflammatory drug use, heart failure) (652a).

#### 3.3.1. Atherosclerosis

Approximately 90% of all renovascular stenotic lesions are due to atherosclerosis (653). Although isolated atherosclerot-

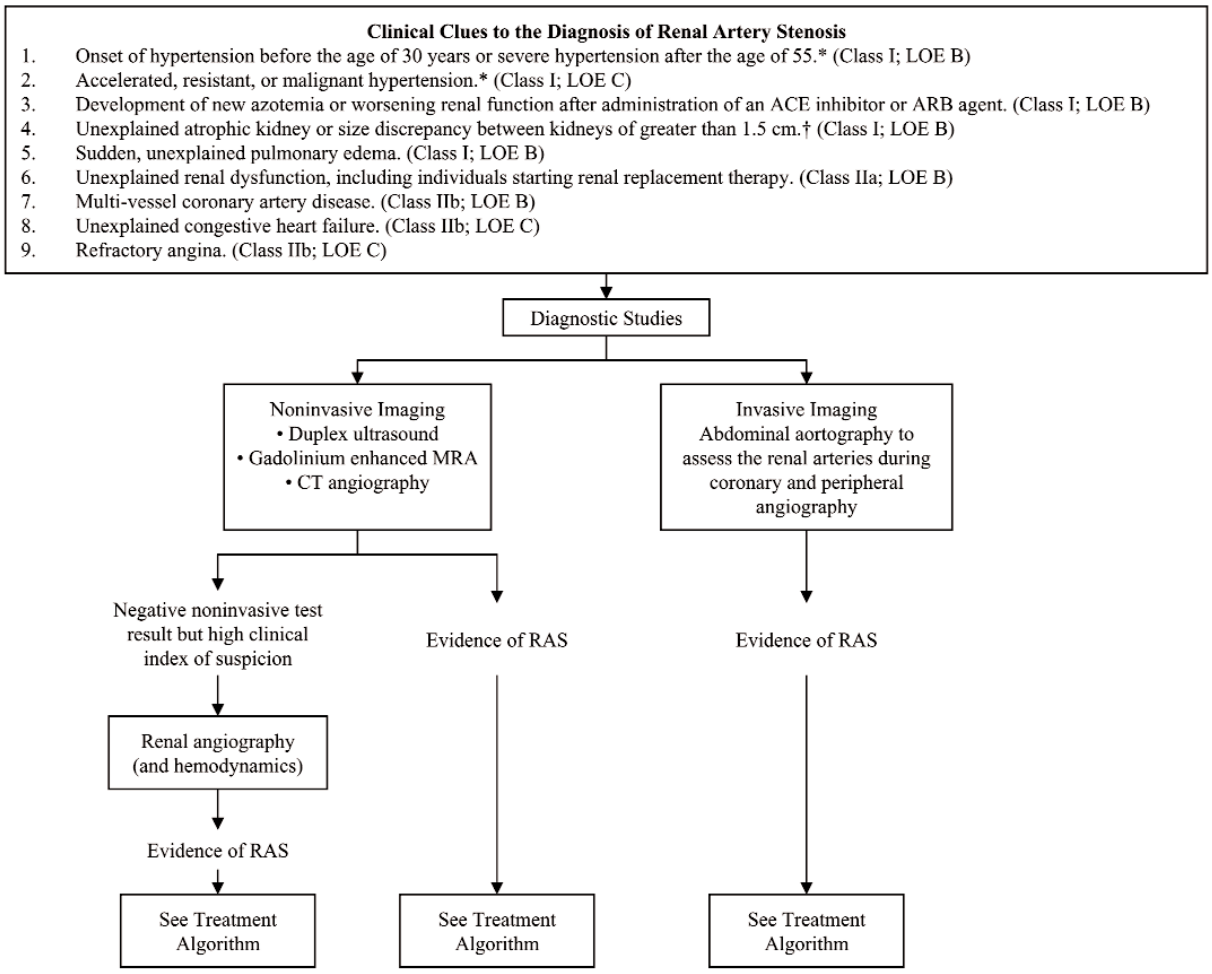


**Figure 17.** Clinical clues to the diagnosis of renal artery stenosis (RAS). *For definition of hypertension, please see Chobanian AV, Bakris GL, Black HR, et al. The Seventh Report of the Joint National Committee on Prevention, Detection, Evaluation, and Treatment of High Blood Pressure: the JNC-7 report. JAMA 2003;289:2560-72 (294). †For example, atrophic kidney due to chronic pyelonephritis is not an indication for RAS evaluation. ACE indicates angiotensin-converting enzyme; ARB, angiotensin receptor blocking agent; CT, computed tomography; LOE, level of evidence; MRA, magnetic resonance angiography.

ic RAS may be found, it is more commonly a manifestation of systemic atherosclerosis that involves the aorta, coronary, cerebral, and peripheral arteries. Atherosclerotic RAS most often affects the aorto-ostial segment, including the proximal 1 cm of the main renal artery, that is, an intrinsic renal plaque extending to and contiguous with the aorta.

### 3.3.2. Fibromuscular Dysplasia

Fibromuscular dysplasia (FMD) is a nonatherosclerotic, noninflammatory disease that most commonly affects the renal arteries and is the second most common cause of RAS (11,654-657). The most common clinical presentation is that of hypertension in a young woman, although FMD can occur in both genders at any age. Whereas atherosclerotic lesions usually involve the origin and proximal portion of the renal arteries, FMD characteristically involves the middle and distal two thirds of the main renal artery and may involve renal artery branches.

Medial fibroplasia is the histological finding in nearly 80% to 85% of all cases of FMD. This form of FMD tends to occur in 25- to 50-year-old women and often involves both renal arteries. It has a characteristic angiographic "string of beads" appearance (Table 28). The "bead" diameter is typically larger than the adjacent, less-affected artery. Bilateral disease occurs in 60% of patients, including 10% to 15% in whom the lesions are functionally important and warrant treatment. In 25% of patients, the disease extends into the segmental arteries. Intimal fibroplasia is, by comparison, relatively rare. Its stenosis appears as a thin, discrete web. Perimedial dysplasia often affects women a decade older than those with medial fibrodysplasia. Segmental perimedial dysplasia is uncommon (658-660).

Fibromuscular dysplasia also affects other arteries, including the carotid and vertebral arteries, and less commonly, the

**Table 28.** Classification of Fibromuscular Dysplasia

| Classification | Frequency | Pathology | Angiographic Appearance |
|---|---|---|---|
| Medial dysplasia | | | |
| Medial fibroplasia | 80% | Alternating areas of thinned media and thickened fibromuscular ridges containing collagen; internal elastic membrane may be lost in some areas | "String of beads" appearance in which diameter of "beading" is larger than diameter of artery |
| Perimedial fibroplasia | 10% to 15% | Extensive collagen deposition in outer half of media | "Beading" in which "beads" are smaller than diameter of artery |
| Medial hyperplasia | 1% to 2% | True smooth muscle cell hyperplasia without fibrosis | Concentric smooth stenosis (similar to intimal disease) |
| Intimal fibroplasia | Less than 10% | Circumferential or eccentric deposition of collagen in the intima; no lipid or inflammatory component; internal elastic lamina fragmented or duplicated | Concentric focal band; long, smooth narrowing |
| Adventitial (periarterial) fibroplasia | Less than 1% | Dense collagen replaces fibrous tissue of adventitia and may extend into surrounding tissue | So rare that classic angiographic findings are not known |

Reprinted with permission from Begelman SM, Olin JW. Fibromuscular dysplasia. Curr Opin Rheumatol 2000;12:41-7 (11).

iliac and mesenteric arteries. There appears to be an association between carotid and vertebral FMD and intracranial aneurysmal disease, with prevalence as high as 51% (661,662). However, the prevalence of cerebral aneurysms may be falsely elevated because of selection bias. When patients who presented with subarachnoid hemorrhage were excluded from the prevalence estimates, the prevalence of incidental, asymptomatic cerebral aneurysms in patients with internal carotid or vertebral artery FMD was 7.3% in one contemporary series (662).

Magnetic resonance angiography of the head should be performed in all patients with cervicocranial FMD. The prevalence of FMD in nonreferral populations is poorly elucidated, and thus, the relative efficacy of screening for FMD in nonrenal arterial beds, in the presence of renal FMD, is beyond the scope of this guideline (661,662).

### 3.3.3. Other Causes of Renal Artery Disease

Renovascular hypertension may also be caused by renal artery aneurysms. Renal artery aneurysms may require surgical or endovascular treatment to obviate risk of rupture or to diminish their contribution to a renin-mediated form of hypertension. Aneurysm rupture is of greatest concern with noncalcified aneurysms larger than 2 cm in diameter, particularly in premenopausal women because of the increased risk of aneurysm rupture during pregnancy (663,664).

The other causes of renovascular disease are myriad (663-673) and include Takayasu's arteritis (671-673), atheroemboli, thromboemboli, William's syndrome (669,671), neurofibromatosis (670,671), spontaneous renal artery dissection, arteriovenous malformations or fistulas, trauma (e.g., lithotripsy, direct injury, or surgery), and prior abdominal radiation therapy (665-668). Rarely, retroperitoneal fibrosis producing external compression has also been associated with RAS.

## *3.4. Diagnostic Methods*

**RECOMMENDATIONS**

**Class I**

1. **Duplex ultrasonography is recommended as a screening test to establish the diagnosis of RAS. *(Level of Evidence: B)***
2. **Computed tomographic angiography (in individuals with normal renal function) is recommended as a screening test to establish the diagnosis of RAS. *(Level of Evidence: B)***
3. **Magnetic resonance angiography is recommended as a screening test to establish the diagnosis of RAS. *(Level of Evidence: B)***
4. **When the clinical index of suspicion is high and the results of noninvasive tests are inconclusive, catheter angiography is recommended as a diagnostic test to establish the diagnosis of RAS. *(Level of Evidence: B)***

**Class III**

1. **Captopril renal scintigraphy is not recommended as a screening test to establish the diagnosis of RAS. *(Level of Evidence: C)***

2. **Selective renal vein renin measurements are not recommended as a useful screening test to establish the diagnosis of RAS.** ***(Level of Evidence: B)***
3. **Plasma renin activity is not recommended as a useful screening test to establish the diagnosis of RAS.** ***(Level of Evidence: B)***
4. **The captopril test (measurement of plasma renin activity after captopril administration) is not recommended as a useful screening test to establish the diagnosis of RAS.** ***(Level of Evidence: B)***

Renal artery stenosis is best diagnosed with an imaging modality. The ideal tool should evaluate both the main and accessory renal arteries, assess the hemodynamic significance of the demonstrated lesions, identify the site and severity of the stenosis, and identify associated perirenal pathology, including the presence of an AAA or renal or adrenal masses. Direct imaging modalities such as duplex ultrasound, CTA, and MRA are best suited to serve as effective diagnostic screening methods. The choice of imaging procedure will depend on the availability of the diagnostic tool, the experience and local accuracy of the chosen modality, and patient characteristics (e.g., body size, renal function, contrast allergy, and presence of prior stents or metallic objects that may serve as contraindications to MRA or CTA techniques).

### 3.4.1. Renal Scintigraphy

Captopril renography yields both scintigraphic images and computer-generated time-activity curves to provide information about renal size, perfusion, and excretory capacity. Typical methods to perform this examination include the oral administration of captopril 50 mg taken 60 minutes before performance of renal scintigraphic imaging with technetium-99m mercaptoacetyltriglycine or technetium-99m diethylenetriaminepentaacetic acid. The diagnostic criteria for RAS are (a) delayed time to maximal activity (TMax greater than or equal to 11 minutes after captopril administration), (b) significant asymmetry of peak activity of each kidney, (c) marked cortical retention of the radionuclide after captopril administration, and (d) marked reduction in calculated glomerular filtration rate of the ipsilateral kidney after ACE inhibition (674). The accuracy of captopril renography in identifying patients with renovascular disease has been variable, with reported sensitivities of approximately 85% (range 45% to 94%) and specificities of approximately 93% (range 81% to 100%) (674-685).

In patients with azotemia, bilateral RAS, or RAS of a solitary functioning kidney, the sensitivity and specificity of captopril renography is poor. Many investigators have excluded from captopril testing those patients with a serum creatinine value that exceeds 2.5 to 3.0 mg per dL. In patients with a serum creatinine greater than or equal to 1.5 mg per dL and less than or equal to 3.0 mg per dL, Fommei et al. reported a reduction in the positive predictive value from 88% to 57%, whereas there was a minimum reduction in sensitivity/specificity in patients with serum creatinine of 1.5 mg per dL (678).

When captopril renography was compared with catheter angiography in a clinical practice setting, the sensitivity was only 74%, and the specificity was only 59% (686). Thus, captopril renography may not be a very useful test for screening most patients for RAS but may retain some value in the assessment of renal artery stenoses of borderline angiographic severity for which the physiological functional significance is unclear.

### 3.4.2. Duplex Ultrasound

Duplex (Doppler with B-mode) ultrasound, compared with angiography, has a sensitivity of 84% to 98% and a specificity of 62% to 99% for detecting RAS (687-693). An end-diastolic velocity of more than 150 cm per second predicts severe (greater than 80%) RAS (694). Other criteria used include direct peak systolic velocity greater than 18 to 200 cm per second, renal to aortic ratio greater than 3.5, rise time greater than 0.07 seconds, acceleration index less than 300 cm per second, and difference in renal or segmental resistive index greater than 0.15. These criteria have correlated with a stenosis exceeding 60% in most published series. Renal artery duplex ultrasonography is an excellent test to monitor renal artery patency after endovascular treatment or surgical revascularization of RAS (695,696). Unlike MRA, in which most stents currently cause artifacts, ultrasound transmission through a stent is not a problem. Limitations of renal artery duplex ultrasonography include its absolute dependence on operator skill, the diminished ability to visualize accessory renal arteries, and the difficulty or inability to image obese patients or patients with intervening bowel gas (696).

Renal artery duplex ultrasonography may be used to measure the renal artery resistive index (RRI). An increased RRI suggests structural abnormalities in the small blood vessels of the kidney. Such small-vessel disease has been documented in the context of longstanding hypertension associated with nephrosclerosis or glomerulosclerosis (697). There have been conflicting reports regarding the usefulness of RRI to predict individual patient response to revascularization. A retrospective study has demonstrated that an elevated resistance index greater than 0.80 predicted a lack of improvement in blood pressure and renal function after revascularization (698). A limitation of that study was its retrospective design, lack of prespecified end points, and inclusion of a large majority of patients who received balloon angioplasty as their method of treatment. Renal angioplasty without stent placement is now generally recognized as a less optimal method of renal revascularization (699-701), and thus, the outcomes in response to renal revascularization therapy may have been underestimated in that report.

A prospective study of renal stent placement in 241 patients demonstrated that patients with an elevated RRI did have a favorable blood pressure response to intervention (702). Furthermore, serum creatinine improved 15% to 23% in patients with mild to moderate (RRI 0.7 to 0.8) and severe

(RRI greater than 0.80) nephrosclerosis, respectively. Notably, only 18% of those with severe nephrosclerosis had serum creatinines greater than 2.5 mg per dL. Resistive indices may prove useful in identifying severe parenchymal disease, which might limit the value of renal revascularization. The database regarding the predictors of a beneficial clinical outcome to renal revascularization remains incomplete and will require future prospective randomized, controlled trials.

### 3.4.3. Computed Tomographic Angiography

Computed tomographic angiography produces excellent 3D images of the aorta and renal arteries. Computed tomographic angiography has a sensitivity and specificity for detecting significant RAS of 59% to 96% and 82% to 99%, respectively, compared with catheter-based contrast angiography (703-709). Current multidetector-row scanners acquire up to 16 simultaneous interweaving helices; 32- and 64-row and flat-panel scanners are in development. With current CTA techniques, sensitivity for detecting renal artery stenoses reached 91% and 92% (readers 1 and 2), and the specificity was 99% for both readers (241). Computed tomographic angiography is capable of providing high-resolution noninvasive detection of RAS while supplying associated 3D angiographic images of the aorta, renal, and visceral arteries. Computed tomographic angiography requires the administration of 100 to 150 cc of iodinated contrast and therefore is not an ideal screening method for patients with renal insufficiency because of the risk of inducing contrast nephropathy. However, as computed tomography scanner technology advances, particularly with regard to the development of scanners with increasing numbers of conventional and newer flat-panel detectors, spatial resolution will improve, scanning time will decrease, and the administered contrast load may be reduced. One advantage of CTA over the MRA technique is that metal stents may be imaged with CTA and in-stent restenosis detected.

### 3.4.4. Magnetic Resonance Angiography

Contrast-enhanced MRA is performed with gadolinium, a less-nephrotoxic contrast agent, to obtain visualization of the renal arteries and abdominal vasculature (710-716). Comparisons with catheter-based contrast angiography have indicated a range of sensitivities from 90% to 100% and specificities of 76% to 94% for detection of RAS. Many earlier flow-related artifacts are avoided almost entirely with the use of gadolinium as a contrast agent. Magnetic resonance angiography may be less effective in the assessment of patients with more subtle beading and changes of FMD because of current resolution limits balanced against the size of the distal renal artery and its branches. Occasionally, beading artifacts may appear when none exist (on angiography). However, as improvements in acquisition speed, pulse sequences, scanner technologies, and novel contrast formulations continue to evolve, many of these technical limitations may be overcome (717).

#### *Summary of Noninvasive Renal Artery Diagnostic Imaging Strategies*

There are relative advantages and disadvantages to each of the aforementioned imaging modalities. Captopril renography has been validated in a large number of patients but is limited in value to a subset of all potential renovascular patients, and it is of limited value in patients with significant azotemia, bilateral RAS, or RAS to a single functioning kidney. Duplex renal sonography, because of the critical role of the sonographer, is accurate in experienced laboratories and is thus ideally performed in high-volume accredited laboratories. The diagnostic accuracy of these ultrasound-based examinations is further limited in patients with large body habitus or intestinal gas obscuring visualization of the entirety of the renal artery. Computed tomographic angiography currently provides higher spatial resolution than MRA and may be more readily available; however, the requirement to use iodinated contrast makes it an unattractive modality in patients with impaired renal function. Gadolinium-enhanced MRA provides excellent and less-nephrotoxic characterization of the renal arteries, surrounding vessels, renal mass, and perhaps renal function, but it remains the most costly renal artery examination. It is far less useful in patients who have had a metallic renal artery stent placed because of the inability to image inside of the stent to detect restenosis. Comparisons of contrast-enhanced 3D MRA and multidetector CTA with digital subtraction catheter angiography in a large number of arterial segments have demonstrated equally high sensitivities for detection of hemodynamically significant stenoses for MRA and computed tomography (greater than 90%), with excellent interobserver and intermodality agreement (kappa equals 0.88 to 0.90) (241).

### 3.4.5. Catheter Angiography

Renal catheter-based contrast arteriography, the longstanding "gold standard" for the diagnosis of RAS, has been largely replaced as a practical first-line modality by the previously described noninvasive imaging studies. The indications for catheter-based contrast renal angiography include (a) individuals in whom there are prespecified indications to suspect clinically important RAS ("clinical clues") in whom definitive diagnostic noninvasive images cannot be obtained and (b) individuals in whom these prespecified clinical indications and patient consent have been documented and in whom concomitant angiographic access has been obtained for peripheral angiography or coronary angiography.

Catheter-based contrast angiography is associated with a low rate of serious adverse outcomes in individuals with normal renal function. These include contrast-induced acute renal failure, contrast-related allergic reactions, atheromatous renal and distal (lower extremity) embolization, and access-related complications such as pseudoaneurysm, arteriovenous fistula, bleeding, and hematoma. However, the risk of contrast-induced acute renal failure is magnified in certain clinical groups, particularly those with diabetes and

chronic kidney disease. In general, the incidence of contrast-induced acute renal failure is less than 3% in patients with neither diabetes nor chronic kidney disease; 5% to 10% in those with diabetes; 10% to 20% in those with chronic kidney disease (and greater with more advanced stages), and 20% to 50% in those with both diabetes and chronic kidney disease (717a,717b).

Iodinated contrast-related acute renal failure can be mitigated with fluids (i.e., avoiding dehydration, using preprocedure intravenous fluids to stimulate urine output) and the use of alternative imaging agents such as carbon dioxide or gadolinium. One randomized trial in diabetic patients with elevated serum creatinine (1.5 to 3.5 mg per dL) levels demonstrated that iodixanol, an iso-osmolar nonionic contrast agent, was associated with significantly fewer nephrotoxic effects than iohexol, a low-osmolar nonionic contrast agent (276). Renal protection has also been demonstrated with the use of oral acetylcysteine (600 mg 2 times per day) in a randomized, controlled trial of patients with chronic renal impairment (serum creatinine greater than 1.2 mg per dL or creatinine clearance less than 60 mL per min) undergoing coronary angiography (278). Additionally, hemofiltration performed both before and after coronary intervention in patients with chronic renal failure has been reported to materially reduce the incidence of deterioration in renal function in this patient population (281).

Given the high prevalence of RAS in individuals with coronary artery disease (621,718,719) and peripheral vascular disease (619,624-630) that warrant catheter angiography, the use of screening flush aortography (not selective renal angiography) at the time of coronary and peripheral vascular angiography has been proposed. Such studies may be appropriate (by operators skilled in the performance and evaluation of RAS using flush aortography) when individuals who will be undergoing coronary or limb angiography have clinical indicators for significant renal arterial occlusive disease. The performance of renal angiography in these individuals, in whom arterial catheterization of the aorta has been performed, provides anatomic access to the renal arteries with relatively low incremental risk (720). To date, studies have not demonstrated a measurable incremental risk to the use of nonselective renal angiography in conjunction with coronary angiography or peripheral vascular arteriography in individuals in whom indications for these procedures exist. Controlled studies demonstrating the benefit of identifying these lesions need to be performed.

### 3.4.6. Renin

#### *3.4.6.1. Selective Renal Vein Renin Studies*

Renal vein renin measurements are now performed very infrequently because of their limited clinical utility and need for invasive catheterization. The utility of the examination depends on the ability to differentiate the unilateral elevation of renin concentration from the renal vein that drains the kidney with renal artery disease from the systemic plasma renin levels and/or renal vein renin levels collected from the contralateral (normal) kidney. The test is performed with direct catheterization and collection of blood samples from within each renal vein and from the inferior vena cava cephalad and caudal to the renal veins at baseline. The test is typically repeated after stimulation of renin release by administration of either oral captopril or furosemide. To maximize the accuracy of this plasma biochemical marker of renal hypoperfusion, all medications that can affect renal renin secretion must be stopped, including all antihypertensive drugs, diuretics, and nonsteroidal anti-inflammatory drugs, for at least 2 weeks. In addition, the patient should be kept on a dietary sodium intake of 100 to 200 mmol per day. If it is considered unsafe to stop all antihypertensive agents, a calcium-channel blocker or alpha-1 adrenergic blocker can be used (721).

One study by Hughes et al. showed that if there was lateralization of the renal vein renin ratio of more than 1.4:1 and a duration of hypertension less than 5 years, the cure rate of hypertension after revascularization was 95% (722). Nevertheless, renal vein renin measurements have been largely supplanted by the aforementioned noninvasive imaging modalities. Renal vein renin measurements may have more utility in establishing an indication for nephrectomy in patients with renal artery occlusion than in identifying patients with RAS who may derive benefit from revascularization (721); for pediatric patients with questionably severe RAS before revascularization; or for patients with very marked aortoiliac-renal atherosclerosis, in whom revascularization could carry unusually high risk.

#### *3.4.6.2. Plasma Renin Activity: Captopril Test*

This study is performed as follows: after a baseline plasma renin level is obtained, 50 mg of captopril is given orally, and a second plasma renin level is obtained 60 minutes later. The overall sensitivity of this test is 61%, with a specificity of 86% for the detection of renal artery disease. However, this test is less accurate in patients who are volume expanded or who have chronic renal failure, bilateral renal artery disease, or disease to a solitary functioning kidney. In addition, the same principles regarding medication withdrawal apply to this test as with renal vein renin measurement. In one large study involving 540 patients, the false-negative rate for elevation of the plasma renin activity was 43% and the false-positive rate was 34% (723). Elevated plasma renin activity may be present in approximately 15% of patients with essential hypertension. Plasma renin activity is not recommended as a useful screening test to establish the diagnosis of RAS.

## *3.5. Treatment of Renovascular Disease: Renal Artery Stenosis*

Treatment of renal arterial disease should serve to aid in the normalization of blood pressure and to preserve renal function, and possibly to reduce risk of cardiovascular events and mortality. Both medical (pharmacological) and revascularization strategies should be considered for patients with documented renal arterial disease. The relative efficacy and safety of medical and endovascular strategies remains an area of

active clinical investigation. A treatment algorithm based on the current evidence base is provided in Figure 18.

### 3.5.1. Medical Treatment

**RECOMMENDATIONS**

**Class I**

1. **Angiotensin-converting enzyme inhibitors are effective medications for treatment of hypertension associated with unilateral RAS.** ***(Level of Evidence: A)***
2. **Angiotensin receptor blockers are effective medications for treatment of hypertension associated with unilateral RAS.** ***(Level of Evidence: B)***
3. **Calcium-channel blockers are effective medications for treatment of hypertension associated with unilateral RAS.** ***(Level of Evidence: A)***
4. **Beta-blockers are effective medications for treatment of hypertension associated with RAS.** ***(Level of Evidence: A)***

Multiple studies have now shown that ACE inhibitors and calcium-channel blockers are effective in the treatment of hypertension in the presence of RAS (724-728). These results address primarily the treatment of hypertension, but diminution in the progression of renal disease has also been demonstrated. There is also evidence that alternative therapies, based largely on chlorothiazide, hydralazine, and beta-blockers, appear effective to achieve target blood pressures in individuals with RAS. The beneficial effects of medical therapy in these studies on the progression of atherosclerotic renal arterial disease contributed by smoking cessation, treatment of dyslipidemia, and the use of aspirin are difficult to differentiate from improvement in blood pressure control alone. In addition, although the angiotensin II receptor blockers also have an evidence base of efficacy for normalization of blood pressure in individuals with RAS, their effects need to be tested further in large randomized trials. There are currently few objective clinical clues that permit selection of specific patient cohorts that would best be treated by medical therapy versus renal arterial revascularization, which remains an area of active clinical investigation. Individuals with atherosclerotic disease and hypertension should be treated according to goals of the Seventh Report of the Joint National Committee on Prevention, Detection, Evaluation, and Treatment of High Blood Pressure (294).

### 3.5.2. Indications for Revascularization

#### *3.5.2.1. Asymptomatic Stenosis*

**RECOMMENDATIONS**

**Class IIb**

1. **Percutaneous revascularization may be considered for treatment of an asymptomatic bilateral or solitary**

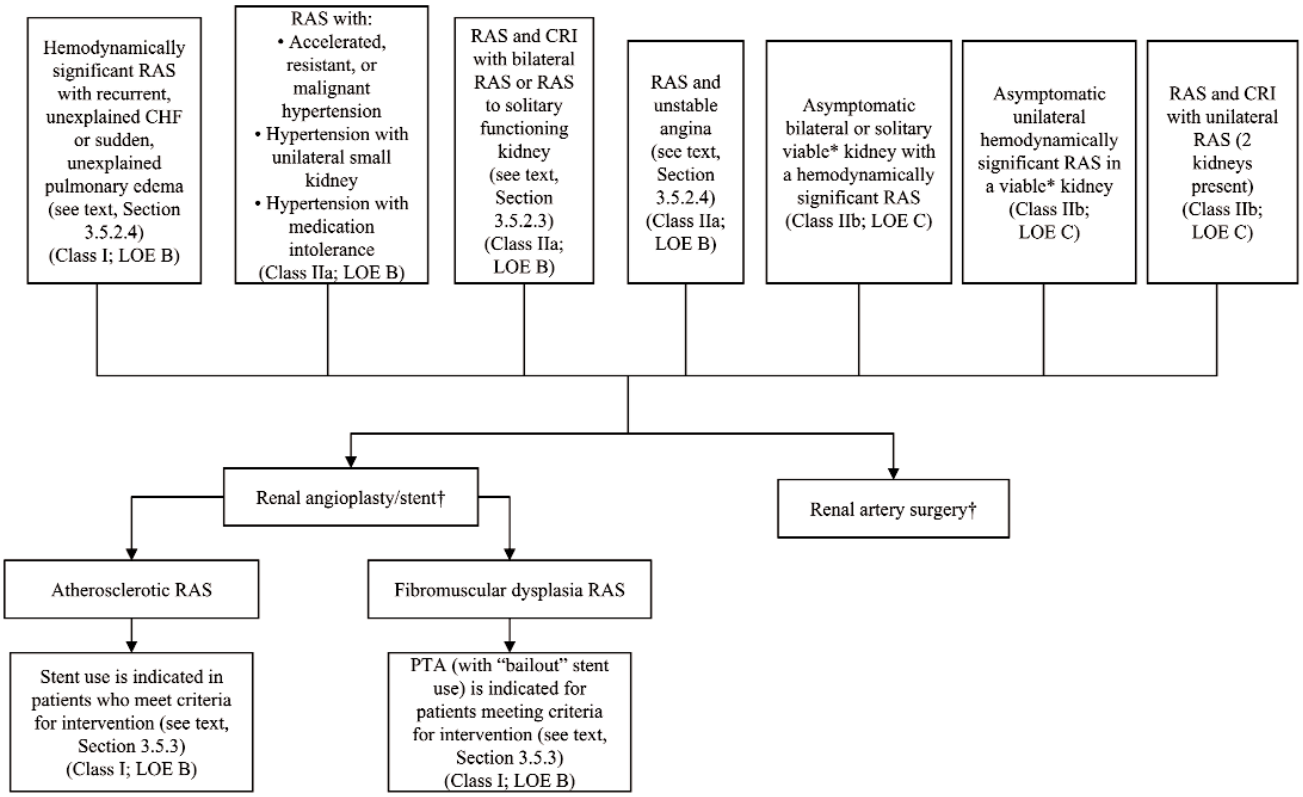


**Figure 18.** Indications for renal revascularization. *Viable means kidney linear length greater than 7 cm. †It is recognized that renal artery surgery has proven efficacy in alleviating RAS due to atherosclerosis and fibromuscular dysplasia. Currently, however, its role is often reserved for individuals in whom less invasive percutaneous RAS interventions are not feasible. CHF indicates congestive heart failure; CRI, chronic renal insufficiency; LOE, level of evidence; PTA, percutaneous transluminal angioplasty.

**Table 29.** Prevalence of Incidental RAS Found at Cardiac Catheterization

| First Author | Reference | No. of Patients | RAS (%) | RAS Greater Than 50% (%) | Bilateral (%) |
|---|---|---|---|---|---|
| Crowley | (643) | 14 152 | 11.4 | 6.3 | 21 |
| Harding | (621) | 1302 | 30 | 15 | 36 |
| Jean | (623) | 196 | 29 | 18 | NR |
| Vetrovec | (729) | 116 | NR | 23 | 29 |
| Conlon | (730) | 3987 | 34 | 9.1 | 17 |
| Rihal | (720) | 297 | 25 | 19 | 4 |
| Weber-Mzell | (622) | 177 | | 11 | 8 |

NR indicates not reported.

**viable kidney with a hemodynamically significant RAS.** ***(Level of Evidence: C)***

2. **The usefulness of percutaneous revascularization of an asymptomatic unilateral hemodynamically significant RAS in a viable kidney is not well established and is presently clinically unproven.** ***(Level of Evidence: C)***

Hemodynamically significant asymptomatic (incidental) renal artery stenosis is defined as RAS in the absence of end-organ dysfunction (e.g., idiopathic pulmonary edema, stroke, visual loss, hypertension, or refractory angina) but in the presence of (a) greater than or equal to 50% to 70% diameter stenosis by visual estimation with a peak translesional gradient (measured with a less than or equal to 5-Fr catheter or pressure wire) of greater than or equal to 20 mm Hg or a mean gradient greater than or equal to 10 mm Hg, (b) any stenosis greater than or equal to 70% diameter stenosis, or (c) greater than or equal to 70% diameter stenosis by intravascular ultrasound measurement (688).

Incidental (asymptomatic) RAS found at coronary or peripheral angiography (abdominal aortography) is more common than previously suspected (Tables 29 and 30) (621-623,625,630,643,719). Screening angiography has demonstrated renal artery stenoses (defined as greater than 50% diameter stenosis) in 18% of 196 consecutive patients undergoing coronary angiography for suspected coronary artery disease (623). In patients with established coronary artery disease, the incidence of incidental, unsuspected RAS climbed to 22%. One large study examined the incidence of RAS diagnosed by screening angiography during coronary angiography and found incidental renal artery narrowing in 30% of 1235 consecutive angiograms (621). Significant unilateral RAS (greater than 50% diameter stenosis) was documented in 15% of individuals, and bilateral RAS was observed in 33% of these subjects. Multivariate predictors of the presence of high-grade renal artery disease included age, associated coronary artery disease, congestive heart failure, female gender, and PAD. Hypertension was not an associated predictive variable.

Univariate predictors of RAS in 14 152 patients undergoing abdominal aortography at the time of cardiac catheterization are summarized in Table 31 (643). A trial of screening renal angiography at the time of cardiac catheterization in 177 consecutive patients found measurable RAS in 25% of the patients, with hemodynamically significant lesions observed in 11% of this population (622). Multivariate analysis demonstrated that the extent of coronary artery disease was the strongest predictor of concomitant RAS (Table 32) (622).

The use of renal angiography screening during peripheral vascular angiography has also demonstrated a much higher than expected incidence of asymptomatic or incidental RAS (Table 30) (625,630,719). In 394 consecutive patients undergoing angiographic evaluation of clinically suspected PAD (aortoiliac and lower extremity), without the usual clinical clues to suggest RAS, 33% to 39% had significant (greater than 50% diameter stenosis) RAS (Table 33) (625). Incidental (asymptomatic) RAS was discovered in 28% of 346 patients undergoing evaluation for AAA or peripheral arterial occlusive disease.

**Table 30.** Prevalence of Incidental RAS Found at Abdominal Aortography

| First Author | Reference | No. of Patients | RAS (%) | % RAS Greater Than 50% (%) | Bilateral (%) |
|---|---|---|---|---|---|
| Olin | (625) | 318 | NR | 38 | 13 |
| Valentine | (630) | 346 | NR | 28 | NR |
| Leertouwer | (719) | 386 | NR | 33 | 26 |

NR indicates not reported; RAS, renal arterial stenosis.

**Table 31.** Univariate Predictors of RAS in Individuals Undergoing Cardiac Catheterization

| Variable | OR (95% CI) | *p* |
|---|---|---|
| Coronary artery disease | 4.8 (3.9 to 5.9) | 0.000001 |
| Elevated creatinine | 4.5 (2.8 to 7.2) | 0.000001 |
| Peripheral arterial disease | 2.6 (2.2 to 3.0) | 0.000001 |
| Cerebrovascular disease | 2.3 (2.0 to 2.7) | 0.000001 |
| Hypertension | 2.3 (2.0 to 2.6) | 0.000001 |
| Ejection fraction less than 30% | 1.5 (1.2 to 1.8) | 0.001 |
| Diabetes mellitus | 1.5 (1.3 to 1.7) | 0.000001 |
| Female sex | 1.4 (1.2 to 1.6) | 0.000001 |
| Family history of CAD | 1.2 (1.0 to 1.4) | 0.009 |

CAD indicates coronary artery disease; CI, confidence interval; OR, odds ratio; RAS, renal arterial disease.
Reprinted with permission from Crowley JJ, Santos RM, Peter RH, et al. Progression of renal artery stenosis in patients undergoing cardiac catheterization. Am Heart J. 1998;136:913-8 (643).

Whereas the presence of coronary atherosclerosis predicts the presence of significant atherosclerotic renal artery disease, there is a converse ability of atherosclerotic renal arterial disease to predict the severity of coronary artery disease. Asymptomatic (incidental) RAS found at peripheral angiography is strongly associated with the presence of coronary artery disease (630). The presence of asymptomatic (incidental) RAS is a strong predictor of subsequent mortality (719). Conlon and coworkers performed screening abdominal aortography on 3987 patients undergoing cardiac catheterization (730). Significant (at least 50% diameter stenosis) RAS was found in 362 patients (9.1%), and severe (at least 75% diameter stenosis) RAS was found in 191 (4.8%). Approximately one fifth (n equals 33) of patients with severe RAS had bilateral involvement. In that study, the 4-year survival rate for patients with asymptomatic, severe (at least 75% diameter stenosis) RAS incidentally discovered at cardiac catheterization was diminished to 57% compared with the 89% survival rate in patients without severe RAS (730). The presence of severe RAS was independently associated with mortality. In a multivariate model, the negative impact of incidental RAS on survival persisted even in those individuals who had undergone revascularization for coronary artery disease. As the severity of RAS increased in 3 disease severity groups (from 50% to 75%, from 75% to 95%, and greater than 95%), the 4-year patient survival rate decreased from 70% to 68% and 48%, respectively (Table 34) (730). Patients with bilateral severe (at least 75% diameter stenosis) RAS had the lowest 4-year survival rate of 47% compared with 59% for those with unilateral disease.

The tendency for RAS to progress or worsen appears unaffected by medical therapy to control blood pressure. Renal artery occlusion generally causes irreversible loss of renal excretory function, although this loss may not be evident in the elevation of serum creatinine (653). Over a 7-year period, 24 312 patients underwent cardiac catheterization, of whom 14 152 (58%) had abdominal aortograms to screen them for asymptomatic RAS (643). The likelihood of new lesions appearing or of known lesions to progress was assessed in a cohort of 1189 patients who underwent 2 abdominal aortograms separated by at least 6 months. The average time separating the 2 angiograms was 2.6 plus or

**Table 32.** Multivariate Logistic Regression of Univariate Predictors of Renal Arterial Stenosis in Patients Undergoing Cardiac Catheterization for Suspected Coronary Artery Disease (CAD)

| | Regression Coefficient | Odds Ratio | 95% CI | *p* |
|---|---|---|---|---|
| Extent of CAD | 0.801 | 2.227 | 1.204 to 4.119 | 0.011 |
| Glomerular filtration rate | –0.04 | 0.961 | 0.925 to 0.998 | 0.038 |
| Systolic blood pressure | 0.025 | 1.026 | 0.996 to 1.057 | 0.078 |
| Age | –0.01 | 0.99 | 0.917 to 1.069 | 0.802 |
| Diabetes mellitus | 0.091 | 1.095 | 0.570 to 2.071 | 0.781 |

CI indicates confidence interval.
Reprinted with permission from Weber-Mzell D, Kotanko P, Schumacher M, et al. Coronary anatomy predicts presence or absence of renal artery stenosis: a prospective study in patients undergoing cardiac catheterization for suspected coronary artery disease. Eur Heart J. 2002;23:1684-91 (622).

**Table 33.** Prevalence of RAS in Individuals With Systemic Atherosclerotic Syndromes*

| | AAA (n=108) | AOD (n=21) | Infrainguinal PAD (n=189) | RAS (n=76) |
|---|---|---|---|---|
| All patients with greater than 50% stenosis | 41 (38%) | 7 (33%) | 74 (39%) | 53 (70%)† |

*Significant renal arterial stenosis (RAS) was defined as greater than 50% stenosis.
†$p<0.01$ versus other 3 groups.
AAA indicates abdominal aortic aneurysm; AOD, aortic occlusive disease; n, total sample size; and PAD, peripheral arterial disease.
Adapted with permission from Olin JW, Melia M, Young JR, et al. Prevalence of atherosclerotic renal artery stenosis in patients with atherosclerosis elsewhere. Am J Med. 1990;88(1N):46N-51N (625).

minus 1.6 years. A new RAS or RAS progression was seen in 11.1% of the patients (Table 35) (643). Progression from normal to greater than 75% stenosis in 1 or more arteries was associated with a decline in renal function and with a significantly higher serum creatinine (141 plus or minus 114 micromoles per liter) than in those patients without lesion progression (97 plus or minus 44 micromoles per liter, *p* equals 0.01). Lesion progression is more likely to occur in more severe stenoses (637,642). Notably, these studies were limited to individuals in whom coronary angiography was performed twice, presumably because of progressive clinical disease, and thus may not be representative of the larger population of individuals with RAS.

There are no well-controlled prospective, randomized investigations to measure the relative risk and benefit of endovascular interventions (or associated medical therapies) in individuals with asymptomatic renal artery disease, and thus the role of such interventions remains controversial. Recommendations regarding the role of percutaneous revascularization of asymptomatic renal disease are made largely on the basis of expert opinion and are not based on evidence that treatment of asymptomatic RAS improves any renal or systemic outcome, including renal preservation, blood pressure, or cardiovascular morbidity or mortality. Therefore, these recommendations are still considered controversial and must be individualized for the patient by each treating physician. The recommendations will likely be modified once controlled prospective data become available.

**Table 34.** Four-Year Survival for Individuals With Incidental (Asymptomatic) RAS as Documented at Cardiac Catheterization

| Severity of Incidental RAS | Four-Year Survival (%) |
|---|---|
| No RAS | 90 |
| 50% to 75% | 70 |
| 75% to 95% | 68 |
| Greater than 95% | 48 |

RAS indicates renal arterial stenosis.
Reprinted with permission from Conlon PJ, Little MA, Pieper K, et al. Severity of renal vascular disease predicts mortality in patients undergoing coronary angiography. Kidney Int. 2001;60:1490-7 (730).

### *3.5.2.2. Hypertension*

**RECOMMENDATIONS**

**Class IIa**

**Percutaneous revascularization is reasonable for patients with hemodynamically significant RAS and accelerated hypertension, resistant hypertension, malignant hypertension, hypertension with an unexplained unilateral small kidney, and hypertension with intolerance to medication.** ***(Level of Evidence: B)***

Control of hypertension is an important component of all atherosclerosis risk reduction. Most hypertension is not due to RAS (essential hypertension) and routine evaluation for RAS is not indicated. However, there are clinical clues that can be useful in identifying the small subset of individuals in whom directed evaluation for renal artery disease may be useful (see Section 3.2 and Figure 17). It should be noted that "resistant hypertension" is defined as the failure to achieve goal blood pressure in patients who are adhering to full doses of an appropriate 3-drug regimen that includes a diuretic (from p. 2570 of Chobanian et al., 294).

Renovascular hypertension remains the most common form of correctable hypertension. Percutaneous techniques have largely replaced surgical revascularization for atherosclerotic renovascular hypertension (731). The DRASTIC trial (Dutch Renal Artery Stenosis Intervention Cooperative) was an attempt to determine the efficacy of medical therapy compared with percutaneous transluminal renal angioplasty for blood pressure control in renovascular hypertension (732). There was an advantage for the percutaneous transluminal renal angioplasty group at 3 months. The intention-to-treat analysis at 1 year was limited in this study by the high proportion (greater than 40%) of patients who were assigned to the "medical treatment" cohort who crossed over to percutaneous transluminal renal angioplasty, thus potentially underestimating the benefit of percutaneous transluminal renal angioplasty. In addition, the percutaneous technique applied in this trial did not consistently utilize stents. Another criticism of the DRASTIC trial is that there was no proof of hemodynamic significance of stenoses of 50% to 70%. Therefore, some patients may have been treated with renal revascularization for nonhemodynamically significant stenoses. This would decrease the overall benefit for the treatment group. Since publication of this trial, stent place-

**Table 35.** Multivariate Analysis of Risk Factors Associated With Progression of Renal Arterial Stenosis

| Variable | OR (95% CI) | *p* |
|---|---|---|
| Female sex | 1.9 (1.5 to 2.2) | 0.002 |
| Increased age | 1.6 (1.4 to 1.8) | 0.0001 |
| Coronary artery disease | 1.3 (1.2 to 1.4) | 0.004 |
| Time between angiograms, yr | 1.3 (1.2 to 1.4) | 0.0001 |

CI indicates confidence interal; and OR, odds ratio.
Reprinted with permission from Crowley JJ, Santos RM, Peter RH, et al. Progression of renal artery stenosis in patients undergoing cardiac catheterization. Am Heart J. 1998;136:913-8 (643).

ment has emerged as a superior technique to balloon angioplasty alone for the treatment of atherosclerotic ostial RAS. In a meta-analysis comparing the clinical benefits of balloon angioplasty and stent therapy, stent therapy demonstrated a better blood pressure response and a lower restenosis rate (699).

The single randomized, controlled trial that compared renal stent placement with balloon treatment alone demonstrated procedural superiority for primary stent placement (700). The burden of reintervention in the percutaneous transluminal renal angioplasty group (48%) compared with that of the stent group (14%) also supported the cost efficacy of stent placement during the primary procedure. The reduced restenosis with stenting compared with angioplasty alone seen in this study was not associated with differences in either hypertension or renal function benefit. A number of studies have confirmed the high technical success rates (95% or higher) for primary renal stent placement (733-739).

As noted above, the indications for renal artery revascularization presume the presence of clinical indications with a hemodynamically significant stenosis defined as (a) 50% to 70% diameter stenosis by visual estimation with a peak translesional gradient (measured with a 5F or smaller catheter or pressure wire) of at least 20 mm Hg or a mean gradient of at least 10 mm Hg; (b) any stenosis of at least 70% diameter; or (c) greater than or equal to 70% diameter stenosis by intravascular ultrasound measurement (718).

It has been assumed that the outcome variability of the current investigational database is attributable to both the heterogeneity of patient selection criteria for inclusion in these clinical trials and the lack of standard reporting criteria. One trial demonstrated that patients with the highest baseline systolic blood pressures had the greatest decrease in systolic pressure, but the variables of age, sex, race, severity of stenosis, number of vessels treated, baseline diastolic pressure, or baseline serum creatinine did not correlate with blood pressure improvement after renal stent placement (13). Another multivariate logistic regression analysis demonstrated that 2 variables, bilateral RAS (OR equals 4.6, *p* equals 0.009) and mean arterial pressure greater than 110 mm Hg (OR equals 2.9, *p* equals 0.003), predicted a beneficial blood pressure response after renal artery stent placement (736). No difference has been demonstrated in the blood pressure response after stent placement in older (75 years and older) versus younger (less than 75 years) patients or in women versus men (740,741).

The current evidence base suggests that patients with severe atherosclerotic RAS and accelerated, resistant, and malignant hypertension may expect to receive some clinical benefit, including improved blood pressure control, the need for fewer medications, or both. However, "cure" of hypertension is rare, improvement in blood pressure control is common, and a moderate fraction of individuals do not achieve measurable benefit (Table 36).

### *3.5.2.3. Preservation of Renal Function*

**RECOMMENDATIONS**

**Class IIa**

**Percutaneous revascularization is reasonable for patients with RAS and progressive chronic kidney disease with bilateral RAS or a RAS to a solitary functioning kidney. *(Level of Evidence: B)***

**Class IIb**

**Percutaneous revascularization may be considered for patients with RAS and chronic renal insufficiency with unilateral RAS. *(Level of Evidence: C)***

Atherosclerotic RAS is an important cause of or contributor to renal failure (632,740,742,743). It is unclear how many patients enter dialysis secondary to RAS. In one study, patients with renovascular disease as the cause of their renal failure had survival rates of 56% at 2 years (640). As individuals with progressive worsening renal function are evaluated for reversible etiologies (including RAS), it should be noted that the National Kidney Foundation defines chronic kidney disease as a decrease in estimated glomerular filtration rate to less than 60 mL/min per 1.73 $m^2$ (modified Modification of Diet in Renal Disease formula) that persists for at least 3 months. Moreover, it may be inappropriate for many patients with new end-stage renal disease to be considered as candidates for evaluation for RAS when significant intrinsic kidney disease is a major contributor to renal failure.

**Table 36.** Clinical Benefit (Net Cure and/or Improvement in Blood Pressure Response) to Renal Artery Stenting

| First Author | Reference | No. of Patients | Arteries | Cure (%) | Improvement (%) | Benefit (%) |
|---|---|---|---|---|---|---|
| Dorros | (737) | 76 | 92 | 7 | 52 | 59 |
| Blum | (733) | 68 | 74 | 16 | 62 | 78 |
| White | (738) | 100 | 133 | NR | 76 | 76 |
| Tuttle | (734) | 129 | 148 | 2 | 55 | 57 |
| Henry | (735) | 210 | 244 | 19 | 61 | 78 |
| Rocha-Singh | (736) | 150 | 180 | 6 | 50 | 56 |
| Lederman | (739) | 261 | NR | Less than 1 | 70 | 70 |

NR indicates not reported.

Revascularization is effective in stabilizing or improving renal function in patients with symptomatic atherosclerotic RAS (701,744-748). Several trials have documented that renal artery stent placement improves or stabilizes renal function in patients with atherosclerotic RAS (749-752). Significant improvement in renal function up to 1 year after unilateral renal artery stent placement was demonstrated by Leertouwer and coworkers (701). They demonstrated that the glomerular filtration rate in the revascularized kidney improved significantly but that overall glomerular filtration rate from both kidneys did not change (721). Prospective randomized trials of stenting for unilateral RAS in an effort to preserve renal function are needed.

Harden and colleagues (750) reported a series of 32 patients (33 kidneys) with unexplained renal insufficiency and hemodynamically significant RAS who underwent stent placement. The majority of patients had bilateral or unilateral solitary RAS, although unilateral disease was present in 7 patients. Improvement and stabilization of renal function were demonstrated by plotting the slope of serial reciprocal serum creatinine values. This study was limited by a relatively short median follow-up of only 8 months. The authors concluded that stent placement slowed the progression of RAS (750). Ultimately, large-scale prospective, controlled trials better defining the role, thresholds, and patient subsets that warrant revascularization in the setting of chronic kidney disease need to be performed.

Improvement of renal function was demonstrated in 33 patients undergoing successful renal artery stent placement for bilateral or unilateral solitary RAS (greater than or equal to 70%) with a baseline serum creatinine between 1.5 and 4.0 mg per dL (751). When reciprocal creatinine plots were used, all patients at baseline had deteriorating renal function manifested by the negative calculated renal function slope. Follow-up data at greater than or equal to 8 months were available in 25 patients, all of whom had either a positive or less-negative reciprocal slope of the creatinine, which indicated improvement and stabilization of renal function. This small study also demonstrated preserved renal mass by ultrasound measurements.

Using a serum creatinine value greater than or equal to 1.5 mg per dL and a negative slope of the reciprocal of the serum creatinine in the preceding 12 months, Rocha-Singh et al. documented reversal of declining renal function with stent placement; this benefit was sustained over 30 months (752). The improvement in renal function was associated with lower blood pressure and fewer medication requirements. These authors concluded that renal stent revascularization should be considered a valid therapeutic option for the long-term treatment of ischemic nephropathy.

Several factors may argue against renal revascularization or predict poorer outcomes. These include the presence of proteinuria greater than 1 g every 24 hours, renal atrophy, severe renal parenchymal disease, and severe diffuse intrarenal arteriolar disease. In addition, several studies have shown that renal function can deteriorate after renal artery angioplasty, especially in patients with stable renal function

prior to the intervention (752a,752b). Thus, the risks and benefits of renal revascularization must be carefully evaluated in each individual.

The adverse consequences of renal atheroembolization at the time of surgical revascularization have been documented (753). Similar potentially severe atheroembolization may be provoked by renal percutaneous revascularization methods (754). The contribution of procedure-related renal artery atheroembolization to decrements in renal function after revascularization can be difficult to quantitate and distinguish from the nephrotoxic effects of iodinated contrast, particularly in patients with initially elevated serum creatinine and limited renal reserve. These potential limitations emphasize the need for preprocedural volume expansion and strict use of contrast-sparing techniques (e.g., highly diluted contrast), the use of alternative agents (e.g., carbon dioxide or gadolinium), preprocedure oral acetylcysteine administration, and high levels of operator experience when revascularization is performed in individuals with renal insufficiency. In a preliminary study, Henry and coworkers used embolic protection devices during percutaneous renal revascularization and demonstrated atheroembolic debris in all 32 arteries treated (755). The value of embolic protection devices is being tested in clinical trials to determine whether these devices can decrease (or increase) the frequency of clinically important atheroemboli to the kidneys. Ultimately, large-scale prospective, controlled trials better defining the role, thresholds, and patient subsets that warrant revascularization in the setting of chronic kidney disease need to be performed.

### *3.5.2.4. Impact of RAS on Congestive Heart Failure and Unstable Angina*

**RECOMMENDATIONS**

**Class I**

**Percutaneous revascularization is indicated for patients with hemodynamically significant RAS and recurrent, unexplained congestive heart failure or sudden, unexplained pulmonary edema (see text). *(Level of Evidence: B)***

**Class IIa**

**Percutaneous revascularization is reasonable for patients with hemodynamically significant RAS and unstable angina (see text). *(Level of Evidence: B)***

Alterations in circulatory homeostasis can be prominent in individuals with significant RAS and may provoke exacerbations of coronary ischemia and/or congestive heart failure due to peripheral arterial vasoconstriction, direct effects of angiotensin II on the myocardium, and/or volume overload. Renovascular disease may also complicate the long-term management of cardiac patients (e.g., those with hypertension or left ventricular systolic dysfunction) by preventing administration of angiotensin antagonist therapies.

Individuals with RAS may experience sudden-onset or "flash" pulmonary edema (756-761). Patients with hemodynamically severe bilateral or solitary RAS may manifest a volume-overload state because they lack normal renal function to respond to pressure natriuresis (762,763). Patients with unilateral renal stenosis may also experience pulmonary edema due to increased left ventricular afterload secondary to angiotensin-mediated vasoconstriction. Unilateral RAS may contribute to the development of unstable coronary syndromes by causing sudden increases in myocardial oxygen demand in patients with coronary disease secondary to peripheral vasoconstriction; this mechanism is distinct from the usual assumption underlying other mechanisms of acute coronary syndromes (e.g., plaque rupture or progressive atherosclerosis) (764,765).

This pathophysiology underpins the potential therapeutic benefit of renal artery stent placement in the treatment of some manifestations of congestive heart failure or unstable coronary syndromes (766,767). These patients were characterized by having at least 1 renal artery with a hemodynamically significant stenosis and established coronary artery disease. Successful renal stent placement resulted in a significant decrease in blood pressure and control of anginal symptoms in 88% of all patients (42 of 48). Some patients underwent both coronary and renal intervention, whereas others had only renal artery stent placement because their coronary atherosclerotic lesions were unsuitable for revascularization. Outcomes were assessed acutely and at 8 months with the Canadian Cardiovascular Society angina classification and the New York Heart Association functional classification. There was no incremental therapeutic advantage gained for the group that underwent coronary intervention with renal stent placement compared with the group that underwent renal stent placement alone.

These potential benefits of renal revascularization for individuals with severe angina or with exacerbations of heart failure have been observed in small prospective case series but have not been evaluated in prospective, randomized clinical trials. In addition, the individuals enrolled in these interventional case series were carefully selected and are not representative of the majority of patients with "accelerated angina" or with "recurrent congestive heart failure." Angina is known to accelerate via many mechanisms that are unrelated to renal hemodynamics (e.g., simple progressive coronary atherosclerosis and instability of coronary plaque), and these mechanisms are predominant. Thus, clinicians are cautioned to carefully explore these other mechanisms before presuming that renal artery disease is the major mechanism underlying the exacerbation of coronary symptoms. Similarly, heart failure is frequently caused by nonatherosclerotic mechanisms, and exacerbations of heart failure symptoms are multifactorial (e.g., due to progressive remodeling, progressive coronary disease, dietary changes, or medical noncompliance). The recommendations in the present guideline are intended to apply to individuals in whom these nonrenal factors have been explored and in whom there are clinical

**Table 37.** Renal Artery Intervention: The Posttreatment Efficacy of Primary Balloon Versus Stent Interventions

| | Baseline | Balloon | Stent |
|---|---|---|---|
| Stenosis (%) | 82 plus or minus 12 | 29 plus or minus 14 | 3 plus or minus 6* |
| Mean gradient, mm Hg | 50 plus or minus 22 | 8 plus or minus 6 | 1 plus or minus 3* |
| Peak gradient, mm Hg | 94 plus or minus 33 | 23 plus or minus 19 | 1 plus or minus 3* |

*$p$ less than 0.05.
Reprinted with permission from Dorros G, Jaff M, Mathiak L, et al. Four-year follow-up of Palmaz-Schatz stent revascularization as treatment for atherosclerotic renal artery stenosis. Circulation. 1998;98:642-7 (779).

indications to suggest the presence of RAS (e.g., systemic atherosclerosis).

In summary, the potential physiological benefits of renal stent placement include reperfusion of the ischemic kidney(s), resulting in a reduction in the stimulus to renin production, which decreases angiotensin and aldosterone production, thereby decreasing peripheral arterial vasoconstriction and the tendency to develop an expanded extracellular fluid volume. Improvement in renal perfusion enhances glomerular filtration and therefore promotes natriuresis. Finally, in patients with a solitary kidney or bilateral RAS, the ability of the patient to tolerate long-term administration of angiotensin antagonist medications may be facilitated by relief of a hemodynamic renal artery obstruction.

### 3.5.3. Catheter-Based Interventions

**RECOMMENDATIONS**

**Class I**

1. **Renal stent placement is indicated for ostial atherosclerotic RAS lesions that meet the clinical criteria for intervention.** ***(Level of Evidence: B)***
2. **Balloon angioplasty with bailout stent placement if necessary is recommended for FMD lesions.** ***(Level of Evidence: B)***

Percutaneous transluminal renal balloon angioplasty is the treatment of choice for symptomatic RAS caused by FMD (744,768-770). However, in atherosclerotic RAS, balloon angioplasty alone is associated with a lower procedural success rate and a higher restenosis rate (745,771-777). Aorto-ostial stenoses represent the most common atherosclerotic lesions and are prone to vascular recoil due to confluent plaque that extends from the wall of the aorta into the ostium of the renal artery. These atherosclerotic aorto-ostial lesions are generally considered unsuitable for treatment by balloon angioplasty alone (769,770,778).

Stent placement has consistently proven superior to balloon angioplasty in the treatment of renal artery atherosclerotic lesions. Balloon angioplasty was compared with stent placement in atherosclerotic RAS by Dorros and coworkers (779). Quantitative vascular angiography and translesional pressure gradients were measured in 18 patients who served as their own controls. Stents were significantly more effective than balloon angioplasty in these atherosclerotic renal artery lesions (Table 37) (779).

The superiority of renal stent placement over balloon angioplasty was confirmed in a randomized, controlled trial in hypertensive patients by van de Ven and coworkers (700). A total of 42 patients and 51 arteries were randomized to balloon angioplasty (with bailout stenting), and 42 patients and 52 arteries were randomized to receive primary stent therapy. Procedure success and long-term patency markedly favored the stent group (Table 38) (700). Over the course of the study, 12 (29%) patients in the balloon group crossed over to the stent group. This large percentage of crossover patients confounded the analysis of the clinical end point at 1 year.

The authors calculated that a renal bailout (provisional) stent strategy would avoid a stent during the initial procedure 40% of the time. However, 45% of the patients would ultimately require a second procedure with a stent and also would incur additional complications that would make the strategy of primary stent placement more efficient. For the balloon group to achieve a 90% patency rate at 6 months, 62% of all patients would ultimately require a stent, and 57% of all patients would need a second or third procedure. To obtain a 90% 6-month patency rate in the primary stent group, only 12% would need a second procedure. This randomized, controlled trial clearly demonstrated the superiority of renal stents over balloons in hypertensive patients with atherosclerotic RAS for procedure success, late patency, and cost-effectiveness (700).

A meta-analysis of 10 renal stent studies performed between 1991 and 1997 demonstrated procedural success

**Table 38.** Balloon Versus Stent: Randomized, Controlled Trial

| | Balloon (n=51) | Stent (n=52) | *p* Value |
|---|---|---|---|
| Procedure success | 63% | 90% | Less than 0.05 |
| Restenosis | 48% | 14% | Less than 0.05 |

van de Ven PJ, Kaatee R, Beutler JJ, et al. Arterial stenting and balloon angioplasty in ostial atherosclerotic renovascular disease: a randomised trial. Lancet. 1999;353:282-6. (700). Reprinted with permission from Elsevier.

rates greater than or equal to 96% with a procedure-related mortality rate of less than 1% (780). The average restenosis rate, evaluated between 6 and 12 months after the procedure, was 16%. A second meta-analysis, comparing renal stent placement and balloon angioplasty, for atherosclerotic RAS was performed by Leertouwer and colleagues (700). They confirmed a significantly higher procedural success rate for stents (98%) than for balloon angioplasty (77%; $p$ less than 0.001) and a lower restenosis rate for stents (17%) than for balloon angioplasty (26%; $p$ less than 0.001). A survey of the literature suggests that restenosis rates for renal stenting are often lower (Table 39).

Renal resistive index has been suggested as a marker for selecting patients likely to respond to intervention. However, there are conflicting data regarding the ability of the RRI to predict treatment response. A retrospective study in which most patients were treated by balloon angioplasty alone by Radermacher and coworkers (698) suggested that an elevated resistance index greater than 0.80 was associated with a low probability of improved blood pressure control or renal function preservation after revascularization. This study has been criticized for its retrospective nature without use of prespecified end points and for its reliance on the use of balloon angioplasty as the primary method of treatment. These data have been challenged recently by a prospective uncontrolled study of renal stent placement in 241 patients by Zeller and associates (702). These investigators clearly demonstrated that patients with an elevated RRI were also able to achieve a favorable blood pressure response and renal functional improvement after renal arterial intervention.

For renal artery atherosclerotic lesions, the larger the post-stent minimal lumen diameter, as measured by quantitative vascular angiography, the better the late stent patency (738). Similar to coronary stents, larger diameter renal arteries have lower restenosis rates than smaller diameter vessels (698, 736). Two series have addressed the long-term durability and patency of renal stents (733,735). In those series, the 5-year primary patency rates of renal stents were 79% and 84.5%, and the secondary patency rates were 92.4% and 98%. Almost all occurrences of stent restenosis occurred during the first year after stent implantation, with restenosis later than 2 years an unusual occurrence.

### 3.5.4. Surgery for RAS

**RECOMMENDATIONS**

**Class I**

1. **Vascular surgical reconstruction is indicated for patients with fibromuscular dysplastic RAS with clinical indications for interventions (same as for PTA), especially those exhibiting complex disease that extends into the segmental arteries and those having macroaneurysms. *(Level of Evidence: B)***
2. **Vascular surgical reconstruction is indicated for patients with atherosclerotic RAS and clinical indications for intervention, especially those with multiple small renal arteries or early primary branching of the main renal artery. *(Level of Evidence: B)***
3. **Vascular surgical reconstruction is indicated for patients with atherosclerotic RAS in combination with pararenal aortic reconstructions (in treatment of aortic aneurysms or severe aortoiliac occlusive disease). *(Level of Evidence: C)***

#### *3.5.4.1. Fibromuscular Dysplasia*

Operative therapy for treatment of FMD, be it performed in situ or ex vivo, is undertaken in 2 basic modes with either (a) an aortorenal bypass or (b) a nonanatomic bypass (781,782). In situ revascularizations are preferred in that disruption of preexisting collateral vessels does not accompany this type of reconstructive procedure. However, ex vivo revascularizations are appropriate in certain patients with complex disease, especially that which affects multiple segmental vessels or that is associated with macroaneurysmal disease of these smaller arteries (783).

Age and the status of the aorta become important determinants of the type of in situ operation. In patients less than 21 years of age, vein grafts are avoided because of the potential for late aneurysmal degeneration (784). Internal iliac artery grafts are favored in younger patients and in occasional older

**Table 39.** Renal Stent Placement Procedural Outcomes

| First Author | Date | Reference | Arteries (n) | Success* (%) | Restenosis (%) |
|---|---|---|---|---|---|
| White | 1997 | (738) | 133 | 99 | 18.8 |
| Blum | 1997 | (733) | 74 | 100 | 11 |
| Tuttle | 1998 | (734) | 148 | 98 | 14 |
| Henry | 1999 | (735) | 209 | 99 | 11.4 |
| van de Ven | 1999 | (700) | 43 | 90 | 14 |
| Rocha-Singh | 1999 | (736) | 180 | 97 | 12 |
| Lederman | 2001 | (739) | 358 | 100 | 21 |

*Definitions of procedural success vary in each study.
n indicates number of patients.

patients. Vein grafts are favored in most patients 21 years and older in whom the aorta is relatively normal. In patients with no suitable vein, synthetic conduits of PTFE or polyester filament may be used, but these materials are not favored over autologous grafts in younger individuals.

In patients with an aorta encased in scar tissue from previous surgery or in whom clamping of the aorta would be hazardous because of severe ventricular dysfunction, a nonanatomic revascularization, in the form of a hepatorenal, splenorenal, or iliorenal reconstruction, would be appropriate (785). A normal, undiseased celiac artery is necessary for the performance of a hepatorenal or splenorenal bypass.

A secondary nephrectomy may be necessary to provide adequate blood pressure control in those patients whose primary operation has failed when attempts at re-revascularization have been unsuccessful (3,12). In rare circumstances, a kidney will initially appear to be hypoplastic or will exhibit irreparable ischemic atrophy. When the contralateral kidney appears normal, a primary nephrectomy may be performed. Dysplastic renal artery stenoses in pediatric-aged patients are usually treated by open surgery, although balloon angioplasty or transcatheter alcohol ablation of the renal parenchyma beyond isolated intrarenal webs may be successfully used in select patients (786-788).

### *3.5.4.2. Arteriosclerotic Renal Artery Occlusive Disease*

Unilateral isolated nonostial RAS in the case of normal renal function is usually treated by percutaneous balloon angioplasty with stenting in lieu of operative therapy (789-791), although with abnormal renal function, surgical treatment may be performed in select patients (782,792,793). Unilateral and bilateral ostial stenoses account for most arteriosclerotic renovascular disease. In the case of unilateral disease and normal renal function, either balloon angioplasty or operative therapy provides acceptable results, although less-invasive endovascular therapy is usually the preferred modality. If restenosis after PTA is severe enough to warrant surgical operation, it can result in secondary nephrectomy (794).

Operative therapy, when undertaken for arteriosclerotic renovascular disease, must consider the status of the aorta. A nonanatomic bypass is appropriate in the case of a hostile aorta due to intrinsic disease that is nontreatable without inordinate patient risks or in instances of very poor cardiac function where aortic cross-clamping would be hazardous. In patients who require open surgical treatment of AAAs or severe aortoiliac occlusive disease, a concomitant aortic reconstruction and an aortorenal bypass or endarterectomy may be performed (782,792,795-797). These latter 2 options also exist in the case of a normal aorta, with an aortorenal bypass favored in treatment of single renal artery disease and aortorenal endarterectomy favored for treatment of multiple renal arteries to the same kidney, as well as in treatment of bilateral disease.

Nonanatomic bypass is an important means of renal revascularization in select patients, provided that flow within the donor artery is normal. When hepatorenal or splenorenal bypasses are created, no significant celiac artery stenoses should be present. For iliorenal bypasses, no pressure gradients across the aorta or proximal iliac arteries should be present, lest they impair graft flow.

Aortorenal bypass is the most common open surgical means of treating arteriosclerotic renovascular disease (782,795). Reversed saphenous vein is the favored conduit when small renal arteries are being bypassed or multiple vessel reconstructions are being performed. For reconstruction of a large poststenotic renal artery, especially when the graft originates from a concurrently placed synthetic aortic prosthesis, use of a PTFE or polyester filament graft is acceptable.

Aortorenal endarterectomy is preferred by many surgeons, especially when undertaken in concert with an aortic reconstructive operation (797). This form of renal revascularization is generally considered more technically demanding than a nonanatomic bypass or a conventional bypass (796). It is often performed through an axial aortotomy that extends from the level of the superior mesenteric artery to the infrarenal aorta or through the transected aorta at the time of the aortic reconstruction. The axial transaortic approach has particular applicability for treatment of bilateral and multiple renal artery ostial stenoses, as well as when coexistent celiac and superior mesenteric arterial stenoses need to be treated. A direct renal arteriotomy and endarterectomy has certain advantages for treatment of complex disease that extends into early branchings of the renal artery, but it is performed much less often than transaortic endarterectomy.

Secondary nephrectomy should only be done after reconstructive failures are deemed impossible to salvage with reoperation (798,799). Irreparable ischemic atrophy or injury in some patients may be a consequence of advanced arteriosclerotic occlusive disease. It is most likely to exist when (a) radionuclide scan evidence exists that the kidney contributes less than 10% of the total renal function, (b) the kidney length is less than 5 cm, or (c) there is evidence of extensive cortical infarction. In such circumstances, especially if the serum creatinine is less than 3 mg per dL, a primary nephrectomy may be appropriate. Renal revascularizations are unlikely to improve either blood pressure control or renal function in these patients.

Primary nephrectomy is performed in select patients in whom operative or catheter-based procedures are not possible, and only when a benefit, especially regarding blood pressure control, is expected after removal of the kidney (800,801). The technique of primary intracapsular nephrectomy is the same as with secondary nephrectomy.

### *3.5.4.3. Results of Operative Therapy*

Renal preservation and maintenance of renal function are important in the assessment of clinical experiences. Nephrectomy will usually not offer as much benefit as revas-

**Table 40.** Surgical Revascularization of Fibrodysplastic Renovascular Hypertension in Adults

| Institution | No. of Patients | Operative Outcome (%) | | | Surgical Mortality (30-Day) Rate (%) |
|---|---|---|---|---|---|
| | | Cured | Improved | Failed | |
| University of Michigan | 144 | 55 | 39 | 6 | 0 |
| Baylor College of Medicine | 113 | 43 | 24 | 33 | 0 |
| Cleveland Clinic | 92 | 58 | 31 | 11 | Unstated |
| University of California, San Francisco | 77 | 66 | 32 | 1.3 | 0 |
| Mayo Clinic | 63 | 66 | 24 | 10 | Unstated |
| University Hospital Leiden, the Netherlands | 53 | 53 | 34 | 13 | 2 |
| Vanderbilt University | 44 | 72 | 24 | 4 | 2.3 |
| Columbia University | 42 | 76 | 14 | 10 | Unstated |
| Bowman Gray | 40 | 33 | 57 | 10 | 0 |
| University of Lund, Malmo, Sweden | 40 | 66 | 24 | 10 | 0 |

Adapted with permission from Stanley JC. The evolution of surgery for renovascular occlusive disease. Cardiovasc Surg. 1994;2:195-202 (781).

cularization. Even when nephrectomy provides good results, it leaves the patient at considerable risk if contralateral disease occurs later. Improved renal function after revascularization is well recognized and is most likely to occur among patients exhibiting arteriosclerotic disease with a relatively sudden onset of renal function impairment.

Surgical treatment of renovascular hypertension affords good clinical outcomes (802-806). The risk of surgery increases in patients who require concomitant aortic reconstruction, in patients with renal insufficiency, and when aortic grafts are used as a source of the bypass graft. The need for reoperation has been reported in 5% to 15% of patients, with survival in 65% to 81% of patients (802-806). Differences among most individual experiences reflect variations in the prevalence of different renovascular disease categories. Arterial fibrodysplastic renovascular hypertension (Table 40) is more likely to benefit from surgical revascularization than is arteriosclerotic renovascular hypertension (Table 41). This is probably a reflection of coexistent essential hypertension in older patients with arteriosclerotic dis-

**Table 41.** Surgical Revascularization of Arteriosclerotic Renovascular Hypertension in Adults

| Institution | No. of Patients | Operative Outcome (%) | | | Surgical Mortality (30-Day) Rate (%) |
|---|---|---|---|---|---|
| | | Cured | Improved | Failed | |
| Baylor College of Medicine | 360 | 34 | 31 | 35 | 2.5 |
| Bowman Gray | 152 | 15 | 75 | 10 | 1.3 |
| University of Michigan | 135 | 29 | 52 | 19 | 4.4 |
| University of California, San Francisco | 84 | 39 | 23 | 38 | 2.4 |
| Cleveland Clinic | 78 | 40 | 51 | 9 | 2 |
| Columbia University | 67 | 58 | 21 | 21 | Unstated |
| University of Lund, Malmo, Sweden | 66 | 49 | 24 | 27 | 0.9 |
| Hospital Aiguelongue, Montpellier, France | 65 | 45 | 40 | 15 | 1.1 |
| Vanderbilt University | 63 | 50 | 45 | 5 | 9 |

Adapted with permission from Stanley JC. The evolution of surgery for renovascular occlusive disease. Cardiovasc Surg. 1994;2:195-202 (781).

ease. Arteriosclerotic renovascular hypertension occurs in 2 subgroups of patients: (a) those with focal renal artery disease whose only clinical manifestation of arteriosclerosis is secondary hypertension and (b) those with clinically overt extrarenal arteriosclerosis that affects the coronary artery, carotid artery, aorta, or extremity vessels. The severity and duration of hypertension, age, and gender in these 2 subgroups are similar, yet the surgical outcome regarding amelioration of hypertension is worse in patients with overt extrarenal arteriosclerotic disease.

Surgery was compared with balloon angioplasty for renal artery revascularization in a randomized clinical trial in hypertensive patients with atherosclerotic RAS (731). At the 2-year follow-up interval, the surgery group had a higher primary patency rate than the balloon angioplasty group (95% vs. 75%, $p$ equals 0.05); however, there was no difference in the secondary patency rate between the groups (balloon 90% vs. surgery 97%, $p$ equals 0.61). The clinical end points of hypertension control and renal function preservation were not different for angioplasty or surgery. Major complications were seen in twice as many surgical patients (34%) as balloon angioplasty patients (17%). The authors concluded that in patients with RAS who were candidates for either surgery or balloon angioplasty, balloon angioplasty should be the first choice of therapy. One retrospective trial comparing outcomes and costs associated with endovascular and surgical revascularization described similar clinical outcomes but a nearly 6-fold greater initial cost for surgery (807).

# 4. MESENTERIC ARTERIAL DISEASE

All diseases and conditions that affect the arteries have been reported in the arteries that supply the intestines, including atherosclerosis, arteritis, aneurysms, arterial infections, FMD, dissections, arterial emboli, and thrombosis. The evidence and recommendations in this section of the guideline are directed at the various causes and treatment of the most common vascular problem affecting the intestines, ischemia. Because there are major differences in presentation, the sections are divided into acute and chronic intestinal ischemia. Acute intestinal ischemia is most frequently caused by arterial obstruction but also occurs in the absence of intestinal arterial obstruction (e.g., nonocclusive mesenteric ischemia seen in low flow states). Chronic intestinal ischemia is always the result of arterial obstruction. Regardless of cause, intestinal ischemia is rare. This means that there are no randomized or controlled trials of diagnosis or therapy for intestinal ischemia, acute or chronic, regardless of cause. There are important gaps in our knowledge of the natural history of intestinal ischemia, especially with regard to the number of persons with asymptomatic intestinal arterial obstructions who eventually become symptomatic. Despite this, the condition and the primary diagnoses responsible for most cases have been known for decades. Numerous series documenting the results of surgical treatment have been reported, and recently, the clinical course of a number of patients' case series treated by percutaneous intervention has also been documented. These largely retrospective clinical reviews form the basis for our knowledge of and recommendations for treatment of intestinal ischemia.

## *4.1. Acute Intestinal Ischemia*

### 4.1.1. Acute Intestinal Ischemia Caused by Arterial Obstruction

#### *4.1.1.1. Etiology*

Acute obstructive intestinal ischemia occurs when the intestinal arteries are suddenly blocked to a degree that all or part of the intestine has insufficient perfusion for viability. The many possible causes include embolism from cardiac or proximal arterial sources (including arterial debris dislodged during percutaneous interventions) and arterial thrombosis, either of arteries chronically stenosed by atherosclerosis or as a result of a hypercoagulable state or an acute arterial dissection (807-812).

Regardless of the cause, patients with acute intestinal ischemia have severe abdominal pain that is initially out of proportion to any physical findings that may be present. This is because peritoneal irritation that leads to abdominal tenderness takes hours to develop, and distention, rigidity, guarding, and systemic symptoms of vascular collapse may take days to manifest and are best correlated with intestinal perforation.

#### *4.1.1.2. Diagnosis*

**RECOMMENDATIONS**

**Class I**

1. **Patients with acute abdominal pain out of proportion to physical findings and who have a history of cardiovascular disease should be suspected of having acute intestinal ischemia.** ***(Level of Evidence: B)***
2. **Patients who develop acute abdominal pain after arterial interventions in which catheters traverse the visceral aorta or any proximal arteries or who have arrhythmias (such as atrial fibrillation) or recent MI should be suspected of having acute intestinal ischemia.** ***(Level of Evidence: C)***

**Class III**

**In contrast to chronic intestinal ischemia, duplex sonography of the abdomen is not an appropriate diagnostic tool for suspected acute intestinal ischemia.** ***(Level of Evidence: C)***

CLINICAL PRESENTATION. Approximately two thirds of patients with acute intestinal ischemia are women, with a median age of 70 years. Most patients have a history of preexisting cardiovascular disease (807-810). Abdominal pain is always present; its nature, location, and duration are variable, but most commonly, the pain is anterior, periumbilical, and sufficiently severe that medical attention is sought immediately. Initially, signs of peritoneal irritation are absent, which

is classically referred to as "pain out of proportion to physical findings."

LABORATORY FINDINGS. Laboratory evaluation most frequently shows leukocytosis and lactic acidosis, and amylase is elevated in approximately 50% of patients; approximately 25% of patients have occult blood in the stool. Abdominal radiographs most frequently show some dilated loops of intestine. There are no specific laboratory or plain radiograph findings for acute intestinal ischemia.

ULTRASOUND. Because duplex ultrasound scanning is capable of identifying occlusive lesions of the intestinal arteries, this test is theoretically attractive for diagnosis of acute intestinal ischemia. In practice, it is not very helpful. This is because duplex scanning of the deeply located intestinal arteries is technically demanding, requiring ideal conditions for success (e.g., fasting patients and early morning examinations to avoid excessive intestinal gas). The abdominal distention and fluid frequently present with acute ischemia precludes successful scanning in most patients. Because of the need for emergent treatment in acute ischemia and the time required to attempt duplex scanning, this test is contraindicated.

COMPUTED TOMOGRAPHIC SCANNING. Computed tomographic scans are frequently performed in patients with acute abdominal pain. Computed tomographic findings suggestive of intestinal ischemia include atherosclerotic disease of intestinal arteries and obvious thrombosis of proximal intestinal arteries, as well as intestinal distention, intestinal wall thickening, intraabdominal fluid, and intestinal perforation. These findings may also be present in patients without intestinal ischemia. Computed tomographic findings suggestive of intestinal ischemia include pneumatosis intestinalis and portal venous air, both of which are late findings. Because computed tomographic scanning for evaluation of abdominal pain requires administration of intravenous iodinated contrast material, which may affect later arteriography, this test is not the best initial examination for suspected acute intestinal ischemia, although it is frequently performed before consideration of the mesenteric ischemia diagnosis.

ARTERIOGRAPHY. Arteriography is the most helpful diagnostic test in patients suspected of having acute intestinal ischemia; however, its use is controversial because of the time required for its performance in the emergency setting. In patients suspected of having intestinal ischemia, arteriography can be diagnostic and can differentiate occlusive from nonocclusive ischemia. Furthermore, catheter-directed therapy of arterial occlusions with intra-arterial vasodilators, thrombolysis, or mechanical thrombectomy devices is possible in some patients with acute ischemia. If surgical treatment is required, knowledge of the extent and nature of intestinal arterial lesions is helpful.

The decision for arteriography is probably best individualized in patients suspected of having acute intestinal ischemia. For those with a very acute presentation, a high likelihood of arterial obstruction, and suspected bowel infarction, immediate laparotomy by a surgeon capable of intestinal revascularization is the best approach. In patients with acute onset in whom angiography can be performed rapidly and without delay, this is a reasonable approach. For those with a more delayed presentation or a high likelihood of nonocclusive ischemia, initial arteriography is indicated. In these cases, the advantages of the additional information provided by arteriography outweigh the time required for its performance.

### *4.1.1.3. Natural History*

All series of acute intestinal ischemia patients include some who had a history of chronic abdominal pain and weight loss. The frequency with which chronic intestinal ischemia caused by arterial obstruction becomes acute intestinal ischemia (presumably by thrombosis) is unknown.

The natural history of acute intestinal ischemia caused by obstruction of intestinal arteries in the absence of treatment is nearly always fatal. Intestinal ischemia leads to infarction, perforation, peritonitis, and death in the vast majority of patients. A few exceptions occur in which the ischemic injury may be confined to the mucosal layer of the intestine, or in which the gradual development of collateral circulation may result in resolution of the ischemia before infarction. Although such patients are well recognized, they are rare compared with those who do not recover. The exact percentage is unknown (808,809,813-818). The focus of treatment in patients with acute mesenteric ischemia is to provide an aggressive and rapid diagnosis to minimize the amount of ischemic bowel that will progress to infarction, while rapidly instituting appropriate therapy.

### *4.1.1.4. Surgical Treatment*

**RECOMMENDATION**

**Class I**

**Surgical treatment of acute obstructive intestinal ischemia includes revascularization, resection of necrotic bowel, and, when appropriate, a "second look" operation 24 to 48 hours after the revascularization.** ***(Level of Evidence: B)***

Despite treatment, acute intestinal ischemia caused by arterial obstruction is most often fatal. Various surgical series show both that treatment outcome has changed little during the past several decades and that mortality averages approximately 70% (808,809,813-817). The reason for this grim prognosis is found in the time course of the signs and symptoms of the disease. Because patients present initially with abdominal pain and few findings, diagnosis is often delayed. By the time the diagnosis is obvious because of abdominal distention, perforation, shock, and so on, ischemia is far advanced, and survival is doubtful, despite treatment.

Surgical treatment consists of laparotomy, revascularization of the ischemic intestine either by embolectomy or bypass grafting, assessment of the viability of the intestine

after revascularization, resection of nonviable intestine, and intensive care. Frequently, some intestine is clearly viable, some is clearly nonviable, and some is questionable. No intraoperative diagnostic test has yet been described that is superior to the clinical judgment of experienced surgeons in determining intestinal viability (819). Scheduled "second look" operations, 24 to 48 hours after the initial procedure, are the best way to avoid both excessive resection of potentially viable bowel and failure to resect nonviable intestine.

#### *4.1.1.5. Endovascular Treatment*

**RECOMMENDATION**

**Class IIb**

**Percutaneous interventions (including transcatheter lytic therapy, balloon angioplasty, and stenting) are appropriate in selected patients with acute intestinal ischemia caused by arterial obstructions. Patients so treated may still require laparotomy. *(Level of Evidence: C)***

Acute intestinal ischemia caused by arterial obstructions is most frequently the result of occlusion of the proximal portion of the superior mesenteric artery either by thrombosis at the site of atherosclerosis or by localized arterial embolism. It is reasonable to consider the role of lytic therapy, balloon angioplasty/stenting, or both as definitive treatment, especially in view of the dismal results associated with standard surgical therapy.

Several isolated reports of percutaneous interventional treatment of superior mesenteric artery obstruction producing acute intestinal ischemia have been published (820-822). Because most patients with acute intestinal ischemia have at least some nonviable intestine at the time of presentation, most will still require laparotomy and surgical assessment of the intestinal viability. This approach may be required even if percutaneous therapy is successful in relieving the obstruction. However, re-establishment of flow to infarcted bowel may cause a sudden systemic release of endotoxins, which may be associated with the sudden onset of disseminated intravascular coagulation, adult respiratory distress syndrome, and sudden cardiovascular collapse. Therefore, in the presence of infarcted bowel or markedly elevated lactic acid levels, initial percutaneous treatment should be weighed against surgical options in which control of the venous outflow (and the endotoxins) from the infarcted bowel segment can be achieved.

Although only a few cases have been reported, further exploration of this approach to acute ischemia seems appropriate. Percutaneous treatment of the arterial obstruction greatly reduces the magnitude of the surgical procedure that is required, and the high mortality associated with the standard approach means that investigation of alternative approaches is appropriate.

### 4.1.2. Acute Nonocclusive Intestinal Ischemia

#### *4.1.2.1. Etiology*

**RECOMMENDATIONS**

**Class I**

1. **Nonocclusive intestinal ischemia should be suspected in patients with low flow states or shock, especially cardiogenic shock, who develop abdominal pain. *(Level of Evidence: B)***
2. **Nonocclusive intestinal ischemia should be suspected in patients receiving vasoconstrictor substances and medications (e.g., cocaine, ergots, vasopressin, or norepinephrine) who develop abdominal pain. *(Level of Evidence: B)***
3. **Nonocclusive intestinal ischemia should be suspected in patients who develop abdominal pain after coarctation repair or after surgical revascularization for intestinal ischemia caused by arterial obstruction. *(Level of Evidence: B)***

Acute intestinal ischemia sufficient to produce infarction also occurs in the absence of fixed arterial obstruction. The most frequent setting is severe systemic illness with systemic shock, usually as a result of reduced cardiac output (808,823-827). In this situation, the intestinal ischemia has been shown to be the result of severe and prolonged intestinal arterial vasospasm. Before modern intensive care and vasodilator treatment of congestive heart failure, nonocclusive intestinal ischemia was quite common. With the advent of this therapy, it has become rare.

Intestinal vasospasm sufficient to produce ischemia/infarction also occurs as a result of cocaine ingestion and ergot poisoning (828,829). Therapeutic drugs may produce intestinal ischemia from vasospasm, especially when vasopressors are used in high doses to treat circulatory shock.

Intestinal ischemia can also occur as a result of mesenteric arterial spasm after repair of aortic coarctation (830) and occasionally occurs after revascularization procedures for chronic mesenteric ischemia (825). The mechanism of this apparently paradoxical spasm is unknown.

#### *4.1.2.2. Diagnosis*

**RECOMMENDATION**

**Class I**

**Arteriography is indicated in patients suspected of having nonocclusive intestinal ischemia whose condition does not improve rapidly with treatment of their underlying disease. *(Level of Evidence: B)***

Nonocclusive mesenteric ischemia should be suspected whenever patients with circulatory shock, especially cardiogenic shock, develop abdominal pain and/or distention. Because such patients are seriously ill, often with a decreased level of consciousness, diagnosis may be delayed.

In modern practice, nearly all ergot poisoning is the result of use/misuse of therapeutic ergot preparations intended to treat migraine headaches. The diagnosis of nonocclusive intestinal ischemia should be suspected in persons using cocaine or amphetamines who have abdominal pain.

There are no physical findings or laboratory tests specific for nonocclusive intestinal ischemia. Arteriography is the "gold standard" study. It can demonstrate the characteristic mesenteric arterial vasospasm and allow direct intra-arterial instillation of vasodilator medications (824,826,829).

#### *4.1.2.3. Treatment*

**RECOMMENDATIONS**

**Class I**

1. **Treatment of the underlying shock state is the most important initial step in treatment of nonocclusive intestinal ischemia.** ***(Level of Evidence: C)***
2. **Laparotomy and resection of nonviable bowel is indicated in patients with nonocclusive intestinal ischemia who have persistent symptoms despite treatment.** ***(Level of Evidence: B)***

**Class IIa**

**Transcatheter administration of vasodilator medications into the area of vasospasm is indicated in patients with nonocclusive intestinal ischemia who do not respond to systemic supportive treatment and in patients with intestinal ischemia due to cocaine or ergot poisoning.** ***(Level of Evidence: B)***

Initial treatment of nonocclusive intestinal ischemia should be directed at treatment of the underlying shock state. The most intensive hemodynamic monitoring possible, including appropriate fluid/pharmacological therapy to improve cardiac output/peripheral perfusion, is the most reliable way to relieve the inappropriate vasospasm.

Administration of vasodilators by percutaneously placed catheters at the site of inappropriate vasospasm has been associated with relief of vasospasm/ischemic symptoms in multiple patients (823). Because of the complete absence of any controlled trials, it is not possible to determine whether the improvement that occurred was the result of the systemic or local effects of the vasodilators or the result of simultaneous treatment of the systemic condition.

Transcatheter administration of vasodilators is especially appropriate in nonocclusive mesenteric ischemia caused by drugs such as ergot or cocaine, in which systemic shock may not coexist (831). Abdominal symptoms/findings that persist after relief of intestinal arterial vasospasm are an indication for laparotomy/resection of necrotic intestine.

There are few level I or II data on treatments for acute mesenteric ischemia caused by mesenteric venous thromboses, internal or external hernias, vasculitides, or aortic dissections, and therefore, a formal discussion of these causes is not included in this document.

## *4.2. Chronic Intestinal Ischemia*

### 4.2.1. Etiology

Although atherosclerotic disease of the celiac and mesenteric vessels is common, the clinical presentation of chronic intestinal ischemia is rare. It is nearly uniformly caused by atherosclerosis (832). Other rare causes include Buerger's disease (812,833), fibromuscular dysplasia/dissection, and aortic dissection, but these are very rare causes of an already rare syndrome. The celiac, superior mesenteric, and inferior mesenteric arteries are all extensively interconnected, to a degree that means that in usual circumstances, proximal occlusion by atherosclerosis of any one is well tolerated (832). Although classic clinical approaches to the diagnosis of intestinal ischemia have often suggested that this syndrome requires occlusion or stenosis of at least 2 of the 3 intestinal arteries, this is not entirely true (833,834). Well-documented cases of intestinal ischemia occur as a result of single-vessel disease, virtually always of the superior mesenteric artery. Patients in whom some of the normal collateral intestinal arterial connections have been interrupted by previous surgery are especially vulnerable to single-vessel occlusions.

Patients with chronic intestinal ischemia are most often female (70%) and classically complain of severe abdominal pain induced by eating. The pattern of pain is quite variable, however, and the relationship to food is not always clear, at least by history. What is clear is that patients voluntarily vastly reduce their food intake, so that weight loss occurs, and this may be profound. Vomiting, diarrhea, and constipation are all present in a minority of patients. A majority have a history of cardiovascular disease, and 30% to 50% have had previous operations for atherosclerotic disease (most frequently coronary and lower extremity bypass) (835,836).

### 4.2.2. Diagnosis

**RECOMMENDATIONS**

**Class I**

1. **Chronic intestinal ischemia should be suspected in patients with abdominal pain and weight loss without other explanation, especially those with cardiovascular disease.** ***(Level of Evidence: B)***
2. **Duplex ultrasound, CTA, and gadolinium-enhanced MRA are useful initial tests for supporting the clinical diagnosis of chronic intestinal ischemia.** ***(Level of Evidence: B)***
3. **Diagnostic angiography, including lateral aortography, should be obtained in patients suspected of having chronic intestinal ischemia for whom noninvasive imaging is unavailable or indeterminate.** ***(Level of Evidence: B)***

#### *Clinical Presentation*

Because there are many common causes of abdominal pain and weight loss, and because chronic intestinal ischemia is

rare, diagnosis is delayed in most patients. Many patients in whom the diagnosis is made have been symptomatic for months or even years and have undergone the gamut of abdominal diagnostic procedures, including contrast X-ray studies, endoscopy, and multiple scans. The profound weight loss that occurs suggests a diagnosis of malignancy, which leads to further imaging studies.

### *Laboratory Testing*

Although multiple tests of intestinal absorption and others have been proposed for diagnosis of chronic intestinal ischemia, none has proven worthwhile. At present, there are no laboratory abnormalities that are diagnostic.

### *Duplex Scanning*

The atherosclerotic lesions that typically produce intestinal arterial obstruction are usually located at the origin of the vessels from the aorta and are actually protruding aortic plaques in most (833). This feature makes the lesions suitable for diagnosis by duplex ultrasound. Duplex scanning of visceral vessels is technically difficult but can be accomplished in more than 85% of subjects in the elective setting. The test has an overall accuracy of approximately 90% for detection of greater than 70% diameter stenoses or occlusions of the celiac and superior mesenteric arteries when performed in highly experienced laboratories (837-839). Although the expected increase in intestinal arterial flow that results from food ingestion can be detected and quantified by duplex scanning, this information has not added to the diagnostic accuracy of the test for establishing whether abdominal symptoms that are present are the result of intestinal ischemia (840).

### *Computed Tomography/MRA*

Both contrast-enhanced CTA and gadolinium-enhanced MRA are well suited for visualizing the typical atherosclerotic lesions at the origins of the intestinal arteries that are implicated in most cases of chronic intestinal ischemia. These techniques are presently less suited for visualizing the more distal intestinal arteries and for diagnosis of some of the more unusual causes of intestinal ischemia.

### *Arteriography*

Arteriograms provide definitive diagnosis of intestinal arterial lesions. Lateral aortography is best suited for display of the typical origin lesions, which may not be apparent on frontal projections. The presence of an enlarged "arc of Riolan" (an enlarged collateral vessel connecting the left colic branch of the inferior mesenteric artery with the superior mesenteric artery) is an arteriographic sign of proximal mesenteric arterial obstruction that is visible on anteroposterior aortograms. Selective arteriography of the intestinal vessels may fail to visualize the typical atherosclerotic origin lesions because the selective catheter may be positioned beyond them in the affected vessel.

### *Approach to Diagnosis*

Although multiple diagnostic techniques are available to demonstrate diseased intestinal vessels, such lesions are actually quite common, whereas symptomatic intestinal ischemia is rare. At present, there are no diagnostic tests that establish the diagnosis definitively. Rather, it is the combination of the typical clinical presentation of abdominal pain and weight loss, with other evidence of cardiovascular disease, and the finding of intestinal arterial obstruction in the absence of other obvious cause of the symptoms that should lead to consideration of the diagnosis.

## 4.2.3. Natural History

Significant atherosclerotic obstruction of the intestinal arteries is present in 6% to 10% of unselected autopsies and in 14% to 24% of patients undergoing abdominal arteriography. The fact that nearly all such patients have no symptoms of intestinal ischemia is a reflection of the extensive collateral connections present among the intestinal arteries (832). Only one study (841) has addressed the issue of how many patients with asymptomatic intestinal arterial lesions ultimately develop intestinal ischemia. Of 980 abdominal aortograms, there were 15 patients who had severe stenosis or occlusions of all 3 intestinal vessels, of whom 4 developed symptomatic intestinal ischemia with a mean follow-up of 2.6 years. No patients who had fewer than 3 severely affected vessels developed symptoms (841).

Development of symptomatic intestinal ischemia in patients with asymptomatic intestinal arterial obstruction after abdominal surgery for other reasons has been described (842). The presumed mechanism is division of vital collaterals during the surgical procedure. This sequence of events has been most frequently recognized after abdominal vascular surgery (e.g., aortic aneurysm or renal artery repair). The frequency with which this complication occurs is unknown.

The natural history of symptomatic chronic intestinal ischemia is known in part. An unknown percentage of patients progress to acute intestinal ischemia, and the remainder have progressive weight loss with ultimate death from inanition. Although it is reasonable to postulate that some of the affected patients must experience spontaneous recovery, no such case has been documented in the literature.

## 4.2.4. Interventional Treatment

**RECOMMENDATION**

**Class I**

**Percutaneous endovascular treatment of intestinal arterial stenosis is indicated in patients with chronic intestinal ischemia.** ***(Level of Evidence: B)***

Percutaneous treatment of symptomatic intestinal ischemia was first reported in 1980 (843). Since then, a large number of reports in the literature have documented that percutaneous interventional treatment of intestinal arterial obstruc-

tions is possible with a high technical success rate and few complications in properly selected cases (844-849). Most procedures have been performed to treat intestinal arterial stenoses, with few attempting to treat occlusions. To date, there have been no prospective therapeutic trials, and follow-up information is limited; that which exists indicates that elimination of the arterial obstruction is reliably followed by relief of symptoms and weight gain. Several reports of concurrent series treated by angioplasty/stenting or surgery indicate that recurrences after percutaneous procedures have been more frequent than after open surgery, but many of the recurrences can be managed by percutaneous interventions (850). The results of several series are listed in Table 42. The reported recurrence rates mandate careful follow-up of patients treated with angioplasty and stents. As with open surgery, recurrent symptoms have nearly always indicated recurrent arterial obstruction.

### 4.2.5. Surgical Treatment

**RECOMMENDATIONS**

**Class I**

**Surgical treatment of chronic intestinal ischemia is indicated in patients with chronic intestinal ischemia.** ***(Level of Evidence: B)***

**Class IIb**

**Revascularization of asymptomatic intestinal arterial obstructions may be considered for patients undergoing aortic/renal artery surgery for other indications.** ***(Level of Evidence: B)***

**Class III**

**Surgical revascularization is not indicated for patients with asymptomatic intestinal arterial obstructions, except in patients undergoing aortic/renal artery surgery for other indications.** ***(Level of Evidence: B)***

Surgical treatment of chronic intestinal ischemia is accomplished by endarterectomy or bypass grafting, with the majority of surgeons preferring the latter approach (836,851-858). The overall operative mortality and durability of revascularization in chronic cases described by multiple contemporary reports are listed in Table 42. Long-term patency and relief of symptoms are the rule, with few recurrences; however, long-term follow-up is mandatory. Essentially all symptomatic recurrences are the result of recurrent stenosis or occlusion of visceral arteries or the reconstructions.

## STAFF

***American College of Cardiology***

Tom Arend, Interim Chief Staff Officer

Marie Temple, Specialist, Knowledge Development

Joseph Allen, MS, Research Analyst, Knowledge Development

Deborah Steinbach, MA, Managing Editor, Knowledge Development

Peg Christiansen, Librarian, Knowledge Development

***American Heart Association***

M. Cass Wheeler, Chief Executive Officer

Rose Marie Robertson, MD, FACC, FAHA, Chief Science Officer

Kathryn A. Taubert, PhD, FAHA, Senior Science Advisor

**Table 42.** Single-Institution Comparisons of Mesenteric Angioplasty/Stenting Versus Surgery

| First Author and Procedure | Year | Reference | No. of Patients | Successfully Revascularized (%) | 30-Day Mortality (%) | Recurrence (%) |
|---|---|---|---|---|---|---|
| Kasirajan* | 2001 | (850) | | | | |
| Angioplasty | | | 28 | 93 | 11 | 27 |
| Surgery | | | 85 | 98 | 8 | 24 |
| Rose† | 1995 | (850a) | | | | |
| Angioplasty/stenting | | | 8 | 80 | 13 | 33 |
| Surgery | | | 9 | 100 | 11 | 22 |
| Bowser‡ | 2002 | (850b) | | | | |
| Angioplasty/stenting | | | 18 | 88 | 11 | 46 |
| Surgery | | | 22 | 100 | 9 | 19 |

*Surgical controls were historic; mean postprocedure follow-up was 3 years for both groups.
†Mean follow-up for surgery was 3 years; for angioplasty/stenting, 9 months.
‡Mean follow-up was 14 months.

**APPENDIX 1.** ACC/AHA Writing Committee to Develop Guidelines on Peripheral Arterial Disease (Lower Extremity, Renal, Mesenteric, and Abdominal Aortic)

| Committee Member | Research Grant | Speakers Bureau/ Honoraria | Stock Ownership | Consultant | Advisory Board |
|---|---|---|---|---|---|
| Dr Curtis W. Bakal | None | None | None | None | Berlex Labs<br>Abbott Labs |
| Dr Mark A. Creager | Eli Lilly<br>Otsuka Pharmaceuticals<br>Pfizer<br>Vasogen | Bristol Myers Squibb/<br>Sanofi Partnership<br>Otsuka Pharmaceuticals | Northport Domain | None | Bristol Myers Squibb/<br>Sanofi<br>Genvec<br>Geozyme<br>Northport Domain<br>Otsuka Pharmaceuticalse<br>Pfizer<br>Vasogen |
| Dr Jonathan L. Halperin | None | AstraZeneca, LP<br>Bristol Myers Squibb/<br>Sanofi Partnership | None | AstraZeneca, LP<br>Bayer AG<br>Boehringer Ingelheim<br>Bristol Myers Squibb/<br>Sanofi Partnership | AstraZeneca, LP |
| Dr Ziv J. Haskal | Bard/Impra<br>Boston Scientific<br>Cook<br>Cordis Endovascular<br>Genentech<br>IntraTherapeutics<br>W. L. Gore | TransVascular<br>W. L. Gore | None | Bard/Impra<br>Endosurgery<br>Ethicon<br>Omnisonics<br>TransVascular | TransVascular |
| Dr Norman R. Hertzer | None | None | None | None | None |
| Dr Loren F. Hiratzka | None | None | None | None | None |
| Dr Alan T. Hirsch | Alteon<br>AstraZeneca<br>Pharmaceuticals<br>Bristol Myers Squibb/<br>Sanofi Aventis Partnership<br>Kos Pharmaceuticals<br>Otsuka America<br>Pharmaceuticals | AstraZeneca<br>Pharmaceuticals<br>Bristol Myers Squibb/<br>Sanofi Aventis Partnership<br>Otsuka America<br>Pharmaceuticals<br>Pfizer | None | Sonosite<br>Vasogen | None |
| Dr William R.C. Murphy | None | None | None | None | None |
| Dr Jeffrey W. Olin | Bristol Myers Squibb/<br>Sanofi Partnership<br>Vasogen | None | None | Aventis<br>Bristol Myers Squibb/<br>Sanofi Partnership<br>Genzyme<br>Otsuka<br>Vasogen | Abbott<br>Aventis<br>Bristol Myers Squibb/<br>Sanofi Partnership<br>Genzyme |

*Continued on Next Page*

**APPENDIX 1.** *Continued*

| Committee Member | Research Grant | Speakers Bureau/ Honoraria | Stock Ownership | Consultant | Advisory Board |
|---|---|---|---|---|---|
| Dr Jules B. Puschett | None | None | None | None | None |
| Dr Kenneth A. Rosenfield | Abbott<br>Boston Scientific<br>Cordis<br>Guidant | Eli Lilly | CryoVascular | Abbott<br>Boston Scientific<br>Cordis<br>CryoVascular<br>Guidant | Abbott<br>Boston Scientific<br>Cordis<br>Guidant |
| Dr David Sacks | None | None | Angiotech | None | None |
| Dr James C. Stanley | None | None | None | None | None |
| Dr Lloyd M. Taylor, Jr | None | None | None | None | None |
| Dr Christopher J. White | None | Eli Lilly | None | None | None |
| Dr John White | None | None | None | None | None |
| Dr Rodney A. White | AVE<br>Bard<br>Baxter<br>Cordis J & J<br>EndoLogix<br>EndoSonics<br>Medtronic | Multiple relationships with commercial entities that arise and are met as needed | Several biomedical companies | None | None |

This table represents the relationships of committee members with industry that were disclosed at the initial writing committee meeting in November 2002 and that were updated in conjunction with all meetings and conference calls of the writing committee. It does not necessarily reflect relationships with industry at the time of publication.

**APPENDIX 2.** External Peer Reviewers for the ACC/AHA 2005 Guideline Update for Peripheral Arterial Disease (Lower Extremity, Renal, Mesenteric, and Abdominal Aortic)*

| Peer Reviewer Name* | Representation | Research Grant | Speakers Bureau/ Honoraria | Stock Ownership | Consultant/ Advisory Board |
|---|---|---|---|---|---|
| Dr Joshua A. Beckman | Content Reviewer – ACC PVD Committee | None | Merck | None | None |
| Dr James F. Benenati | Official Reviewer – AHA | None | None | None | None |
| Dr Ralph G. Brindis | Official Reviewer – ACC BOT | None | None | None | None |
| Dr Alan S. Brown | Official Reviewer – ACC BOG | AstraZeneca<br>Merck<br>Merck Schering Plough<br>Pfizer<br>Smith Kline Beecham | Merck<br>Merck Schering Plough<br>Pfizer | None | AstraZeneca<br>Merck<br>Merck Schering Plough |
| Rita C. Clark | Organizational Reviewer – SVN | None | None | None | None |
| Dr John P. Cooke | Content Reviewer – Individual | None | None | None | None |
| Dr Robert T. Eberhardt | Official Reviewer – AHA | None | None | None | None |
| Dr Brian S. Funaki | Content Reviewer – AHA Committee on PV Imaging and Intervention | None | None | None | None |
| Dr Bruce Gray | Organizational Reviewer – SVMB | None | None | None | None |
| Karen Hayden, MSN | Organizational Reviewer – SVN | None | None | None | None |
| Dr William R. Hiatt | Organizational Reviewer – TASC | None | BMS/Sanofi<br>Otsuka | None | BMS/Sanofi<br>Signature |
| Dr David Holmes, Jr | Content Reviewer – ACC BOG | None | None | None | None |
| Dr Sharon A. Hunt | Organizational Reviewer – ACC/AHA TF on PGL | None | None | None | None |
| Dr Michael R. Jaff | Organizational Reviewer – SVMB | None | OtsukaBMS/Sanofi | None | Cordis Endovascular |
| Dr Matthew S. Johnson | Content Reviewer – AHA Committee on PV Imaging and Intervention | Bard Access Systems<br>Boston Scientific | None | None | Boston Scientific |
| Dr John A. Kaufman | Content Reviewer – AHA Atherosclerosis PVD Steering Committee | None | None | None | None |
| Dr Morton Kern | Content Reviewer – AHA Diag and Interv Cardiac Cath Cmte | None | None | None | None |
| Dr Lloyd Klein | Content Reviewer – AHA Diag and Interv Cardiac Cath Cmte | TBD | TBD | TBD | TBD |

*Continued on Next Page*

**APPENDIX 2.** *Continued*

| Peer Reviewer Name* | Representation | Research Grant | Speakers Bureau/ Honoraria | Stock Ownership | Consultant/ Advisory Board |
|---|---|---|---|---|---|
| Dr Frank Lederle | Content Reviewer – Individual Review | None | None | None | None |
| Dr Jonathan Lindner | Official Reviewer – ACCF TF on CECD | None | None | None | None |
| Dr Mary M. McDermott | Content Reviewer – AHA Athero PVD PVD Steering Committee | None | None | None | None |
| Dr Alan Matsumoto | Content Reviewer – AHA Committee on PV Imaging and Intervention | None | Genentech | None | Cordis Endovascular Medtronic W. .L. Gore |
| Dr Roxana Mehran | Content Reviewer – Individual Review | Boston Scientific Cordis Medtronic | The Medicines Company Tyco/Mallinckrodt | None | None |
| Dr Emile R. Mohler III | Content Reviewer – Individual Review | None | None | None | None |
| Roberta Oka, RN | Content Reviewer – AHA Atherosclerosis PVD Steering Committee | None | None | None | None |
| Dr Joseph P. Ornato | Official Reviewer – ACC/AHA TF on PGL, Lead Reviewer | None | None | None | Genentech Meridian Revivant Wyeth |
| Dr Kenneth Ouriel | Content Reviewer – ACC PVD Committee | TBD | TBD | TBD | TBD |
| Dr William Pearce | Official Reviewer – AHA | None | None | None | None |
| Carolyn A. Robinson | Organizational Reviewer – SVN | None | None | None | None |
| Dr Robert D. Safian | Organizational Reviewer – SCAI | None | None | None | Boston Scientific Cordis/Johnson & Johnson eV3 Medtronic |
| Dr Sonia I. Skarlatos | Organizational Reviewer – NHLBI | None | None | None | None |
| Dr Kimberly A. Skelding | Content Reviewer – AHA Diag and Interv Cardiac Cath Cmte | None | None | None | None |
| Dr Vincenza Snow | Organizational Reviewer – ACP/ASIM | None | None | None | None |
| Dr Thomas L. Whitsett | Organizational Reviewer – SVMB | None | None | None | None |

This table represents the relationships of peer reviewers with industry that were disclosed at the time of peer review of this guideline. It does not necessarily reflect relationships with industry at the time of publication. Participation in the peer review process does not imply endorsement of the document.

*Names are listed in alphabetical order.

ACCF indicates American College of Cardiology Foundation; ACP, American College of Physicians; AHA Diag and Interv Cardiac Cath Cmte, AHA Diagnostic and Interventional Cardiac Catheterization Committee; ASIM, American Society of Internal Medicine; BOG, Board of Governors; BOT, Board of Trustees; NHLBI, National Heart, Lung, and Blood Institute; PV, peripheral vein; PVD, peripheral vascular disease; SCAI, Society for Cardiovascular Angiography and Interventions; SVMB, Society of Vascular Medicine and Biology; SVN, Society for Vascular Nursing; TBD, to be determined; TF on CECD, Task Force on Clinical Expert Consensus Documents; and TF on PGL, Task Force on Practice Guidelines.

## APPENDIX 3. ABBREVIATIONS

**ABI** = ankle-brachial index
**ACC** = American College of Cardiology
**ACE** = angiotensin-converting enzyme
**AHA** = American Heart Association
**ARIC** = Atherosclerosis Risk in Communities study
**bFGF** = basic fibroblast growth factor
**CI** = confidence interval
**CLI** = critical limb ischemia
**COPD** = chronic obstructive pulmonary disease
**CTA** = computed tomographic angiography
**DNA** = deoxyribonucleic acid
**DRASTIC** = Dutch Renal Artery Stenosis Intervention Cooperative
**EDTA** = ethylenediaminetetraacetic acid
**ESRD** = end-stage renal disease
**EUROSTAR** = EUROpean collaborators on Stent-graft Techniques for abdominal aortic Aneurysm Repair
**FDA** = Food and Drug Administration
**FMD** = fibromuscular dysplasia
**HDL** = high-density lipoprotein
**HMG** = hydroxymethyl glutaryl
**ICAVL** = Intersocietal Commission for Accreditation of Vascular Laboratories
**INR** = international normalized ratio
**LDL** = low-density lipoprotein
**MI** = myocardial infarction
**MMP** = matrix metalloproteinases
**MRA** = magnetic resonance angiography
**NHDS** = National Hospital Discharge Survey
**OR** = odds ratio
**p** = statistical significance
**PAD** = peripheral arterial disease
**PARTNERS** = PAD Awareness, Risk and Treatment: New Resources for Survival (study)
**PGE-1** = prostaglandin E1
**phVEGF165** = vascular endothelial growth factor plasma DNA
**PTA** = percutaneous transluminal angioplasty
**PTFE** = polytetrafluoroethylene
**PVR** = pulse volume recording
**RAS** = renal artery stenosis
**RRI** = resistive index
**ROS** = review of symptoms
**SVS/ISCVS** = Society for Vascular Surgery/ International Society for Cardiac Vascular Surgery
**TASC** = TransAtlantic Inter-Society Consensus Working Group
**TBI** = toe-brachial index
**3D** = 3-dimensional
**UK** = United Kingdom
**US** = United States
**USPSTF** = United States Preventive Services Task Force
**VA** = Veterans Affairs
**VEGF** = vascular endothelial growth factor

## References

1. Dormandy JA, Rutherford RB. Management of peripheral arterial disease (PAD). TASC Working Group. TransAtlantic Inter-Society Consensus (TASC). J Vasc Surg 2000;31(1 pt 2):S1-S296.
2. Ross R. Cellular and molecular studies of atherogenesis. Atherosclerosis 1997;131(suppl):S3-4.
3. Fowkes FG, Housley E, Riemersma RA, et al. Smoking, lipids, glucose intolerance, and blood pressure as risk factors for peripheral atherosclerosis compared with ischemic heart disease in the Edinburgh Artery Study. Am J Epidemiol 1992;135:331-40.
4. Ridker PM, Cushman M, Stampfer MJ, et al. Plasma concentration of C-reactive protein and risk of developing peripheral vascular disease. Circulation 1998;97:425-8.
5. Taylor LM Jr, DeFrang RD, Harris EJ Jr, et al. The association of elevated plasma homocyst(e)ine with progression of symptomatic peripheral arterial disease. J Vasc Surg 1991;13:128-36.
6. Robinson PN, Booms P. The molecular pathogenesis of the Marfan syndrome. Cell Mol Life Sci 2001;58:1698-707.
7. Pyeritz RE. The Marfan syndrome. Annu Rev Med 2000;51:481-510.
8. Parfitt J, Chalmers RT, Wolfe JH. Visceral aneurysms in Ehlers-Danlos syndrome: case report and review of the literature. J Vasc Surg 2000;31:1248-51.
9. Pope FM, Burrows NP. Ehlers-Danlos syndrome has varied molecular mechanisms. J Med Genet 1997;34:400-10.
10. Bergqvist D. Ehlers-Danlos type IV syndrome: a review from a vascular surgical point of view. Eur J Surg 1996;162:163-70.
11. Begelman SM, Olin JW. Fibromuscular dysplasia. Curr Opin Rheumatol 2000;12:41-7.
12. Luscher TF, Lie JT, Stanson AW, et al. Arterial fibromuscular dysplasia. Mayo Clin Proc 1987;62:931-52.
13. Gonzalez-Gay MA, Garcia-Porrua C. Epidemiology of the vasculitides. Rheum Dis Clin North Am 2001;27:729-49.
14. Johnston SL, Lock RJ, Gompels MM. Takayasu arteritis: a review. J Clin Pathol 2002;55:481-6.
15. Salvarani C, Cantini F, Boiardi L, et al. Polymyalgia rheumatica and giant-cell arteritis. N Engl J Med 2002;347:261-71.
16. Cid MC, Font C, Coll-Vinent B, et al. Large vessel vasculitides. Curr Opin Rheumatol 1998;10:18-28.
17. Langford CA, Sneller MC. New developments in the treatment of Wegener's granulomatosis, polyarteritis nodosa, microscopic polyangiitis, and Churg-Strauss syndrome. Curr Opin Rheumatol 1997;9:26-30.
18. Barron KS. Kawasaki disease: etiology, pathogenesis, and treatment. Cleve Clin J Med 2002;69 suppl 2:SII69-78.
19. Gedalia A. Kawasaki disease: an update. Curr Rheumatol Rep 2002;4:25-9.
20. Newburger JW, Burns JC. Kawasaki disease. Vasc Med 1999;4:187-202.
21. Olin JW. Thromboangiitis obliterans (Buerger's disease). N Engl J Med 2000;343:864-9.
22. Szuba A, Cooke JP. Thromboangiitis obliterans: an update on Buerger's disease. West J Med 1998;168:255-60.
23. Aqel MB, Olin JW. Thromboangiitis obliterans (Buerger's disease). Vasc Med 1997;2:61-6.
24. Lee R. Factor V Leiden: a clinical review. Am J Med Sci 2001;322:88-102.
25. Kottke-Marchant K. Genetic polymorphisms associated with venous and arterial thrombosis: an overview. Arch Pathol Lab Med 2002;126:295-304.
26. Segal JB, McNamara RL, Miller MR, et al. Anticoagulants or antiplatelet therapy for non-rheumatic atrial fibrillation and flutter. Cochrane Database Syst Rev 2001;(1):CD001938.
27. Hirsh J, Anand SS, Halperin JL, et al. Guide to anticoagulant therapy: heparin: a statement for healthcare professionals from the American Heart Association. Circulation 2001;103:2994-3018.
28. Lillicrap D. The genetics of venous and arterial thromboembolism. Curr Atheroscler Rep 2001;3:209-15.
29. Dormandy J, Heeck L, Vig S. Acute limb ischemia. Semin Vasc Surg 1999;12:148-53.
30. Fraenkel L. Raynaud''s phenomenon: epidemiology and risk factors. Curr Rheumatol Rep 2002;4:123-8.
31. Edwards JM, Porter JM. Upper extremity arterial disease: etiologic considerations and differential diagnosis. Semin Vasc Surg 1998;11:60-6.
32. Belch J. Raynaud's phenomenon. Cardiovasc Res 1997;33:25-30.
33. Belch JJ, Ho M. Pharmacotherapy of Raynaud's phenomenon. Drugs 1996;52:682-95.
34. Criqui MH, Fronek A, Klauber MR, et al. The sensitivity, specificity, and predictive value of traditional clinical evaluation of peripheral arterial disease: results from noninvasive testing in a defined population. Circulation 1985;71:516-22.
35. Criqui MH, Denenberg JO, Langer RD, et al. The epidemiology of peripheral arterial disease: importance of identifying the population at risk. Vasc Med 1997;2:221-6.
36. Price JF, Mowbray PI, Lee AJ, et al. Relationship between smoking and cardiovascular risk factors in the development of peripheral arterial disease and coronary artery disease: Edinburgh Artery Study. Eur Heart J 1999;20:344-53.
37. Kannel WB, McGee DL. Update on some epidemiologic features of intermittent claudication: the Framingham Study. J Am Geriatr Soc 1985;33:13-8.
38. Smith GD, Shipley MJ, Rose G. Intermittent claudication, heart disease risk factors, and mortality. The Whitehall Study. Circulation 1990;82:1925-31.
39. Bowlin SJ, Medalie JH, Flocke SA, et al. Epidemiology of intermittent claudication in middle-aged men. Am J Epidemiol 1994;140:418-30.
40. Meijer WT, Hoes AW, Rutgers D, et al. Peripheral arterial disease in the elderly: the Rotterdam Study. Arterioscler Thromb Vasc Biol 1998;18:185-92.
41. Cole CW, Hill GB, Farzad E, et al. Cigarette smoking and peripheral arterial occlusive disease. Surgery 1993;114:753-6; discussion 756-7.
42. Powell JT, Edwards RJ, Worrell PC, et al. Risk factors associated with the development of peripheral arterial disease in smokers: a case-control study. Atherosclerosis 1997;129:41-8.
43. Kannel WB, Shurtleff D. The Framingham Study: cigarettes and the development of intermittent claudication. Geriatrics 1973;28:61-8.
44. Newman AB, Siscovick DS, Manolio TA, et al. Ankle-arm index as a marker of atherosclerosis in the Cardiovascular Health Study. Cardiovascular Heart Study (CHS) Collaborative Research Group. Circulation 1993;88:837-45.
45. Hiatt WR, Hoag S, Hamman RF. Effect of diagnostic criteria on the prevalence of peripheral arterial disease. The San Luis Valley Diabetes Study. Circulation 1995;91:1472-9.
46. Beks PJ, Mackaay AJ, de Neeling JN, et al. Peripheral arterial disease in relation to glycaemic level in an elderly Caucasian population: the Hoorn study. Diabetologia 1995;38:86-96.
47. Katsilambros NL, Tsapogas PC, Arvanitis MP, et al. Risk factors for lower extremity arterial disease in non–insulin-dependent diabetic persons. Diabet Med 1996;13:243-6.

48. Bowers BL, Valentine RJ, Myers SI, et al. The natural history of patients with claudication with toe pressures of 40 mm Hg or less. J Vasc Surg 1993;18:506-11.
49. McDaniel MD, Cronenwett JL. Basic data related to the natural history of intermittent claudication. Ann Vasc Surg 1989;3:273-7.
50. Dormandy JA, Murray GD. The fate of the claudicant—-a prospective study of 1969 claudicants. Eur J Vasc Surg 1991; 5:131-3.
51. Most RS, Sinnock P. The epidemiology of lower extremity amputations in diabetic individuals. Diabetes Care 1983;6:87-91.
52. Murabito JM, Evans JC, Nieto K, et al. Prevalence and clinical correlates of peripheral arterial disease in the Framingham Offspring Study. Am Heart J 2002;143:961-5.
53. Ingolfsson IO, Sigurdsson G, Sigvaldason H, et al. A marked decline in the prevalence and incidence of intermittent claudication in Icelandic men 1968-1986: a strong relationship to smoking and serum cholesterol—the Reykjavik Study. J Clin Epidemiol 1994;47:1237-43.
54. Murabito JM, D'Agostino RB, Silbershatz H, et al. Intermittent claudication. A risk profile from The Framingham Heart Study. Circulation 1997;96:44-9.
55. Bainton D, Sweetnam P, Baker I, et al. Peripheral vascular disease: consequence for survival and association with risk factors in the Speedwell prospective heart disease study. Br Heart J 1994; 72:128-32.
56. Sanderson KJ, van Rij AM, Wade CR, et al. Lipid peroxidation of circulating low density lipoproteins with age, smoking and in peripheral vascular disease. Atherosclerosis 1995;118:45-51. Erratum in: Atherosclerosis 1996;121:295.
57. Horby J, Grande P, Vestergaard A, et al. High density lipoprotein cholesterol and arteriography in intermittent claudication. Eur J Vasc Surg 1989;3:333-7.
58. Bradby GV, Valente AJ, Walton KW. Serum high-density lipoproteins in peripheral vascular disease. Lancet 1978;2:1271-4.
59. Greenhalgh RM, Rosengarten DS, Mervart I, et al. Serum lipids and lipoproteins in peripheral vascular disease. Lancet 1971; 2:947-50.
60. Harris LM, Armstrong D, Browne R, et al. Premature peripheral vascular disease: clinical profile and abnormal lipid peroxidation. Cardiovasc Surg 1998;6:188-93.
61. Mowat BF, Skinner ER, Wilson HM, et al. Alterations in plasma lipids, lipoproteins and high density lipoprotein subfractions in peripheral arterial disease. Atherosclerosis 1997;131:161-6.
62. Mendelson G, Aronow WS, Ahn C. Prevalence of coronary artery disease, atherothrombotic brain infarction, and peripheral arterial disease: associated risk factors in older Hispanics in an academic hospital-based geriatrics practice. J Am Geriatr Soc 1998;46:481-3.
63. Novo S, Avellone G, Di Garbo V, et al. Prevalence of risk factors in patients with peripheral arterial disease: a clinical and epidemiological evaluation. Int Angiol 1992;11:218-29.
64. Hooi JD, Stoffers HE, Kester AD, et al. Risk factors and cardiovascular diseases associated with asymptomatic peripheral arterial occlusive disease. The Limburg PAOD Study. Peripheral Arterial Occlusive Disease. Scand J Prim Health Care 1998; 16:177-82.
65. Reunanen A, Takkunen H, Aromaa A. Prevalence of intermittent claudication and its effect on mortality. Acta Med Scand 1982; 211:249-56.
66. Boushey CJ, Beresford SA, Omenn GS, et al. A quantitative assessment of plasma homocysteine as a risk factor for vascular disease: probable benefits of increasing folic acid intakes. JAMA 1995;274:1049-57.
67. Graham IM, Daly LE, Refsum HM, et al. Plasma homocysteine as a risk factor for vascular disease. The European Concerted Action Project. JAMA 1997;277:1775-81.
68. Robinson K, Arheart K, Refsum H, et al. Low circulating folate and vitamin B6 concentrations: risk factors for stroke, peripheral vascular disease, and coronary artery disease. European COMAC Group. Circulation 1998;97:437-43. Erratum in: Circulation 1999;99:983.
69. Hoogeveen EK, Kostense PJ, Beks PJ, et al. Hyperhomocysteinemia is associated with an increased risk of cardiovascular disease, especially in non–insulin-dependent diabetes mellitus: a population-based study. Arterioscler Thromb Vasc Biol 1998;18:133-8.
70. Aronow WS, Ahn C. Association between plasma homocysteine and peripheral arterial disease in older persons. Coron Artery Dis 1998;9:49-50.
71. Currie IC, Wilson YG, Scott J, et al. Homocysteine: an independent risk factor for the failure of vascular intervention. Br J Surg 1996;83:1238-41.
72. Molgaard J, Malinow MR, Lassvik C, et al. Hyperhomocyst(e)inaemia: an independent risk factor for intermittent claudication. J Intern Med 1992;231:273-9.
73. Taylor LM Jr, Moneta GL, Sexton GJ, et al. Prospective blinded study of the relationship between plasma homocysteine and progression of symptomatic peripheral arterial disease. J Vasc Surg 1999;29:8-19; discussion 19-21.
74. Pradhan AD, Manson JE, Rossouw JE, et al. Inflammatory biomarkers, hormone replacement therapy, and incident coronary heart disease: prospective analysis from the Women's Health Initiative observational study. JAMA 2002;288:980-7.
75. Burke GL, Evans GW, Riley WA, et al. Arterial wall thickness is associated with prevalent cardiovascular disease in middle-aged adults. The Atherosclerosis Risk in Communities (ARIC) Study. Stroke 1995;26:386-91.
76. Kannel WB, Skinner JJ Jr, Schwartz MJ, et al. Intermittent claudication: incidence in the Framingham Study. Circulation 1970;41:875-83.
77. Criqui MH, Fronek A, Barrett-Connor E, et al. The prevalence of peripheral arterial disease in a defined population. Circulation 1985;71:510-5.
78. Kannel WB. The demographics of claudication and the aging of the American population. Vasc Med 1996;1:60-4.
79. Hiatt WR, Marshall JA, Baxter J, et al. Diagnostic methods for peripheral arterial disease in the San Luis Valley Diabetes Study. J Clin Epidemiol 1990;43:597-606.
80. Fowkes FG, Housley E, Cawood EH, et al. Edinburgh Artery Study: prevalence of asymptomatic and symptomatic peripheral arterial disease in the general population. Int J Epidemiol 1991;20:384-92.
81. Aronow WS. Prevalence of atherothrombotic brain infarction, coronary artery disease and peripheral arterial disease in elderly blacks, Hispanics and whites. Am J Cardiol 1992;70:1212-3.
82. Aronow WS, Ahn C. Prevalence of coexistence of coronary artery disease, peripheral arterial disease, and atherothrombotic brain infarction in men and women > or = 62 years of age. Am J Cardiol 1994;74:64-5.
83. Cofan F, Nunez I, Gilabert R, et al. Increased prevalence of carotid and femoral atherosclerosis in renal transplant recipients. Transplant Proc 2001;33:1254-6.
84. Erdoes LS, Hunter GC, Venerus BJ, et al. Prospective evaluation of peripheral vascular disease in heart transplant recipients. J Vasc Surg 1995;22:434-40; discussion 440-2.

85. Hirsch AT, Halverson SL, Treat-Jacobson D, et al. The Minnesota Regional Peripheral Arterial Disease Screening Program: toward a definition of community standards of care. Vasc Med 2001;6:87-96.
86. Hirsch AT, Criqui MH, Treat-Jacobson D, et al. Peripheral arterial disease detection, awareness, and treatment in primary care. JAMA 2001;286:1317-24.
87. Coni N, Tennison B, Troup M. Prevalence of lower extremity arterial disease among elderly people in the community. Br J Gen Pract 1992;42:149-52.
88. Gallotta G, Iazzetta N, Milan G, et al. Prevalence of peripheral arterial disease in an elderly rural population of southern Italy. Gerontology 1997;43:289-95.
89. Cheng SW, Ting AC, Lau H, et al. Epidemiology of atherosclerotic peripheral arterial occlusive disease in Hong Kong. World J Surg 1999;23:202-6.
90. Binaghi F, Fronteddu PF, Cannas F, et al. Prevalence of peripheral arterial occlusive disease and associated risk factors in a sample of southern Sardinian population. Int Angiol 1994;13:233-45.
91. Al Zahrani HA, Al Bar HM, Bahnassi A, et al. The distribution of peripheral arterial disease in a defined population of elderly high-risk Saudi patients. Int Angiol 1997;16:123-8.
92. Ness J, Aronow WS. Prevalence of coexistence of coronary artery disease, ischemic stroke, and peripheral arterial disease in older persons, mean age 80 years, in an academic hospital-based geriatrics practice. J Am Geriatr Soc 1999;47:1255-6.
93. Weitz JI, Byrne J, Clagett GP, et al. Diagnosis and treatment of chronic arterial insufficiency of the lower extremities: a critical review. Circulation 1996;94:3026-49. Erratum in: Circulation 2000;102:1074.
94. Stoffers HE, Rinkens PE, Kester AD, et al. The prevalence of asymptomatic and unrecognized peripheral arterial occlusive disease. Int J Epidemiol 1996;25:282-90.
95. Dormandy J, Mahir M, Ascady G, et al. Fate of the patient with chronic leg ischaemia: a review article. J Cardiovasc Surg (Torino) 1989;30:50-7.
96. Golomb B, Criqui MH, Budens W. Epidemiology. In: Creager MA, ed. Management of Peripheral Arterial Disease. London, UK: ReMEDICA Pub; 2000:1-18.
97. Valentine RJ, Grayburn PA, Eichhorn EJ, et al. Coronary artery disease is highly prevalent among patients with premature peripheral vascular disease. J Vasc Surg 1994;19:668-74.
98. A randomised, blinded, trial of clopidogrel versus aspirin in patients at risk of ischaemic events (CAPRIE). CAPRIE Steering Committee. Lancet 1996;348:1329-39.
99. Klop RB, Eikelboom BC, Taks AC. Screening of the internal carotid arteries in patients with peripheral vascular disease by colour-flow duplex scanning. Eur J Vasc Surg 1991;5:41-5.
100. Alexandrova NA, Gibson WC, Norris JW, et al. Carotid artery stenosis in peripheral vascular disease. J Vasc Surg 1996;23:645-9.
101. Cheng SW, Wu LL, Ting AC, et al. Screening for asymptomatic carotid stenosis in patients with peripheral vascular disease: a prospective study and risk factor analysis. Cardiovasc Surg 1999;7:303-9.
102. Long TH, Criqui MH, Vasilevskis EE, et al. The correlation between the severity of peripheral arterial disease and carotid occlusive disease. Vasc Med 1999;4:135-42.
103. Leng GC, Lee AJ, Fowkes FG, et al. Incidence, natural history and cardiovascular events in symptomatic and asymptomatic peripheral arterial disease in the general population. Int J Epidemiol 1996;25:1172-81.
104. Kornitzer M, Dramaix M, Sobolski J, et al. Ankle/arm pressure index in asymptomatic middle-aged males: an independent predictor of ten-year coronary heart disease mortality. Angiology 1995;46:211-9.
105. Newman AB, Sutton-Tyrrell K, Vogt MT, et al. Morbidity and mortality in hypertensive adults with a low ankle/arm blood pressure index. JAMA 1993;270:487-9.
106. Criqui MH, Langer RD, Fronek A, et al. Mortality over a period of 10 years in patients with peripheral arterial disease. N Engl J Med 1992;326:381-6.
107. Vogt MT, Cauley JA, Newman AB, et al. Decreased ankle/arm blood pressure index and mortality in elderly women. JAMA 1993;270:465-9.
108. Zheng ZJ, Sharrett AR, Chambless LE, et al. Associations of ankle-brachial index with clinical coronary heart disease, stroke and preclinical carotid and popliteal atherosclerosis: the Atherosclerosis Risk in Communities (ARIC) Study. Atherosclerosis 1997;131:115-25.
109. McKenna M, Wolfson S, Kuller L. The ratio of ankle and arm arterial pressure as an independent predictor of mortality. Atherosclerosis 1991;87:119-28.
110. McDermott MM, Feinglass J, Slavensky R, et al. The ankle-brachial index as a predictor of survival in patients with peripheral vascular disease. J Gen Intern Med 1994;9:445-9.
111. Howell MA, Colgan MP, Seeger RW, et al. Relationship of severity of lower limb peripheral vascular disease to mortality and morbidity: a six-year follow-up study. J Vasc Surg 1989;9:691-6; discussion 696-7.
112. Heart Protection Study Collaborative Group. MRC/BHF Heart Protection Study of cholesterol lowering with simvastatin in 20,536 high-risk individuals: a randomised placebo-controlled trial. Lancet 2002;360:7-22. Summary for patients in Curr Cardiol Rep 2002;4:486-7.
113. Yusuf S, Dagenais G, Pogue J, et al. Vitamin E supplementation and cardiovascular events in high-risk patients. The Heart Outcomes Prevention Evaluation Study Investigators. N Engl J Med 2000;342:154-60.
114. Luther M. The influence of arterial reconstructive surgery on the outcome of critical leg ischaemia. Eur J Vasc Surg 1994;8:682-9.
115. Ebskov B. Relative mortality and long term survival for the non-diabetic lower limb amputee with vascular insufficiency. Prosthet Orthot Int 1999;23:209-16.
116. Kazmers A, Perkins AJ, Jacobs LA. Major lower extremity amputation in Veterans Affairs medical centers. Ann Vasc Surg 2000;14:216-22.
117. Dormandy J, Heeck L, Vig S. The fate of patients with critical leg ischemia. Semin Vasc Surg 1999;12:142-7.
118. Muluk SC, Muluk VS, Kelley ME, et al. Outcome events in patients with claudication: a 15-year study in 2777 patients. J Vasc Surg 2001;33:251-7; discussion 257-8.
119. Rose GA. The diagnosis of ischaemic heart pain and intermittent claudication in field surveys. Bull World Health Organ 1962; 27:645-58.
120. Fowkes FG. The measurement of atherosclerotic peripheral arterial disease in epidemiological surveys. Int J Epidemiol 1988;17:248-54.
121. Leng GC, Fowkes FG. The Edinburgh Claudication Questionnaire: an improved version of the WHO/Rose Questionnaire for use in epidemiological surveys. J Clin Epidemiol 1992;45:1101-9.
122. Criqui MH, Denenberg JO, Bird CE, et al. The correlation between symptoms and non-invasive test results in patients referred for peripheral arterial disease testing. Vasc Med

1996;1:65-71.
123. McDermott MM, Ferrucci L, Simonsick EM, et al. The ankle brachial index and change in lower extremity functioning over time: the Women's Health and Aging Study. J Am Geriatr Soc 2002;50:238-46.
124. McDermott MM, Greenland P, Liu K, et al. Leg symptoms in peripheral arterial disease: associated clinical characteristics and functional impairment. JAMA 2001;286:1599-606.
125. Newman AB, Naydeck BL, Sutton-Tyrrell K, et al. The role of comorbidity in the assessment of intermittent claudication in older adults. J Clin Epidemiol 2001;54:294-300.
126. Hooi JD, Kester AD, Stoffers HE, et al. Incidence of and risk factors for asymptomatic peripheral arterial occlusive disease: a longitudinal study. Am J Epidemiol 2001;153:666-72.
127. Criqui MH, Denenberg JO. The generalized nature of atherosclerosis: how peripheral arterial disease may predict adverse events from coronary artery disease. Vasc Med 1998;3:241-5.
128. Simons PC, Algra A, Eikelboom BC, et al. Carotid artery stenosis in patients with peripheral arterial disease: the SMART study. SMART study group. J Vasc Surg 1999;30:519-25.
129. House AK, Bell R, House J, et al. Asymptomatic carotid artery stenosis associated with peripheral vascular disease: a prospective study. Cardiovasc Surg 1999;7:44-9.
129a. Grundy SM, Cleeman JI, Bairey Merz CN, et al. Implications of recent clinical trials for the National Cholesterol Education Program Adult Treatment Panel III Guidelines. Circulation 2004;110:227-39.
130. Joint National Committee on Prevention, Detection Evaluation and Treatment of High Blood Pressure. The Sixth Report of the Joint National Committee on Prevention, Detection, Evaluation, and Treatment of High Blood Pressure. Bethesda, Md: US Department of Health and Human Services, Public Health Service, National Institutes of Health, National Heart, Lung and Blood Institute; 1997. Publication No. 98-4080.
131. National Cholesterol Education Program (NCEP) Expert Panel on Detection, Evaluation and Treatment of High Blood Cholesterol in Adults. Third Report of the National Cholesterol Education Program (NCEP) Expert Panel on Detection, Evaluation, and Treatment of High Blood Cholesterol in Adults (Adult Treatment Panel III). Bethesda, Md: National Cholesterol Education Program, National Heart, Lung, and Blood Institute, National Institutes of Health; 2002. Publication No. 02-5215. Available at: http://www.nhlbi.nih.gov/guidelines/cholesterol/. Accessed July 16, 2005.
132. Stewart KJ, Hiatt WR, Regensteiner JG, et al. Exercise training for claudication. N Engl J Med 2002;347:1941-51.
133. Feinglass J, McCarthy WJ, Slavensky R, et al. Effect of lower extremity blood pressure on physical functioning in patients who have intermittent claudication. The Chicago Claudication Outcomes Research Group. J Vasc Surg 1996;24:503-11; discussion 511-2.
134. Breek JC, Hamming JF, De Vries J, et al. The impact of walking impairment, cardiovascular risk factors, and comorbidity on quality of life in patients with intermittent claudication. J Vasc Surg 2002;36:94-9.
135. Aquino R, Johnnides C, Makaroun M, et al. Natural history of claudication: long-term serial follow-up study of 1244 claudicants. J Vasc Surg 2001;34:962-70.
136. Mukherjee D, Lingam P, Chetcuti S, et al. Missed opportunities to treat atherosclerosis in patients undergoing peripheral vascular interventions: insights from the University of Michigan Peripheral Vascular Disease Quality Improvement Initiative (PVD-QI2). Circulation 2002;106:1909-12.
137. Grundy SM, Pasternak R, Greenland P, et al. AHA/ACC scientific statement: Assessment of cardiovascular risk by use of multiple-risk-factor assessment equations: a statement for healthcare professionals from the American Heart Association and the American College of Cardiology. J Am Coll Cardiol 1999; 34:1348-59.
138. Chan AW, Bhatt DL, Chew DP, et al. Early and sustained survival benefit associated with statin therapy at the time of percutaneous coronary intervention. Circulation 2002;105:691-6.
139. McGee SR, Boyko EJ. Physical examination and chronic lower-extremity ischemia: a critical review. Arch Intern Med 1998; 158:1357-64.
140. Second European Consensus Document on chronic critical leg ischemia. Circulation 1991;84(4 suppl):IV1-26.
141. Vale PR, Isner JM, Rosenfield K. Therapeutic angiogenesis in critical limb and myocardial ischemia. J Interv Cardiol 2001; 14:511-28.
142. Boersma E, Poldermans D, Bax JJ, et al. Predictors of cardiac events after major vascular surgery: role of clinical characteristics, dobutamine echocardiography, and beta-blocker therapy. JAMA 2001;285:1865-73.
143. Mercer KG, Berridge DC. Saddle embolus—the need for intensive investigation and critical evaluation: a case report. Vasc Surg 2001;35:63-5.
144. Ha JW, Chung N, Chang BC, et al. Aortic saddle embolism. Clin Cardiol 1999;22:229-30.
145. Green RM, Ouriel K, Ricotta JJ, et al. Revision of failed infrainguinal bypass graft: principles of management. Surgery 1986; 100:646-54.
146. Bartlett ST, Olinde AJ, Flinn WR, et al. The reoperative potential of infrainguinal bypass: long-term limb and patient survival. J Vasc Surg 1987;5:170-9.
147. Belkin M, Donaldson MC, Whittemore AD, et al. Observations on the use of thrombolytic agents for thrombotic occlusion of infrainguinal vein grafts. J Vasc Surg 1990;11:289-94; discussion 295-6.
148. Kinney EV, Bandyk DF, Mewissen MW, et al. Monitoring functional patency of percutaneous transluminal angioplasty. Arch Surg 1991;126:743-7.
149. Schmidtke I, Roth FJ. Repeated percutaneous transluminal catheter-treatment: primary results. Int Angiol 1985;4:87-91.
150. Brewster DC, LaSalle AJ, Robison JG, et al. Femoropopliteal graft failures: clinical consequences and success of secondary reconstructions. Arch Surg 1983;118:1043-7.
151. Moody P, de Cossart LM, Douglas HM, et al. Asymptomatic strictures in femoro-popliteal vein grafts. Eur J Vasc Surg 1989;3: 389-92.
152. Decrinis M, Doder S, Stark G, et al. A prospective evaluation of sensitivity and specificity of the ankle/brachial index in the follow-up of superficial femoral artery occlusions treated by angioplasty. Clin Investig 1994;72:592-7.
153. Sanchez LA, Suggs WD, Veith FJ, et al. Is surveillance to detect failing polytetrafluoroethylene bypasses worthwhile? Twelve-year experience with ninety-one grafts. J Vasc Surg 1993;18:981-9; discussion 989-90.
154. Buth J, Disselhoff B, Sommeling C, et al. Color-flow duplex criteria for grading stenosis in infrainguinal vein grafts. J Vasc Surg 1991;14:716-26; discussion 726-8.
155. Idu MM, Blankenstein JD, de Gier P, et al. Impact of a color-flow duplex surveillance program on infrainguinal vein graft patency: a five-year experience. J Vasc Surg 1993;17:42-52; discussion 52-3.

155a. Hirsch AT. Recognition and management of peripheral arterial disease. In: Eugene Braunwald E, Goldman L, eds. Primary Cardiology. 2nd ed. Saunders, 2003:659-71.
156. Lijmer JG, Hunink MG, van den Dungen JJ, et al. ROC analysis of noninvasive tests for peripheral arterial disease. Ultrasound Med Biol 1996;22:391-8.
157. Feigelson HS, Criqui MH, Fronek A, et al. Screening for peripheral arterial disease: the sensitivity, specificity, and predictive value of noninvasive tests in a defined population. Am J Epidemiol 1994;140:526-34.
158. Nassoura ZE, Ivatury RR, Simon RJ, et al. A reassessment of Doppler pressure indices in the detection of arterial lesions in proximity penetrating injuries of extremities: a prospective study. Am J Emerg Med 1996;14:151-6.
158a. Hiatt WR. Medical treatment of peripheral arterial disease and claudication. N Engl J Med 2001;344:1608-21.
159. Baker JD, Dix DE. Variability of Doppler ankle pressures with arterial occlusive disease: an evaluation of ankle index and brachial-ankle pressure gradient. Surgery 1981;89:134-7.
160. Carter SA. Clinical measurement of systolic pressures in limbs with arterial occlusive disease. JAMA 1969;207(10):1869-74.
161. Strandness DE Jr, Dalman RL, Panian S, et al. Effect of cilostazol in patients with intermittent claudication: a randomized, double-blind, placebo-controlled study. Vasc Endovascular Surg 2002; 36:83-91.
162. Yao ST. Haemodynamic studies in peripheral arterial disease. Br J Surg 1970;57:761-6.
163. Ouriel K, Zarins CK. Doppler ankle pressure: an evaluation of three methods of expression. Arch Surg 1982;117:1297-1300.
164. Jelnes R, Gaardsting O, Hougaard Jensen K, et al. Fate in intermittent claudication: outcome and risk factors. Br Med J (Clin Res Ed) 1986;293:1137-40.
165. McLafferty RB, Moneta GL, Taylor LM Jr, et al. Ability of ankle-brachial index to detect lower-extremity atherosclerotic disease progression. Arch Surg 1997;132:836-40; discussion 840-1.
166. Resnick HE, Lindsay RS, McDermott MM, et al. Relationship of high and low ankle brachial index to all-cause and cardiovascular disease mortality: the Strong Heart Study. Circulation 2004; 109:733-9.
167. Sikkink CJ, van Asten WN, van't Hof MA, et al. Decreased ankle/brachial indices in relation to morbidity and mortality in patients with peripheral arterial disease. Vasc Med 1997;2:169-73.
168. Mohler ER 3rd, Treat-Jacobson D, Reilly MP, et al. Utility and barriers to performance of the ankle-brachial index in primary care practice. Vasc Med 2004;9:253-60.
169. Orchard TJ, Strandness DE Jr. Assessment of peripheral vascular disease in diabetes: report and recommendations of an international workshop sponsored by the American Diabetes Association and the American Heart Association September 18-20, 1992 New Orleans, Louisiana. Circulation 1993;88:819-28.
170. American Diabetes Association. Peripheral arterial disease in people with diabetes. Diabetes Care 2003;26:3333-41.
171. American Medical Association. Current Procedural Terminology (CPT). Chicago, Ill: American Medical Association; 2001.
172. Heintz SE, Bone GE, Slaymaker EE, et al. Value of arterial pressure measurements in the proximal and distal part of the thigh in arterial occlusive disease. Surg Gynecol Obstet 1978;146:337-43.
173. Rutherford RB, Lowenstein DH, Klein MF. Combining segmental systolic pressures and plethysmography to diagnose arterial occlusive disease of the legs. Am J Surg 1979;138:211-8.
174. Carter SA. Indirect systolic pressures and pulse waves in arterial occlusive diseases of the lower extremities. Circulation 1968; 37:624-37.
175. Carter SA. Clinical measurement of systolic pressures in limbs with arterial occlusive disease. JAMA 1969;207:1869-74.
176. Carter SA, Tate RB. Value of toe pulse waves in addition to systolic pressures in the assessment of the severity of peripheral arterial disease and critical limb ischemia. J Vasc Surg 1996;24:258-65.
177. Carter SA, Tate RB. The value of toe pulse waves in determination of risks for limb amputation and death in patients with peripheral arterial disease and skin ulcers or gangrene. J Vasc Surg 2001;33:708-14.
178. Brooks B, Dean R, Patel S, et al. TBI or not TBI: that is the question. Is it better to measure toe pressure than ankle pressure in diabetic patients? Diabet Med 2001;18:528-32.
179. Ramsey DE, Manke DA, Sumner DS. Toe blood pressure: a valuable adjunct to ankle pressure measurement for assessing peripheral arterial disease. J Cardiovasc Surg (Torino) 1983;24:43-8.
180. Raines JK. The pulse volume recorder in peripheral arterial disease. In: Bernstein EF, ed. Noninvasive Diagnostic Techniques in Vascular Disease. St. Louis, Mo: Mosby; 1985:513-44.
181. Jorgensen JJ, Stranden E, Gjolberg T. Measurements of common femoral artery flow velocity in the evaluation of aortoiliac atherosclerosis: comparisons between pulsatility index, pressures measurements and pulse-volume recordings. Acta Chir Scand 1988;154:261-6.
182. Symes JF, Graham AM, Mousseau M. Doppler waveform analysis versus segmental pressure and pulse-volume recording: assessment of occlusive disease in the lower extremity. Can J Surg 1984;27:345-7.
183. Clifford PC, Morgan AP, Thomas WE, et al. Monitoring arterial surgery: a comparison of pulse volume recording and electromagnetic flowmetering in aortofemoral reconstruction. J Cardiovasc Surg (Torino) 1986;27:262-7.
184. Kaufman JL, Fitzgerald KM, Shah DM, et al. The fate of extremities with flat lower calf pulse volume recordings. J Cardiovasc Surg (Torino) 1989;30:216-9.
185. Gale SS, Scissons RP, Salles-Cunha SX, et al. Lower extremity arterial evaluation: are segmental arterial blood pressures worthwhile? J Vasc Surg 1998;27:831-8; discussion 838-9.
186. Gosling RG, Dunbar G, King DH, et al. The quantitative analysis of occlusive peripheral arterial disease by a non-intrusive ultrasonic technique. Angiology 1971;22:52-5.
187. Johnston KW, Taraschuk I. Validation of the role of pulsatility index in quantitation of the severity of peripheral arterial occlusive disease. Am J Surg 1976;131:295-7.
188. Thiele BL, Hutchinson KJ, Greene FM, et al. Pulsed Doppler waveform patters produced by smooth stenosis in the dog thoracic aorta. In: Taylor DM, Stevens AL, eds. Blood Flow, Theory and Practice. San Diego, Calif: Academic Press; 1983:85-104.
189. Bascom PA, Johnston KW, Cobbold RS, et al. Defining the limitations of measurements from Doppler spectral recordings. J Vasc Surg 1996;24:34-44; discussion 44-5.
190. Thiele BL, Bandyk DF, Zierler RE, et al. A systematic approach to the assessment of aortoiliac disease. Arch Surg 1983;118:477-81.
191. Johnston KW, Kassam M, Cobbold RS. Relationship between Doppler pulsatility index and direct femoral pressure measurements in the diagnosis of aortoiliac occlusive disease. Ultrasound Med Biol 1983;9:271-81.
192. Gardner AW, Skinner JS, Cantwell BW, et al. Progressive vs single-stage treadmill tests for evaluation of claudication. Med Sci Sports Exerc 1991;23:402-8.
193. Hiatt WR, Nawaz D, Regensteiner JG, et al. The evaluation of exercise performance in patients with peripheral vascular disease.

J Cardiopulm Rehabil 1988;8:525-32.
194. Nagle FJ, Balke B, Naughton JP. Gradational step tests for assessing work capacity. J Appl Physiol 1965;20:745-8.
195. Sumner DS, Strandness DE Jr. The relationship between calf blood flow and ankle blood pressure in patients with intermittent claudication. Surgery 1969;65:763-71.
196. Raines JK, Darling RC, Buth J, et al. Vascular laboratory criteria for the management of peripheral vascular disease of the lower extremities. Surgery 1976;79:21-9.
197. McPhail IR, Spittell PC, Weston SA, et al. Intermittent claudication: an objective office-based assessment. J Am Coll Cardiol 2001;37:1381-5.
198. Greig C, Butler F, Skelton D, et al. Treadmill walking in old age may not reproduce the real life situation. J Am Geriatr Soc 1993;41:15-8.
199. Gardner AW, Katzel LI, Sorkin JD, et al. Exercise rehabilitation improves functional outcomes and peripheral circulation in patients with intermittent claudication: a randomized controlled trial. J Am Geriatr Soc 2001;49:755-62.
200. Simonsick EM, Gardner AW, Poehlman ET. Assessment of physical function and exercise tolerance in older adults: reproducibility and comparability of five measures. Aging (Milano) 2000;12:274-80.
201. Moneta GL, Yeager RA, Lee RW, et al. Noninvasive localization of arterial occlusive disease: a comparison of segmental Doppler pressures and arterial duplex mapping. J Vasc Surg 1993;17:578-82.
202. Pinto F, Lencioni R, Napoli V, et al. Peripheral ischemic occlusive arterial disease: comparison of color Doppler sonography and angiography. J Ultrasound Med 1996;15:697-704; quiz 705-6.
203. Sacks D, Robinson ML, Marinelli DL, et al. Peripheral arterial Doppler ultrasonography: diagnostic criteria. J Ultrasound Med 1992;11:95-103.
204. de Smet AA, Ermers EJ, Kitslaar PJ. Duplex velocity characteristics of aortoiliac stenoses. J Vasc Surg 1996;23:628-36.
205. Fletcher JP, Kershaw LZ, Chan A, et al. Noninvasive imaging of the superficial femoral artery using ultrasound Duplex scanning. J Cardiovasc Surg (Torino) 1990;31:364-7.
206. Ranke C, Creutzig A, Alexander K. Duplex scanning of the peripheral arteries: correlation of the peak velocity ratio with angiographic diameter reduction. Ultrasound Med Biol 1992; 18:433-40.
207. Whelan JF, Barry MH, Moir JD. Color flow Doppler ultrasonography: comparison with peripheral arteriography for the investigation of peripheral vascular disease. J Clin Ultrasound 1992;20:369-74.
208. Davies AH, Willcox JH, Magee TR, et al. Colour duplex in assessing the infrainguinal arteries in patients with claudication. Cardiovasc Surg 1995;3:211-2.
209. Currie IC, Jones AJ, Wakeley CJ, et al. Non-invasive aortoiliac assessment. Eur J Vasc Endovasc Surg 1995;9:24-8.
210. van der Heijden FH, Legemate DA, van Leeuwen MS, et al. Value of duplex scanning in the selection of patients for percutaneous transluminal angioplasty. Eur J Vasc Surg 1993;7:71-6.
211. de Vries SO, Hunink MG, Polak JF. Summary receiver operating characteristic curves as a technique for meta-analysis of the diagnostic performance of duplex ultrasonography in peripheral arterial disease. Acad Radiol 1996;3:361-9.
212. Allard L, Cloutier G, Durand LG, et al. Limitations of ultrasonic duplex scanning for diagnosing lower limb arterial stenoses in the presence of adjacent segment disease. J Vasc Surg 1994;19:650-7.
213. Edwards JM, Coldwell DM, Goldman ML, et al. The role of duplex scanning in the selection of patients for transluminal angioplasty. J Vasc Surg 1991;13:69-74.
214. Proia RR, Walsh DB, Nelson PR, et al. Early results of infragenicular revascularization based solely on duplex arteriography. J Vasc Surg 2001;33:1165-70.
215. Ligush J Jr, Reavis SW, Preisser JS, et al. Duplex ultrasound scanning defines operative strategies for patients with limb-threatening ischemia. J Vasc Surg 1998;28:482-90; discussion 490-1.
216. Ascher E, Mazzariol F, Hingorani A, et al. The use of duplex ultrasound arterial mapping as an alternative to conventional arteriography for primary and secondary infrapopliteal bypasses. Surg Gynecol Obstet 1999;178:162-5.
217. Wain RA, Berdejo GL, Delvalle WN, et al. Can duplex scan arterial mapping replace contrast arteriography as the test of choice before infrainguinal revascularization? J Vasc Surg 1999;29:100-7; discussion 107-9.
218. Larch E, Minar E, Ahmadi R, et al. Value of color duplex sonography for evaluation of tibioperoneal arteries in patients with femoropopliteal obstruction: a prospective comparison with anterograde intraarterial digital subtraction angiography. J Vasc Surg 1997;25:629-36.
219. Mattos MA, van Bemmelen PS, Hodgson KJ, et al. Does correction of stenoses identified with color duplex scanning improve infrainguinal graft patency? J Vasc Surg 1993;17:54-64; discussion 64-6.
220. Mills JL, Harris EJ, Taylor LM Jr, et al. The importance of routine surveillance of distal bypass grafts with duplex scanning: a study of 379 reversed vein grafts. J Vasc Surg 1990;12:379-86; discussion 387-9.
221. Laborde AL, Synn AY, Worsey MJ, et al. A prospective comparison of ankle/brachial indices and color duplex imaging in surveillance of the in situ saphenous vein bypass. J Cardiovasc Surg (Torino) 1992;33:420-5.
222. Taylor PR, Tyrrell MR, Crofton M, et al. Colour flow imaging in the detection of femoro-distal graft and native artery stenosis: improved criteria. Eur J Vasc Surg 1992;6:232-6.
223. Bandyk DF, Schmitt DD, Seabrook GR, et al. Monitoring functional patency of in situ saphenous vein bypasses: the impact of a surveillance protocol and elective revision. J Vasc Surg 1989;9:286-96.
224. Golledge J, Beattie DK, Greenhalgh RM, et al. Have the results of infrainguinal bypass improved with the widespread utilisation of postoperative surveillance? Eur J Vasc Endovasc Surg 1996;11:388-92.
225. Lundell A, Lindblad B, Bergqvist D, et al. Femoropopliteal-crural graft patency is improved by an intensive surveillance program: a prospective randomized study. J Vasc Surg 1995;21:26-33; discussion 33-4.
226. Ihlberg L, Luther M, Tierala E, et al. The utility of duplex scanning in infrainguinal vein graft surveillance: results from a randomised controlled study. Eur J Vasc Endovasc Surg 1998;16:19-27.
227. Lalak NJ, Hanel KC, Hunt J, et al. Duplex scan surveillance of infrainguinal prosthetic bypass grafts. J Vasc Surg 1994;20:637-41.
228. Dunlop P, Sayers RD, Naylor AR, et al. The effect of a surveillance programme on the patency of synthetic infrainguinal bypass grafts. Eur J Vasc Endovasc Surg 1996;11:441-5.
229. Calligaro KD, Musser DJ, Chen AY, et al. Duplex ultrasonography to diagnose failing arterial prosthetic grafts. Surgery 1996;120:455-9.
230. Woodburn KR, Murtagh A, Breslin P, et al. Insonation and impedance analysis in graft surveillance. Br J Surg 1995;82:1222-5.
231. Sacks D, Robinson ML, Marinelli DL, et al. Evaluation of the peripheral arteries with duplex US after angioplasty. Radiology

1990;176:39-44.
232. Sacks D, Robinson ML, Summers TA, et al. The value of duplex sonography after peripheral artery angioplasty in predicting subacute restenosis. AJR Am J Roentgenol 1994;162:179-83.
233. Spijkerboer AM, Nass PC, de Valois JC, et al. Iliac artery stenoses after percutaneous transluminal angioplasty: follow-up with duplex ultrasonography. J Vasc Surg 1996;23:691-7.
234. Spijkerboer AM, Nass PC, de Valois JC, et al. Evaluation of femoropopliteal arteries with duplex ultrasound after angioplasty. Can we predict results at one year? Eur J Vasc Endovasc Surg 1996;12:418-23.
235. Mewissen MW, Kinney EV, Bandyk DF, et al. The role of duplex scanning versus angiography in predicting outcome after balloon angioplasty in the femoropopliteal artery. J Vasc Surg 1992; 15:860-5; discussion 865-6.
236. Miller BV, Sharp WJ, Shamma AR, et al. Surveillance for recurrent stenosis after endovascular procedures: a prospective study. Arch Surg 1991;126:867-71; discussion 871-2.
237. Vroegindeweij D, Kemper FJ, Tielbeek AV, et al. Recurrence of stenoses following balloon angioplasty and Simpson atherectomy of the femoro-popliteal segment: a randomised comparative 1-year follow-up study using colour flow duplex. Eur J Vasc Surg 1992;6:164-71.
238. Vroegindeweij D, Tielbeek AV, Buth J, et al. Patterns of recurrent disease after recanalization of femoropopliteal artery occlusions. Cardiovasc Intervent Radiol 1997;20:257-62.
239. Rubin GD, Shiau MC, Leung AN, et al. Aorta and iliac arteries: single versus multiple detector-row helical CT angiography. Radiology 2000;215:670-6.
240. Martin ML, Tay KH, Flak B, et al. Multidetector CT angiography of the aortoiliac system and lower extremities: a prospective comparison with digital subtraction angiography. AJR Am J Roentgenol 2003;180:1085-91.
241. Willmann JK, Wildermuth S, Pfammatter T, et al. Aortoiliac and renal arteries: prospective intraindividual comparison of contrast-enhanced three-dimensional MR angiography and multi-detector row CT angiography. Radiology 2003;226:798-811.
242. Willmann JK, Mayer D, Banyai M, et al. Evaluation of peripheral arterial bypass grafts with multi-detector row CT angiography: comparison with duplex US and digital subtraction angiography. Radiology 2003;229:465-74.
243. Ofer A, Nitecki SS, Linn S, et al. Multidetector CT angiography of peripheral vascular disease: a prospective comparison with intraarterial digital subtraction angiography. AJR Am J Roentgenol 2003;180:719-24.
244. Ota H, Takase K, Igarashi K, et al. MDCT compared with digital subtraction angiography for assessment of lower extremity arterial occlusive disease: importance of reviewing cross-sectional images. AJR Am J Roentgenol 2004;182:201-9.
245. Rieker O, Duber C, Schmiedt W, et al. Prospective comparison of CT angiography of the legs with intraarterial digital subtraction angiography. AJR Am J Roentgenol 1996;166:269-76.
246. Tins B, Oxtoby J, Patel S. Comparison of CT angiography with conventional arterial angiography in aortoiliac occlusive disease. Br J Radiol 2001;74:219-25.
247. Rubin GD, Schmidt AJ, Logan LJ, et al. Multi-detector row CT angiography of lower extremity arterial inflow and runoff: initial experience. Radiology 2001;221:146-58.
248. Catalano C, Fraioli F, Laghi A, et al. Infrarenal aortic and lower-extremity arterial disease: diagnostic performance of multi-detector row CT angiography. Radiology 2004;231:555-63.
249. Beregi JP, Djabbari M, Desmoucelle F, et al. Popliteal vascular disease: evaluation with spiral CT angiography. Radiology 1997;203:477-83.
250. Adriaensen ME, Kock MC, Stijnen T, et al. Peripheral arterial disease: therapeutic confidence of CT versus digital subtraction angiography and effects on additional imaging recommendations. Radiology 2004;233:385-91.
251. Rofsky NM, Adelman MA. MR angiography in the evaluation of atherosclerotic peripheral vascular disease. Radiology 2000; 214:325-38.
252. Baum RA, Rutter CM, Sunshine JH, et al. Multicenter trial to evaluate vascular magnetic resonance angiography of the lower extremity. American College of Radiology Rapid Technology Assessment Group. JAMA 1995;274:875-80.
253. Nelemans PJ, Leiner T, de Vet HC, et al. Peripheral arterial disease: meta-analysis of the diagnostic performance of MR angiography. Radiology 2000;217:105-14.
254. Khilnani NM, Winchester PA, Prince MR, et al. Peripheral vascular disease: combined 3D bolus chase and dynamic 2D MR angiography compared with x-ray angiography for treatment planning. Radiology 2002;224:63-74.
255. Visser K, Hunink MG. Peripheral arterial disease: gadolinium-enhanced MR angiography versus color-guided duplex US—a meta-analysis. Radiology 2000;216:67-77.
256. Kreitner KF, Kalden P, Neufang A, et al. Diabetes and peripheral arterial occlusive disease: prospective comparison of contrast-enhanced three-dimensional MR angiography with conventional digital subtraction angiography. AJR Am J Roentgenol 2000;174:171-9.
257. Owen RS, Carpenter JP, Baum RA, et al. Magnetic resonance imaging of angiographically occult runoff vessels in peripheral arterial occlusive disease. N Engl J Med 1992;326:1577-81.
258. Dorweiler B, Neufang A, Kreitner KF, et al. Magnetic resonance angiography unmasks reliable target vessels for pedal bypass grafting in patients with diabetes mellitus. J Vasc Surg 2002;35:766-72.
259. Hartnell G. MR angiography compared with digital subtraction angiography. AJR Am J Roentgenol 2000;175:1188-9.
260. Oser RF, Picus D, Hicks ME, et al. Accuracy of DSA in the evaluation of patency of infrapopliteal vessels. J Vasc Interv Radiol 1995;6:589-94.
261. Leyendecker JR, Elsass KD, Johnson SP, et al. The role of infrapopliteal MR angiography in patients undergoing optimal contrast angiography for chronic limb-threatening ischemia. J Vasc Interv Radiol 1998;9:545-51.
262. Maintz D, Tombach B, Juergens KU, et al. Revealing in-stent stenoses of the iliac arteries: comparison of multidetector CT with MR angiography and digital radiographic angiography in a Phantom model. AJR Am J Roentgenol 2002;179:1319-22.
263. Lee VS, Martin DJ, Krinsky GA, et al. Gadolinium-enhanced MR angiography: artifacts and pitfalls. AJR Am J Roentgenol 2000;175:197-205.
264. Sam AD 2nd, Morasch MD, Collins J, et al. Safety of gadolinium contrast angiography in patients with chronic renal insufficiency. J Vasc Surg 2003;38:313-8.
265. Hilfiker PR, Quick HH, Debatin JF. Plain and covered stent-grafts: in vitro evaluation of characteristics at three-dimensional MR angiography. Radiology 1999;211:693-7.
266. Snidow JJ, Harris VJ, Trerotola SO, et al. Interpretations and treatment decisions based on MR angiography versus conventional arteriography in symptomatic lower extremity ischemia. J Vasc Interv Radiol 1995;6:595-603.
267. Cambria RP, Kaufman JA, L'Italien GJ, et al. Magnetic resonance

angiography in the management of lower extremity arterial occlusive disease: a prospective study. J Vasc Surg 1997;25:380-9.
268. Hoch JR, Tullis MJ, Kennell TW, et al. Use of magnetic resonance angiography for the preoperative evaluation of patients with infrainguinal arterial occlusive disease. J Vasc Surg 1996;23:792-800; discussion 801.
269. Huber TS, Back MR, Ballinger RJ, et al. Utility of magnetic resonance arteriography for distal lower extremity revascularization. J Vasc Surg 1997;26:415-23; discussion 423-4.
270. Loewe C, Cejna M, Lammer J, et al. Contrast-enhanced magnetic resonance angiography in the evaluation of peripheral bypass grafts. Eur Radiol 2000;10:725-32.
271. Dorenbeck U, Seitz J, Volk M, et al. Evaluation of arterial bypass grafts of the pelvic and lower extremities with gadolinium-enhanced magnetic resonance angiography: comparison with digital subtraction angiography. Invest Radiol 2002;37:60-4.
272. Bertschinger K, Cassina PC, Debatin JF, et al. Surveillance of peripheral arterial bypass grafts with three-dimensional MR angiography: comparison with digital subtraction angiography. AJR Am J Roentgenol 2001;176:215-20.
273. Davis CP, Schopke WD, Seifert B, et al. MR angiography of patients with peripheral arterial disease before and after transluminal angioplasty. AJR Am J Roentgenol 1997;168:1027-34.
274. Bettmann MA, Heeren T, Greenfield A, et al. Adverse events with radiographic contrast agents: results of the SCVIR Contrast Agent Registry. Radiology 1997;203:611-20.
275. Waugh JR, Sacharias N. Arteriographic complications in the DSA era. Radiology 1992;182:243-6.
276. Aspelin P, Aubry P, Fransson SG, et al. Nephrotoxic effects in high-risk patients undergoing angiography. N Engl J Med 2003;348:491-9.
277. Baker CS, Wragg A, Kumar S, et al. A rapid protocol for the prevention of contrast-induced renal dysfunction: the RAPPID study. J Am Coll Cardiol 2003;41:2114-8.
278. Kay J, Chow WH, Chan TM, et al. Acetylcysteine for prevention of acute deterioration of renal function following elective coronary angiography and intervention: a randomized controlled trial. JAMA 2003;289:553-8.
279. Isenbarger DW, Kent SM, O'Malley PG. Meta-analysis of randomized clinical trials on the usefulness of acetylcysteine for prevention of contrast nephropathy. Am J Cardiol 2003;92:1454-8.
280. Stone GW, McCullough PA, Tumlin JA, et al. Fenoldopam mesylate for the prevention of contrast-induced nephropathy: a randomized controlled trial. JAMA 2003;290:2284-91.
281. Marenzi G, Marana I, Lauri G, et al. The prevention of radiocontrast-agent–induced nephropathy by hemofiltration. N Engl J Med 2003;349:1333-40.
282. Randomised trial of cholesterol lowering in 4444 patients with coronary heart disease: the Scandinavian Simvastatin Survival Study (4S) Lancet 1994;344:1383-9.
283. Sacks FM, Pfeffer MA, Moye LA, et al. The effect of pravastatin on coronary events after myocardial infarction in patients with average cholesterol levels. Cholesterol and Recurrent Events Trial investigators. N Engl J Med 1996;335:1001-9.
284. Prevention of cardiovascular events and death with pravastatin in patients with coronary heart disease and a broad range of initial cholesterol levels. The Long-Term Intervention with Pravastatin in Ischaemic Disease (LIPID) Study Group. N Engl J Med 1998;339:1349-57.
285. Rubins HB, Robins SJ, Collins D, et al. Gemfibrozil for the secondary prevention of coronary heart disease in men with low levels of high-density lipoprotein cholesterol. Veterans Affairs High-Density Lipoprotein Cholesterol Intervention Trial Study Group. N Engl J Med 1999;341:410-8.
286. Blankenhorn DH, Azen SP, Crawford DW, et al. Effects of colestipol-niacin therapy on human femoral atherosclerosis. Circulation 1991;83:438-47.
287. Duffield RG, Lewis B, Miller NE, et al. Treatment of hyperlipidaemia retards progression of symptomatic femoral atherosclerosis: a randomised controlled trial. Lancet 1983;2:639-42.
288. Buchwald H, Bourdages HR, Campos CT, et al. Impact of cholesterol reduction on peripheral arterial disease in the Program on the Surgical Control of the Hyperlipidemias (POSCH). Surgery 1996;120:672-9.
289. Pedersen TR, Kjekshus J, Pyorala K, et al. Effect of simvastatin on ischemic signs and symptoms in the Scandinavian simvastatin survival study (4S). Am J Cardiol 1998;81:333-5.
290. Mohler ER 3rd, Hiatt WR, Creager MA. Cholesterol reduction with atorvastatin improves walking distance in patients with peripheral arterial disease. Circulation 2003;108:1481-6.
291. Aronow WS, Nayak D, Woodworth S, et al. Effect of simvastatin versus placebo on treadmill exercise time until the onset of intermittent claudication in older patients with peripheral arterial disease at six months and at one year after treatment. Am J Cardiol 2003;92:711-2.
292. Mondillo S, Ballo P, Barbati R, et al. Effects of simvastatin on walking performance and symptoms of intermittent claudication in hypercholesterolemic patients with peripheral vascular disease. Am J Med 2003;114:359-64.
293. Psaty BM, Smith NL, Siscovick DS, et al. Health outcomes associated with antihypertensive therapies used as first-line agents: a systematic review and meta-analysis. JAMA 1997;277:739-45.
294. Chobanian AV, Bakris GL, Black HR, et al. The Seventh Report of the Joint National Committee on Prevention, Detection, Evaluation, and Treatment of High Blood Pressure: the JNC 7 report. JAMA 2003;289:2560-72. Erratum in: JAMA 2003;290:197.
295. Hennekens CH, Albert CM, Godfried SL, et al. Adjunctive drug therapy of acute myocardial infarction—evidence from clinical trials. N Engl J Med 1996;335:1660-7.
296. Radack K, Deck C. Beta-adrenergic blocker therapy does not worsen intermittent claudication in subjects with peripheral arterial disease: a meta-analysis of randomized controlled trials. Arch Intern Med 1991;151:1769-76.
297. Pfeffer MA, Braunwald E, Moye LA, et al. Effect of captopril on mortality and morbidity in patients with left ventricular dysfunction after myocardial infarction. Results of the survival and ventricular enlargement trial. The SAVE Investigators. N Engl J Med 1992;327:669-77.
298. Gustafsson F, Torp-Pedersen C, Kober L, et al. Effect of angiotensin converting enzyme inhibition after acute myocardial infarction in patients with arterial hypertension. TRACE Study Group, Trandolapril Cardiac Event. J Hypertens 1997;15:793-8.
299. Yusuf S, Sleight P, Pogue J, et al. Effects of an angiotensin-converting-enzyme inhibitor, ramipril, on cardiovascular events in high-risk patients. The Heart Outcomes Prevention Evaluation Study Investigators. N Engl J Med 2000;342:145-53. Errata in: N Engl J Med 2000;342:1376; N Engl J Med 2000;342:748.
300. Effect of intensive diabetes management on macrovascular events and risk factors in the Diabetes Control and Complications Trial. Am J Cardiol 1995;75:894-903.
301. Intensive blood-glucose control with sulphonylureas or insulin compared with conventional treatment and risk of complications in patients with type 2 diabetes (UKPDS 33). UK Prospective

Diabetes Study (UKPDS) Group. Lancet 1998;352:837-53. Erratum in: Lancet 1999;354:602.
302. American Diabetes Association. Standards of medical care for patients with diabetes mellitus. Diabetes Care 2003;26 suppl 1:S33-50. Erratum in: Diabetes Care 2003;26:972.
303. Donohoe ME, Fletton JA, Hook A, et al. Improving foot care for people with diabetes mellitus–-a randomized controlled trial of an integrated care approach. Diabet Med 2000;17:581-7.
304. Faulkner KW, House AK, Castleden WM. The effect of cessation of smoking on the accumulative survival rates of patients with symptomatic peripheral vascular disease. Med J Aust 1983;1:217-9.
305. Lassila R, Lepantalo M. Cigarette smoking and the outcome after lower limb arterial surgery. Acta Chir Scand 1988;154:635-40.
306. Jonason T, Bergstrom R. Cessation of smoking in patients with intermittent claudication: effects on the risk of peripheral vascular complications, myocardial infarction and mortality. Acta Med Scand 1987;221:253-60.
307. Quick CR, Cotton LT. The measured effect of stopping smoking on intermittent claudication. Br J Surg 1982;69 suppl:S24-6.
308. Gardner AW. The effect of cigarette smoking on exercise capacity in patients with intermittent claudication. Vasc Med 1996; 1:181-6.
309. Law M, Tang JL. An analysis of the effectiveness of interventions intended to help people stop smoking. Arch Intern Med 1995; 155:1933-41.
310. Jorenby DE, Leischow SJ, Nides MA, et al. A controlled trial of sustained-release bupropion, a nicotine patch, or both for smoking cessation. N Engl J Med 1999;340:685-91.
311. Lowering blood homocysteine with folic acid based supplements: meta-analysis of randomised trials. Homocysteine Lowering Trialists' Collaboration. BMJ 1998;316:894-8.
312. Omenn GS, Beresford SA, Motulsky AG. Preventing coronary heart disease: B vitamins and homocysteine. Circulation 1998;97:421-4.
313. Clarke R, Collins R. Can dietary supplements with folic acid or vitamin B6 reduce cardiovascular risk? Design of clinical trials to test the homocysteine hypothesis of vascular disease. J Cardiovasc Risk 1998;5:249-55.
314. Antithrombotic Trialists' Collaboration. Collaborative meta-analysis of randomised trials of antiplatelet therapy for prevention of death, myocardial infarction, and stroke in high risk patients. BMJ 2002;324:71-86. Erratum in: BMJ 2002;324:141.
315. Roderick PJ, Wilkes HC, Meade TW. The gastrointestinal toxicity of aspirin: an overview of randomised controlled trials. Br J Clin Pharmacol 1993;35:219-26.
316. Yusuf S, Zhao F, Mehta SR, et al. Effects of clopidogrel in addition to aspirin in patients with acute coronary syndromes without ST-segment elevation. N Engl J Med 2001;345:494-502. Errata in: N Engl J Med 2001;345:1716; N Engl J Med 2001;345:1506.
317. Collaborative overview of randomised trials of antiplatelet therapy–-I: prevention of death, myocardial infarction, and stroke by prolonged antiplatelet therapy in various categories of patients. Antiplatelet Trialists' Collaboration. BMJ 1994;308:81-106. Erratum in: BMJ 1994;308:1540.
318. Girolami B, Bernardi E, Prins MH, et al. Antithrombotic drugs in the primary medical management of intermittent claudication: a meta-analysis. Thromb Haemost 1999;81:715-22.
319. Anand SS, Yusuf S. Oral anticoagulant therapy in patients with coronary artery disease: a meta-analysis. JAMA 1999;282:2058-67. Erratum in: JAMA 2000;284:45.
320. Anand SS, Yusuf S. Oral anticoagulants in patients with coronary artery disease. J Am Coll Cardiol 2003;41(4 suppl S):62S-69S. 3
321. Efficacy of oral anticoagulants compared with aspirin after infrainguinal bypass surgery (The Dutch Bypass Oral Anticoagulants or Aspirin Study): a randomised trial. Lancet 2000;355:346-51. Erratum in: Lancet 2000;355:1104.
322. Regensteiner JG. Exercise in the treatment of claudication: assessment and treatment of functional impairment. Vasc Med 1997;2:238-42.
323. Gardner AW, Poehlman ET. Exercise rehabilitation programs for the treatment of claudication pain: a meta-analysis. JAMA 1995;274:975-80.
324. Hiatt WR, Wolfel EE, Meier RH, et al. Superiority of treadmill walking exercise versus strength training for patients with peripheral arterial disease: implications for the mechanism of the training response. Circulation 1994;90:1866-74.
325. Regensteiner JG, Meyer TJ, Krupski WC, et al. Hospital vs home-based exercise rehabilitation for patients with peripheral arterial occlusive disease. Angiology 1997;48:291-300.
326. Hiatt WR, Regensteiner JG, Hargarten ME, et al. Benefit of exercise conditioning for patients with peripheral arterial disease. Circulation 1990;81:602-9.
327. Lundgren F, Dahllof AG, Schersten T, et al. Muscle enzyme adaptation in patients with peripheral arterial insufficiency: spontaneous adaptation, effect of different treatments and consequences on walking performance. Clin Sci (Lond) 1989;77:485-93.
328. Hirsch AT, Ekers MA. A comprehensive vascular medical therapeutic approach to peripheral arterial disease: the foundation of effective vascular rehabilitation. In: Fahey VA, ed. Vascular Nursing. 3rd ed. Philadelphia, Pa: WB Saunders; 1999:188-211.
329. Leng GC, Fowler B, Ernst E. Exercise for intermittent claudication. Cochrane Database Syst Rev 2000;CD000990.
330. Larsen OA, Lassen NA. Effect of daily muscular exercise in patients with intermittent claudication. Lancet 1966;2:1093-6.
331. Holm J, Dahllof AG, Bjorntorp P, et al. Enzyme studies in muscles of patients with intermittent claudication: effect of training. Scand J Clin Lab Invest Suppl 1973;128:201-5.
332. Dahllof AG, Bjorntorp P, Holm J, et al. Metabolic activity of skeletal muscle in patients with peripheral arterial insufficiency. Eur J Clin Invest 1974;4:9-15.
333. Dahllof AG, Holm J, Schersten T, et al. Peripheral arterial insufficiency, effect of physical training on walking tolerance, calf blood flow, and blood flow resistance. Scand J Rehabil Med 1976;8:19-26.
334. Creasy TS, McMillan PJ, Fletcher EW, et al. Is percutaneous transluminal angioplasty better than exercise for claudication? Preliminary results from a prospective randomised trial. Eur J Vasc Surg 1990;4:135-40.
335. Mannarino E, Pasqualini L, Innocente S, et al. Physical training and antiplatelet treatment in stage II peripheral arterial occlusive disease: alone or combined? Angiology 1991;42:513-21.
336. Patterson RB, Pinto B, Marcus B, et al. Value of a supervised exercise program for the therapy of arterial claudication. J Vasc Surg 1997;25:312-8; discussion 318-9.
337. Dawson DL, Cutler BS, Meissner MH, et al. Cilostazol has beneficial effects in treatment of intermittent claudication: results from a multicenter, randomized, prospective, double-blind trial. Circulation 1998;98:678-86.
338. Money SR, Herd JA, Isaacsohn JL, et al. Effect of cilostazol on walking distances in patients with intermittent claudication caused by peripheral vascular disease. J Vasc Surg 1998;27:267-74; discussion 274-5.
339. Clifford PC, Davies PW, Hayne JA, et al. Intermittent claudica-

tion: is a supervised exercise class worth while? Br Med J 1980; 280:1503-5.
340. Regensteiner JG, Steiner JF, Hiatt WR. Exercise training improves functional status in patients with peripheral arterial disease. J Vasc Surg 1996;23:104-15.
341. Expert Panel on Detection, Evaluation, and Treatment of High Blood Cholesterol in Adults. Executive Summary of the Third Report of the National Cholesterol Education Program (NCEP) Expert Panel on Detection, Evaluation, and Treatment of High Blood Cholesterol in Adults (Adult Treatment Panel III). JAMA 2001;285:2486-97.
342. The sixth report of the Joint National Committee on prevention, detection, evaluation, and treatment of high blood pressure. Arch Intern Med 1997;157:2413-46. Erratum in Arch Intern Med 1998;158:573.
343. Gibellini R, Fanello M, Bardile AF, et al. Exercise training in intermittent claudication. Int Angiol 2000;19:8-13.
344. Gardner AW, Katzel LI, Sorkin JD, et al. Effects of long-term exercise rehabilitation on claudication distances in patients with peripheral arterial disease: a randomized controlled trial. J Cardiopulm Rehabil 2002;22:192-8.
345. ACSM's Resource Manual for Guidelines for Exercise Testing and Prescription. 4th ed. Roitman JL, ed. Baltimore, Md: Lippincott, Williams, and Wilkins; 2001.
346. Ryan AS, Katzel LI, Gardner AW. Determinants of peak V(O2) in peripheral arterial occlusive disease patients. J Gerontol A Biol Sci Med Sci 2000;55:B302-6.
347. Pollock ML, Franklin BA, Balady GJ, et al. AHA Science Advisory. Resistance exercise in individuals with and without cardiovascular disease: benefits, rationale, safety, and prescription: an advisory from the Committee on Exercise, Rehabilitation, and Prevention, Council on Clinical Cardiology, American Heart Association; Position paper endorsed by the American College of Sports Medicine. Circulation 2000;101:828-33.
348. Coffman JD. Intermittent claudication—be conservative. N Engl J Med 1991;325:577-8.
349. Radack K, Wyderski RJ. Conservative management of intermittent claudication. Ann Intern Med 1990;113:135-46.
350. Savage P, Ricci MA, Lynn M, et al. Effects of home versus supervised exercise for patients with intermittent claudication. J Cardiopulm Rehabil 2001;21:152-7.
351. Degischer S, Labs KH, Hochstrasser J, et al. Physical training for intermittent claudication: a comparison of structured rehabilitation versus home-based training. Vasc Med 2002;7:109-15.
352. Perkins JM, Collin J, Creasy TS, et al. Exercise training versus angioplasty for stable claudication: long and medium term results of a prospective, randomised trial. Eur J Vasc Endovasc Surg 1996;11:409-13.
353. Chong PF, Golledge J, Greenhalgh RM, et al. Exercise therapy or angioplasty? A summation analysis. Eur J Vasc Endovasc Surg 2000;20:4-12.
354. Gelin J, Jivegard L, Taft C, et al. Treatment efficacy of intermittent claudication by surgical intervention, supervised physical exercise training compared to no treatment in unselected randomised patients I: one year results of functional and physiological improvements. Eur J Vasc Endovasc Surg 2001;22:107-13.
355. Lundgren F, Dahllof AG, Lundholm K, et al. Intermittent claudication–-surgical reconstruction or physical training? A prospective randomized trial of treatment efficiency. Ann Surg 1989;209:346-55.
356. Priebe M, Davidoff G, Lampman RM. Exercise testing and training in patients with peripheral vascular disease and lower extremity amputation. West J Med 1991;154:598-601.
357. Walker RD, Nawaz S, Wilkinson CH, et al. Influence of upper- and lower-limb exercise training on cardiovascular function and walking distances in patients with intermittent claudication. J Vasc Surg 2000;31:662-9.
358. Belcaro G, Nicolaides AN, Agus G, et al. PGE(1) treatment of severe intermittent claudication (short-term versus long-term, associated with exercise)–-efficacy and costs in a 20-week, randomized trial. Angiology 2000;51(8 pt 2):S15-26.
359. Diehm C, Kuhn A, Strauss R, et al. Effects of regular physical training in a supervised class and additional intravenous prostaglandin E1 and naftidrofuryl infusion therapy in patients with intermittent claudication–-a controlled study. Vasa Suppl 1989;28:26-30.
360. Girolami B, Bernardi E, Prins MH, et al. Treatment of intermittent claudication with physical training, smoking cessation, pentoxifylline, or nafronyl: a meta-analysis. Arch Intern Med 1999;159: 337-45.
361. Hall JA, Barnard J. The effects of an intensive 26-day program of diet and exercise on patients with peripheral vascular disease. J Cardiac Rehabil 1982;2:569-74.
362. Rosfors S, Bygdeman S, Arnetz BB, et al. Longterm neuroendocrine and metabolic effects of physical training in intermittent claudication. Scand J Rehabil Med 1989;21:7-11.
362a. Ruderman N, Devlin JT, Schneider S, Kriska A. Handbook of Exercise in Diabetes. Alexandria, VA: American Diabetes Association, 2002.
362b. ACSM's Guidelines for Exercise Testing and Prescription. In: Franklin BA, ed. Baltimore, MD: Lippincott, Williams, & Wilkins, 2000.
362c. Guidelines for Cardiac Rehabilitation and Secondary Prevention/American Association of Cardiovascular and Pulmonary Rehabilitation. Champaign, IL: Human Kinetics, 1999.
362d. Stewart KJ, Hiatt WR, Regensteiner JG, Hirsch AT. Medical progress: exercise training for claudication. N Engl J Med 2002;347:1941-51.
363. Igawa T, Tani T, Chijiwa T, et al. Potentiation of anti-platelet aggregating activity of cilostazol with vascular endothelial cells. Thromb Res 1990;57:617-23.
364. Woo SK, Kang WK, Kwon KI. Pharmacokinetic and pharmacodynamic modeling of the antiplatelet and cardiovascular effects of cilostazol in healthy humans. Clin Pharmacol Ther 2002;71:246-52.
365. Elam MB, Heckman J, Crouse JR, et al. Effect of the novel antiplatelet agent cilostazol on plasma lipoproteins in patients with intermittent claudication. Arterioscler Thromb Vasc Biol 1998;18:1942-7.
366. Otsuki M, Saito H, Xu X, et al. Cilostazol represses vascular cell adhesion molecule-1 gene transcription via inhibiting NF-kappaB binding to its recognition sequence. Atherosclerosis 2001; 158:121-8.
367. Tsuchikane E, Fukuhara A, Kobayashi T, et al. Impact of cilostazol on restenosis after percutaneous coronary balloon angioplasty. Circulation 1999;100:21-6.
368. Takahashi S, Oida K, Fujiwara R, et al. Effect of cilostazol, a cyclic AMP phosphodiesterase inhibitor, on the proliferation of rat aortic smooth muscle cells in culture. J Cardiovasc Pharmacol1992;20:900-6.
369. Beebe HG, Dawson DL, Cutler BS, et al. A new pharmacological treatment for intermittent claudication: results of a randomized, multicenter trial. Arch Intern Med 1999;159:2041-50.
370. Dawson DL, Cutler BS, Hiatt WR, et al. A comparison of cilosta-

zol and pentoxifylline for treating intermittent claudication. Am J Med 2000;109:523-30.
371. Mohler ER 3rd, Beebe HG, Salles-Cuhna S, et al. Effects of cilostazol on resting ankle pressures and exercise-induced ischemia in patients with intermittent claudication. Vasc Med 2001;6:151-6.
372. Regensteiner JG, Ware JE Jr, McCarthy WJ, et al. Effect of cilostazol on treadmill walking, community-based walking ability, and health-related quality of life in patients with intermittent claudication due to peripheral arterial disease: meta-analysis of six randomized controlled trials. J Am Geriatr Soc 2002;50:1939-46.
373. Packer M, Carver JR, Rodeheffer RJ, et al. Effect of oral milrinone on mortality in severe chronic heart failure. The PROMISE Study Research Group. N Engl J Med 1991;325:1468-75.
374. Cohn JN, Goldstein SO, Greenberg BH, et al. A dose-dependent increase in mortality with vesnarinone among patients with severe heart failure. Vesnarinone Trial Investigators. N Engl J Med 1998; 339:1810-6.
375. Strano A, Davi G, Avellone G, et al. Double-blind, crossover study of the clinical efficacy and the hemorheological effects of pentoxifylline in patients with occlusive arterial disease of the lower limbs. Angiology 1984;35:459-66.
376. Rao KM, Simel DL, Cohen HJ, et al. Effects of pentoxifylline administration on blood viscosity and leukocyte cytoskeletal function in patients with intermittent claudication. J Lab Clin Med 1990;115:738-44.
377. Schratzberger P, Dunzendorfer S, Reinisch N, et al. Mediator-dependent effects of pentoxifylline on endothelium for transmigration of neutrophils. Immunopharmacology 1999;41:65-75.
378. Dawson DL, Zheng Q, Worthy SA, et al. Failure of pentoxifylline or cilostazol to improve blood and plasma viscosity, fibrinogen, and erythrocyte deformability in claudication. Angiology 2002;53:509-20.
379. Franzini E, Sellak H, Babin-Chevaye C, et al. Effects of pentoxifylline on the adherence of polymorphonuclear neutrophils to oxidant-stimulated human endothelial cells: involvement of cyclic AMP. J Cardiovasc Pharmacol 1995;25 suppl 2:S92-5.
380. Hood SC, Moher D, Barber GG. Management of intermittent claudication with pentoxifylline: meta-analysis of randomized controlled trials. CMAJ 1996;155:1053-9.
381. Lindgarde F, Jelnes R, Bjorkman H, et al. Conservative drug treatment in patients with moderately severe chronic occlusive peripheral arterial disease. Scandinavian Study Group. Circulation 1989; 80:1549-56.
382. Porter JM, Cutler BS, Lee BY, et al. Pentoxifylline efficacy in the treatment of intermittent claudication: multicenter controlled double-blind trial with objective assessment of chronic occlusive arterial disease patients. Am Heart J 1982;104:66-72.
383. Lindgarde F, Labs KH, Rossner M. The pentoxifylline experience: exercise testing reconsidered. Vasc Med 1996;1:145-54.
384. Belch JJ, Bell PR, Creissen D, et al. Randomized, double-blind, placebo-controlled study evaluating the efficacy and safety of AS-013, a prostaglandin E1 prodrug, in patients with intermittent claudication. Circulation 1997;95:2298-302.
385. Diehm C, Balzer K, Bisler H, et al. Efficacy of a new prostaglandin E1 regimen in outpatients with severe intermittent claudication: results of a multicenter placebo-controlled double-blind trial. J Vasc Surg 1997;25:537-44.
386. Boger RH, Bode-Boger SM, Thiele W, et al. Restoring vascular nitric oxide formation by L-arginine improves the symptoms of intermittent claudication in patients with peripheral arterial occlusive disease. J Am Coll Cardiol 1998;32:1336-44.
387. Mangiafico RA, Messina R, Attina T, et al. Impact of a 4-week treatment with prostaglandin E1 on health-related quality of life of patients with intermittent claudication. Angiology 2000; 51:441-9.
388. Lievre M, Morand S, Besse B, et al. Oral Beraprost sodium, a prostaglandin I(2) analogue, for intermittent claudication: a double-blind, randomized, multicenter controlled trial. Beraprost et Claudication Intermittente (BERCI) Research Group. Circulation 2000;102:426-31.
389. Mohler ER 3rd, Hiatt WR, Olin JW, et al. Treatment of intermittent claudication with beraprost sodium, an orally active prostaglandin I2 analogue: a double-blinded, randomized, controlled trial. J Am Coll Cardiol 2003;41:1679-86.
390. Yang HT, Deschenes MR, Ogilvie RW, et al. Basic fibroblast growth factor increases collateral blood flow in rats with femoral arterial ligation. Circ Res 1996;79:62-9.
391. Takeshita S, Zheng LP, Brogi E, et al. Therapeutic angiogenesis: a single intraarterial bolus of vascular endothelial growth factor augments revascularization in a rabbit ischemic hind limb model. J Clin Invest 1994;93:662-70.
392. Tsurumi Y, Takeshita S, Chen D, et al. Direct intramuscular gene transfer of naked DNA encoding vascular endothelial growth factor augments collateral development and tissue perfusion. Circulation 1996;94:3281-90.
393. Ohara N, Koyama H, Miyata T, et al. Adenovirus-mediated ex vivo gene transfer of basic fibroblast growth factor promotes collateral development in a rabbit model of hind limb ischemia. Gene Ther 2001;8:837-45.
394. Lazarous DF, Unger EF, Epstein SE, et al. Basic fibroblast growth factor in patients with intermittent claudication: results of a phase I trial. J Am Coll Cardiol 2000;36:1239-44.
395. Lederman RJ, Mendelsohn FO, Anderson RD, et al. Therapeutic angiogenesis with recombinant fibroblast growth factor-2 for intermittent claudication (the TRAFFIC study): a randomised trial. Lancet 2002;359:2053-8.
396. Cooper LT Jr, Hiatt WR, Creager MA, et al. Proteinuria in a placebo-controlled study of basic fibroblast growth factor for intermittent claudication. Vasc Med 2001;6:235-9.
397. Rajagopalan S, Trachtenberg J, Mohler E, et al. Phase I study of direct administration of a replication deficient adenovirus vector containing the vascular endothelial growth factor cDNA (CI-1023) to patients with claudication. Am J Cardiol 2002;90:512-6.
398. Rajagopalan S, Mohler ER 3rd, Lederman RJ, et al. Regional angiogenesis with vascular endothelial growth factor in peripheral arterial disease: a phase II randomized, double-blind, controlled study of adenoviral delivery of vascular endothelial growth factor 121 in patients with disabling intermittent claudication. Circulation 2003;108:1933-8.
399. Cooke JP, Creager MA. Hypercholesterolemia, atherosclerosis, and the NO synthase pathway. In: Vallance PJ, Webb DJ, eds. Vascular Endothelium in Human Physiology and Pathophysiology. Amsterdam, the Netherlands: Harwood Academic Publishers, 2000:147-70.
400. Creager MA, Gallagher SJ, Girerd XJ, et al. L-arginine improves endothelium-dependent vasodilation in hypercholesterolemic humans. J Clin Invest 1992;90:1248-53.
401. Maxwell AJ, Anderson BE, Cooke JP. Nutritional therapy for peripheral arterial disease: a double-blind, placebo-controlled, randomized trial of HeartBar. Vasc Med 2000;5:11-9.
402. Brevetti G, Chiariello M, Ferulano G, et al. Increases in walking distance in patients with peripheral vascular disease treated with

L-carnitine: a double-blind, cross-over study. Circulation 1988; 77:767-73.
403. Brevetti G, Diehm C, Lambert D. European multicenter study on propionyl-L-carnitine in intermittent claudication. J Am Coll Cardiol 1999;34:1618-24.
404. Brevetti G, Perna S, Sabba C, et al. Propionyl-L-carnitine in intermittent claudication: double-blind, placebo-controlled, dose titration, multicenter study. J Am Coll Cardiol 1995;26:1411-6.
405. Hiatt WR, Regensteiner JG, Creager MA, et al. Propionyl-L-carnitine improves exercise performance and functional status in patients with claudication. Am J Med 2001;110:616-22.
406. Pittler MH, Ernst E. Ginkgo biloba extract for the treatment of intermittent claudication: a meta-analysis of randomized trials. Am J Med 2000;108:276-81.
407. Kleijnen J, Mackerras D. Vitamin E for intermittent claudication. Cochrane Database Syst Rev 2000;(2):CD000987.
408. Tornwall ME, Virtamo J, Haukka JK, et al. The effect of alpha-tocopherol and beta-carotene supplementation on symptoms and progression of intermittent claudication in a controlled trial. Atherosclerosis 1999;147:193-7.
409. Ernst E. Chelation therapy for peripheral arterial occlusive disease: a systematic review. Circulation 1997;96:1031-3.
410. Villarruz MV, Dans A, Tan F. Chelation therapy for atherosclerotic cardiovascular disease. Cochrane Database Syst Rev 2002; CD002785.
411. Olszewer E, Sabbag FC, Carter JP. A pilot double-blind study of sodium-magnesium EDTA in peripheral vascular disease. J Natl Med Assoc 1990;82:173-7.
412. Sloth-Nielsen J, Guldager B, Mouritzen C, et al. Arteriographic findings in EDTA chelation therapy on peripheral arteriosclerosis. Surg Gynecol Obstet 1991;162:122-5.
413. van Rij AM, Solomon C, Packer SG, et al. Chelation therapy for intermittent claudication: a double-blind, randomized, controlled trial. Circulation 1994;90:1194-9.
414. Guldager B, Jelnes R, Jorgensen SJ, et al. EDTA treatment of intermittent claudication—a double-blind, placebo-controlled study. J Intern Med 1992;231:261-7.
415. Johnston KW, Rae M, Hogg-Johnston SA, et al. 5-year results of a prospective study of percutaneous transluminal angioplasty. Ann Surg 1987;206:403-13.
416. Lofberg AM, Karacagil S, Ljungman C, et al. Percutaneous transluminal angioplasty of the femoropopliteal arteries in limbs with chronic critical lower limb ischemia. J Vasc Surg 2001;34:114-21.
417. Jamsen T, Manninen H, Tulla H, et al. The final outcome of primary infrainguinal percutaneous transluminal angioplasty in 100 consecutive patients with chronic critical limb ischemia. J Vasc Interv Radiol 2002;13:455-63.
418. Powell RJ, Fillinger M, Walsh DB, et al. Predicting outcome of angioplasty and selective stenting of multisegment iliac artery occlusive disease. J Vasc Surg 2000;32:564-9.
419. Laborde JC, Palmaz JC, Rivera FJ, et al. Influence of anatomic distribution of atherosclerosis on the outcome of revascularization with iliac stent placement. J Vasc Interv Radiol 1995;6:513-21.
420. Capek P, McLean GK, Berkowitz HD. Femoropopliteal angioplasty: factors influencing long-term success. Circulation 1991; 83(2 suppl):I70-80.
421. Stokes KR, Strunk HM, Campbell DR, et al. Five-year results of iliac and femoropopliteal angioplasty in diabetic patients. Radiology 1990;174(3 pt 2):977-82.
422. Johnston KW. Iliac arteries: reanalysis of results of balloon angioplasty. Radiology 1993;186:207-12.
423. Clark TW, Groffsky JL, Soulen MC. Predictors of long-term patency after femoropopliteal angioplasty: results from the STAR registry. J Vasc Interv Radiol 2001;12:923-33.
424. Beck AH, Muhe A, Ostheim W, et al. Long-term results of percutaneous transluminal angioplasty: a study of 4750 dilatations and local lyses. Eur J Vasc Surg 1989;3:245-52.
425. Palmaz JC, Laborde JC, Rivera FJ, et al. Stenting of the iliac arteries with the Palmaz stent: experience from a multicenter trial. Cardiovasc Intervent Radiol 1992;15:291-7.
426. Soder HK, Manninen HI, Jaakkola P, et al. Prospective trial of infrapopliteal artery balloon angioplasty for critical limb ischemia: angiographic and clinical results. J Vasc Interv Radiol 2000;11:1021-31.
427. Sapoval MR, Chatellier G, Long AL, et al. Self-expandable stents for the treatment of iliac artery obstructive lesions: long-term success and prognostic factors. AJR Am J Roentgenol 1996;166:1173-9.
428. Bakal CW, Sprayregen S, Scheinbaum K, et al. Percutaneous transluminal angioplasty of the infrapopliteal arteries: results in 53 patients. AJR Am J Roentgenol 1990;154:171-4.
429. Brown KT, Moore ED, Getrajdman GI, et al. Infrapopliteal angioplasty: long-term follow-up. J Vasc Interv Radiol 1993;4:139-44.
430. Bull PG, Mendel H, Hold M, et al. Distal popliteal and tibioperoneal transluminal angioplasty: long-term follow-up. J Vasc Interv Radiol 1992;3:45-53.
431. Timaran CH, Stevens SL, Freeman MB, et al. External iliac and common iliac artery angioplasty and stenting in men and women. J Vasc Surg 2001;34:440-6.
432. Timaran CH, Stevens SL, Grandas OH, et al. Influence of hormone replacement therapy on the outcome of iliac angioplasty and stenting. J Vasc Surg 2001;33(2 suppl):S85-92.
433. Avino AJ, Bandyk DF, Gonsalves AJ, et al. Surgical and endovascular intervention for infrainguinal vein graft stenosis. J Vasc Surg 1999;29:60-70; discussion 70-1.
434. Whittemore AD, Donaldson MC, Polak JF, et al. Limitations of balloon angioplasty for vein graft stenosis. J Vasc Surg 1991; 14:340-5.
435. Goh RH, Sniderman KW, Kalman PG. Long-term follow-up of management of failing in situ saphenous vein bypass grafts using endovascular intervention techniques. J Vasc Interv Radiol 2000;11:705-12.
436. Bosch JL, Hunink MG. Meta-analysis of the results of percutaneous transluminal angioplasty and stent placement for aortoiliac occlusive disease. Radiology 1997;204:87-96. Erratum in: Radiology 1997;205:584.
437. Hunink MG, Wong JB, Donaldson MC, et al. Patency results of percutaneous and surgical revascularization for femoropopliteal arterial disease. Med Decis Making 1994;14:71-81.
438. Hunink MG, Wong JB, Donaldson MC, et al. Revascularization for femoropopliteal disease: a decision and cost-effectiveness analysis. JAMA 1995;274:165-71.
438a. Kandarpa K, Becker, BJ, Hunink, M, et al. J Vasc Interv Radiol 2001;12:683-95.
439. Udoff EJ, Barth KH, Harrington DP, et al. Hemodynamic significance of iliac artery stenosis: pressure measurements during angiography. Radiology 1979;132:289-93.
440. Tetteroo E, van Engelen AD, Spithoven JH, et al. Stent placement after iliac angioplasty: comparison of hemodynamic and angiographic criteria. Dutch Iliac Stent Trial Study Group. Radiology 1996;201:155-9.
441. Kinney TB, Rose SC. Intraarterial pressure measurements during angiographic evaluation of peripheral vascular disease: techniques, interpretation, applications, and limitations. AJR Am J

Roentgenol 1996;166:277-84.
442. Bonn J. Percutaneous vascular intervention: value of hemodynamic measurements. Radiology 1996;201:18-20.
443. Whyman MR, Fowkes FG, Kerracher EM, et al. Randomised controlled trial of percutaneous transluminal angioplasty for intermittent claudication. Eur J Vasc Endovasc Surg 1996;12:167-72.
444. Whyman MR, Fowkes FG, Kerracher EM, et al. Is intermittent claudication improved by percutaneous transluminal angioplasty? A randomized controlled trial. J Vasc Surg 1997;26:551-7.
445. Feinglass J, McCarthy WJ, Slavensky R, et al. Functional status and walking ability after lower extremity bypass grafting or angioplasty for intermittent claudication: results from a prospective outcomes study. J Vasc Surg 2000;31(1 pt 1):93-103.
446. Holm J, Arfvidsson B, Jivegard L, et al. Chronic lower limb ischaemia. A prospective randomised controlled study comparing the 1-year results of vascular surgery and percutaneous transluminal angioplasty (PTA). Eur J Vasc Surg 1991;5:517-22.
447. Wolf GL, Wilson SE, Cross AP, et al. Surgery or balloon angioplasty for peripheral vascular disease: a randomized clinical trial. Principal investigators and their Associates of Veterans Administration Cooperative Study Number 199. J Vasc Interv Radiol 1993;4:639-48.
448. Wilson SE, Wolf GL, Cross AP. Percutaneous transluminal angioplasty versus operation for peripheral arteriosclerosis: report of a prospective randomized trial in a selected group of patients. J Vasc Surg 1989;9:1-9.
449. Gray BH, Sullivan TM, Childs MB, et al. High incidence of restenosis/reocclusion of stents in the percutaneous treatment of long-segment superficial femoral artery disease after suboptimal angioplasty. J Vasc Surg 1997;25:74-83.
450. de Vries SO, Visser K, de Vries JA, et al. Intermittent claudication: cost-effectiveness of revascularization versus exercise therapy. Radiology 2002;222:25-36.
451. Treesak C, Kasemsup V, Treat-Jacobson D, et al. Cost-effectiveness of exercise training to improve claudication symptoms in patients with peripheral arterial disease. Vasc Med 2004;9:279-85.
452. Tetteroo E, van der Graaf Y, Bosch JL, et al. Randomised comparison of primary stent placement versus primary angioplasty followed by selective stent placement in patients with iliac-artery occlusive disease. Dutch Iliac Stent Trial Study Group. Lancet 1998;351:1153-9.
453. Richter GM, Roeren T, Noeldge G, et al. [Initial long-term results of a randomized 5-year study: iliac stent implantation versus PTA] Vasa Suppl 1992;35:192-3.
454. Bosch JL, Tetteroo E, Mali WP, et al. Iliac arterial occlusive disease: cost-effectiveness analysis of stent placement versus percutaneous transluminal angioplasty. Dutch Iliac Stent Trial Study Group. Radiology 1998;208:641-8.
455. Bosch JL, Haaring C, Meyerovitz MF, et al. Cost-effectiveness of percutaneous treatment of iliac artery occlusive disease in the United States. AJR Am J Roentgenol 2000;175:517-21.
456. Muradin GS, Bosch JL, Stijnen T, et al. Balloon dilation and stent implantation for treatment of femoropopliteal arterial disease: meta-analysis. Radiology 2001;221:137-45.
457. Cejna M, Thurnher S, Illiasch H, et al. PTA versus Palmaz stent placement in femoropopliteal artery obstructions: a multicenter prospective randomized study. J Vasc Interv Radiol 2001;12:23-31.
458. Grimm J, Muller-Hulsbeck S, Jahnke T, et al. Randomized study to compare PTA alone versus PTA with Palmaz stent placement for femoropopliteal lesions. J Vasc Interv Radiol 2001;12:935-42.
459. Vroegindeweij D, Vos LD, Tielbeek AV, et al. Balloon angioplasty combined with primary stenting versus balloon angioplasty alone in femoropopliteal obstructions: a comparative randomized study. Cardiovasc Intervent Radiol 1997;20:420-5.
460. Zdanowski Z, Albrechtsson U, Lundin A, et al. Percutaneous transluminal angioplasty with or without stenting for femoropopliteal occlusions? A randomized controlled study. Int Angiol 1999;18:251-5.
461. Schillinger M, Mlekusch W, Haumer M, et al. Angioplasty and elective stenting of de novo versus recurrent femoropopliteal lesions: 1-year follow-up. J Endovasc Ther 2003;10:288-97.
462. Vroegindeweij D, Tielbeek AV, Buth J, et al. Directional atherectomy versus balloon angioplasty in segmental femoropopliteal artery disease: two-year follow-up with color-flow duplex scanning. J Vasc Surg 1995;21:255-68; discussion 268-9.
463. Nakamura S, Conroy RM, Gordon IL, et al. A randomized trial of transcutaneous extraction atherectomy in femoral arteries: intravascular ultrasound observations. J Clin Ultrasound 1995;23:461-71.
464. Jahnke T, Link J, Muller-Hulsbeck S, et al. Treatment of infrapopliteal occlusive disease by high-speed rotational atherectomy: initial and mid-term results. J Vasc Interv Radiol 2001;12:221-6.
465. Belli AM, Cumberland DC, Procter AE, et al. Follow-up of conventional angioplasty versus laser thermal angioplasty for total femoropopliteal artery occlusions: results of a randomized trial. J Vasc Interv Radiol 1991;2:485-8.
466. Fisher CM, Fletcher JP, May J, et al. No additional benefit from laser in balloon angioplasty of the superficial femoral artery. Eur J Vasc Endovasc Surg 1996;11:349-52.
467. Jeans WD, Murphy P, Hughes AO, et al. Randomized trial of laser-assisted passage through occluded femoro-popliteal arteries. Br J Radiol 1990;63:19-21.
468. Lammer J, Pilger E, Decrinis M, et al. Pulsed excimer laser versus continuous-wave Nd:YAG laser versus conventional angioplasty of peripheral arterial occlusions: prospective, controlled, randomised trial. Lancet 1992;340:1183-8.
469. Minar E, Pokrajac B, Maca T, et al. Endovascular brachytherapy for prophylaxis of restenosis after femoropopliteal angioplasty: results of a prospective randomized study. Circulation 2000;102:2694-9.
470. Waksman R, Laird JR, Jurkovitz CT, et al. Intravascular radiation therapy after balloon angioplasty of narrowed femoropopliteal arteries to prevent restenosis: results of the PARIS feasibility clinical trial. J Vasc Interv Radiol 2001;12:915-21.
471. Sidawy AN, Weiswasser JM, Waksman R. Peripheral vascular brachytherapy. J Vasc Surg 2002;35:1041-7.
472. Zehnder T, von Briel C, Baumgartner I, et al. Endovascular brachytherapy after percutaneous transluminal angioplasty of recurrent femoropopliteal obstructions. J Endovasc Ther 2003; 10:304-11.
473. Krueger K, Landwehr P, Bendel M, et al. Endovascular gamma irradiation of femoropopliteal de novo stenoses immediately after PTA: interim results of prospective randomized controlled trial. Radiology 2002;224:519-28.
474. Jahnke T, Andresen R, Muller-Hulsbeck S, et al. Hemobahn stent-grafts for treatment of femoropopliteal arterial obstructions: midterm results of a prospective trial. J Vasc Interv Radiol 2003; 14:41-51.
475. Saxon RR, Coffman JM, Gooding JM, et al. Long-term results of ePTFE stent-graft versus angioplasty in the femoropopliteal artery: single center experience from a prospective, randomized trial. J Vasc Interv Radiol 2003;14:303-11.
476. Duda SH, Poerner TC, Wiesinger B, et al. Drug-eluting stents:

potential applications for peripheral arterial occlusive disease. J Vasc Interv Radiol 2003;14:291-301.
477. Duda SH, Pusich B, Richter G, et al. Sirolimus-eluting stents for the treatment of obstructive superficial femoral artery disease: six-month results. Circulation 2002;106:1505-9.
478. Girolami B, Bernardi E, Prins MH, et al. Antiplatelet therapy and other interventions after revascularisation procedures in patients with peripheral arterial disease: a meta-analysis. Eur J Vasc Endovasc Surg 2000;19:370-80.
479. Watson HR, Bergqvist D. Antithrombotic agents after peripheral transluminal angioplasty: a review of the studies, methods and evidence for their use. Eur J Vasc Endovasc Surg 2000;19:445-50.
480. Timaran CH, Prault TL, Stevens SL, et al. Iliac artery stenting versus surgical reconstruction for TASC (TransAtlantic Inter-Society Consensus) type B and type C iliac lesions. J Vasc Surg 2003;38:272-8.
481. Reed AB, Conte MS, Donaldson MC, et al. The impact of patient age and aortic size on the results of aortobifemoral bypass grafting. J Vasc Surg 2003;37:1219-25.
482. Olsen PS, Gustafsen J, Rasmussen L, et al. Long-term results after arterial surgery for arteriosclerosis of the lower limbs in young adults. Eur J Vasc Surg 1988;2:15-8.
483. Green RM, Abbott WM, Matsumoto T, et al. Prosthetic above-knee femoropopliteal bypass grafting: five-year results of a randomized trial. J Vasc Surg 2000;31:417-25.
484. Eagle KA, Berger PB, Calkins H, et al. ACC/AHA guideline update for perioperative cardiovascular evaluation for noncardiac surgery—executive summary a report of the American College of Cardiology/American Heart Association Task Force on Practice Guidelines (Committee to Update the 1996 Guidelines on Perioperative Cardiovascular Evaluation for Noncardiac Surgery). Circulation 2002;105:1257-67.
485. de Vries SO, Hunink MG. Results of aortic bifurcation grafts for aortoiliac occlusive disease: a meta-analysis. J Vasc Surg 1997; 26:558-69.
486. van der Vliet JA, Scharn DM, de Waard JW, et al. Unilateral vascular reconstruction for iliac obstructive disease. J Vasc Surg 1994;19:610-4.
487. Ricco JB. Unilateral iliac artery occlusive disease: a randomized multicenter trial examining direct revascularization versus crossover bypass. Association Universitaire de Recherche en Chirurgie. Ann Vasc Surg 1992;6:209-19.
488. Raptis S, Faris I, Miller J, et al. The fate of the aortofemoral graft. Eur J Vasc Endovasc Surg 1995;9:97-102.
489. Oskam J, van den Dungen JJ, Boontje AH. Thromboendarterectomy for obstructive disease of the common iliac artery. Cardiovasc Surg 1996;4:356-9.
490. Pretre R, Katchatourian G, Bednarkiewicz M, et al. Aortoiliac endarterectomy: a 9-year experience. Thorac Cardiovasc Surg 1992;40:152-4.
491. Radoux JM, Maiza D, Coffin O. Long-term outcome of 121 iliofemoral endarterectomy procedures. Ann Vasc Surg 2001; 15:163-70.
492. Mingoli A, Sapienza P, Feldhaus RJ, et al. Comparison of femorofemoral and aortofemoral bypass for aortoiliac occlusive disease. J Cardiovasc Surg (Torino) 2001;42:381-7.
493. Mohan CR, Sharp WJ, Hoballah JJ, et al. A comparative evaluation of externally supported polytetrafluoroethylene axillobifemoral and axillounifemoral bypass grafts. J Vasc Surg 1995; 21:801-8; discussion 808-9.
494. Harrington ME, Harrington EB, Haimov M, et al. Axillofemoral bypass: compromised bypass for compromised patients. J Vasc Surg 1994;20:195-201.
495. Onohara T, Komori K, Kume M, et al. Multivariate analysis of long-term results after an axillobifemoral and aortobifemoral bypass in patients with aortoiliac occlusive disease. J Cardiovasc Surg (Torino) 2000;41:905-10.
496. Martin D, Katz SG. Axillofemoral bypass for aortoiliac occlusive disease. Surg Gynecol Obstet 2000;180:100-3.
497. Faries PL, LoGerfo FW, Hook SC, et al. The impact of diabetes on arterial reconstructions for multilevel arterial occlusive disease. Surg Gynecol Obstet 2001;181:251-5.
498. Archie JP Jr. Femoropopliteal bypass with either adequate ipsilateral reversed saphenous vein or obligatory polytetrafluoroethylene. Ann Vasc Surg 1994;8:475-84.
499. Nicoloff AD, Taylor LM Jr, McLafferty RB, et al. Patient recovery after infrainguinal bypass grafting for limb salvage. J Vasc Surg 1998;27:256-63; discussion 264-6.
500. Gentile AT, Lee RW, Moneta GL, et al. Results of bypass to the popliteal and tibial arteries with alternative sources of autogenous vein. J Vasc Surg 1996;23:272-9; discussion 279-80.
500a. Allen BT, Reilly JM, Rubin BG, et al. Femoropopliteal bypass for claudication: vein vs. PTFE. Ann Vasc Surg 1996;10:178-85.
501. Taylor LM Jr, Edwards JM, Porter JM. Present status of reversed vein bypass grafting: five-year results of a modern series. J Vasc Surg 1990;11:193-205; discussion 205-6.
502. Schweiger H, Klein P, Lang W. Tibial bypass grafting for limb salvage with ringed polytetrafluoroethylene prostheses: results of primary and secondary procedures. J Vasc Surg 1993;18:867-74.
503. Londrey GL, Ramsey DE, Hodgson KJ, et al. Infrapopliteal bypass for severe ischemia: comparison of autogenous vein, composite, and prosthetic grafts. J Vasc Surg 1991;13:631-6.
504. McCarthy WJ, Pearce WH, Flinn WR, et al. Long-term evaluation of composite sequential bypass for limb-threatening ischemia. J Vasc Surg 1992;15:761-9; discussion 769-70.
505. Desai TR, Meyerson SL, Skelly CL, et al. Patency and limb salvage after infrainguinal bypass with severely compromised (“blind”) outflow. Arch Surg 2001;136:635-42.
506. Towne JB, Bernhard VM, Rollins DL, et al. Profundaplasty in perspective: limitations in the long-term management of limb ischemia. Surgery 1981;90:1037-46.
507. Kalman PG, Johnston KW, Walker PM. The current role of isolated profundaplasty. J Cardiovasc Surg (Torino) 1990;31:107-11.
508. AbuRahma AF, Robinson PA, Holt SM. Prospective controlled study of polytetrafluoroethylene versus saphenous vein in claudicant patients with bilateral above knee femoropopliteal bypasses. Surgery 1999;126:594-601; discussion 601-2.
509. Johnson WC, Lee KK. A comparative evaluation of polytetrafluoroethylene, umbilical vein, and saphenous vein bypass grafts for femoral-popliteal above-knee revascularization: a prospective randomized Department of Veterans Affairs cooperative study. J Vasc Surg 2000;32:268-77.
510. Klinkert P, Schepers A, Burger DH, et al. Vein versus polytetrafluoroethylene in above-knee femoropopliteal bypass grafting: five-year results of a randomized controlled trial. J Vasc Surg 2003;37:149-55.
511. Baldwin ZK, Pearce BJ, Curi MA, et al. Limb salvage after infrainguinal bypass graft failure. J Vasc Surg 2004;39:951-7.
512. Veith FJ, Gupta SK, Ascer E, et al. Six-year prospective multicenter randomized comparison of autologous saphenous vein and expanded polytetrafluoroethylene grafts in infrainguinal arterial reconstructions. J Vasc Surg 1986;3:104-14.
513. Brothers TE, Greenfield LJ. Long-term results of aortoiliac reconstruction. J Vasc Interv Radiol 1990;1:49-55.

514. Criado E, Burnham SJ, Tinsley EA Jr, et al. Femorofemoral bypass graft: analysis of patency and factors influencing long-term outcome. J Vasc Surg 1993;18:495-504; discussion 504-5.
515. Perler BA, Williams GM. Does donor iliac artery percutaneous transluminal angioplasty or stent placement influence the results of femorofemoral bypass? Analysis of 70 consecutive cases with long-term follow-up. J Vasc Surg 1996;24:363-9; discussion 369-70.
516. Szilagyi DE, Elliott JP Jr, Smith RF, et al. A thirty-year survey of the reconstructive surgical treatment of aortoiliac occlusive disease. J Vasc Surg 1986;3:421-36.
517. Johnson WC, Lee KK. Comparative evaluation of externally supported Dacron and polytetrafluoroethylene prosthetic bypasses for femorofemoral and axillofemoral arterial reconstructions. Veterans Affairs Cooperative Study #141. J Vasc Surg 1999;30:1077-83.
518. Rutherford RB, Baker JD, Ernst C, et al. Recommended standards for reports dealing with lower extremity ischemia: revised version. J Vasc Surg 1997;26:517-38. Erratum in: J Vasc Surg 2001;33:805.
519. Intravenous pentoxifylline for the treatment of chronic critical limb ischaemia. The European Study Group. Eur J Vasc Endovasc Surg 1995;9:426-36.
520. Efficacy and clinical tolerance of parenteral pentoxifylline in the treatment of critical lower limb ischemia: a placebo controlled multicenter study. Norwegian Pentoxifylline Multicenter Trial Group. Int Angiol 1996;15:75-80.
521. Nizankowski R, Krolikowski W, Bielatowicz J, et al. Prostacyclin for ischemic ulcers in peripheral arterial disease: a random assignment, placebo controlled study. Thromb Res 1985;37:21-8.
522. Negus D, Irving JD, Friedgood A. Intra-arterial prostacyclin compared to Praxilene in the management of severe lower limb ischaemia: a double blind trial. J Cardiovasc Surg (Torino) 1987;28:196-9.
523. Eklund AE, Eriksson G, Olsson AG. A controlled study showing significant short term effect of prostaglandin E1 in healing of ischaemic ulcers of the lower limb in man. Prostaglandins Leukot Med 1982;8:265-71.
524. Schuler JJ, Flanigan DP, Holcroft JW, et al. Efficacy of prostaglandin E1 in the treatment of lower extremity ischemic ulcers secondary to peripheral vascular occlusive disease: results of a prospective randomized, double-blind, multicenter clinical trial. J Vasc Surg 1984;1:160-70.
525. Telles GS, Campbell WB, Wood RF, et al. Prostaglandin E1 in severe lower limb ischaemia: a double-blind controlled trial. Br J Surg 1984;71:506-8.
526. Belch JJ, McKay A, McArdle B, et al. Epoprostenol (prostacyclin) and severe arterial disease: a double-blind trial. Lancet 1983;1:315-7.
527. Cronenwett JL, Zelenock GB, Whitehouse WM Jr, et al. Prostacyclin treatment of ischemic ulcers and rest pain in unreconstructible peripheral arterial occlusive disease. Surgery 1986;100:369-75.
528. Trubestein G, Diehm C, Gruss JD, et al. Prostaglandin E1 in chronic arterial disease—a multicenter study. Vasa Suppl 1987;17:39-43.
529. The effect of ciprostene in patients with peripheral vascular disease (PVD) characterized by ischemic ulcers. The Ciprostene Study Group. J Clin Pharmacol 1991;31:81-7.
530. Prostanoids for chronic critical leg ischemia. A randomized, controlled, open-label trial with prostaglandin E1. The ICAI Study Group. Ischemia Cronica degli Arti Inferiori. Ann Intern Med 1999;130:412-21.
531. Trubestein G, von Bary S, Breddin K, et al. Intravenous prostaglandin E1 versus pentoxifylline therapy in chronic arterial occlusive disease—a controlled randomised multicenter study. Vasa Suppl 1989;28:44-9.
532. Balzer K, Bechara G, Bisler H, et al. Reduction of ischaemic rest pain in advanced peripheral arterial occlusive disease: a double blind placebo controlled trial with iloprost. Int Angiol 1991; 10:229-32.
533. Diehm C, Abri O, Baitsch G, et al. [Iloprost, a stable prostacyclin derivative, in stage 4 arterial occlusive disease: a placebo-controlled multicenter study] Dtsch Med Wochenschr 1989;114:783-8.
534. Norgren L, Alwmark A, Angqvist KA, et al. A stable prostacyclin analogue (iloprost) in the treatment of ischaemic ulcers of the lower limb: a Scandinavian-Polish placebo controlled, randomised multicenter study. Eur J Vasc Surg 1990;4:463-7.
535. Brock FE, Abri O, Baitsch G, et al. [Iloprost in the treatment of ischemic tissue lesions in diabetics: results of a placebo-controlled multicenter study with a stable prostacyclin derivative] Schweiz Med Wochenschr 1990;120:1477-82.
536. Treatment of limb threatening ischaemia with intravenous iloprost: a randomised double-blind placebo controlled study. U.K. Severe Limb Ischaemia Study Group. Eur J Vasc Surg 1991; 5:511-6.
537. Two randomised and placebo-controlled studies of an oral prostacyclin analogue (Iloprost) in severe leg ischaemia. The Oral Iloprost in severe Leg Ischaemia Study Group. Eur J Vasc Endovasc Surg 2000;20:358-62.
538. Isner JM, Walsh K, Symes J, et al. Arterial gene therapy for therapeutic angiogenesis in patients with peripheral artery disease. Circulation 1995;91:2687-92.
539. Isner JM, Pieczek A, Schainfeld R, et al. Clinical evidence of angiogenesis after arterial gene transfer of phVEGF165 in patient with ischaemic limb. Lancet 1996;348:370-4.
540. Isner JM. Arterial gene transfer of naked DNA for therapeutic angiogenesis: early clinical results. Adv Drug Deliv Rev 1998;30(1-3):185-97.
541. Baumgartner I, Pieczek A, Manor O, et al. Constitutive expression of phVEGF165 after intramuscular gene transfer promotes collateral vessel development in patients with critical limb ischemia. Circulation 1998;97:1114-23.
542. Nasr MK, McCarthy RJ, Hardman J, et al. The increasing role of percutaneous transluminal angioplasty in the primary management of critical limb ischaemia. Eur J Vasc Endovasc Surg 2002;23:398-403.
543. Isner JM, Rosenfield K. Redefining the treatment of peripheral artery disease: role of percutaneous revascularization. Circulation 1993;88(4 pt 1):1534-57.
544. Durham JR, Horowitz JD, Wright JG, et al. Percutaneous transluminal angioplasty of tibial arteries for limb salvage in the high-risk diabetic patient. Ann Vasc Surg 1994;8:48-53.
545. Isner JM, Pieczek A, Rosenfield K. Images in cardiovascular medicine: untreated gangrene in patients with peripheral artery disease. Circulation 1994;89:482-3.
546. Gray BH, Laird JR, Ansel GM, et al. Complex endovascular treatment for critical limb ischemia in poor surgical candidates: a pilot study. J Endovasc Ther 2002;9:599-604.
547. Faglia E, Mantero M, Caminiti M, et al. Extensive use of peripheral angioplasty, particularly infrapopliteal, in the treatment of ischaemic diabetic foot ulcers: clinical results of a multicentric study of 221 consecutive diabetic subjects. J Intern Med 2002;252:225-32.

548. Ingle H, Nasim A, Bolia A, et al. Subintimal angioplasty of isolated infragenicular vessels in lower limb ischemia: long-term results. J Endovasc Ther 2002;9:411-6. Erratum in: J Endovasc Ther 2002;9:A-6.
549. Gordon IL, Conroy RM, Arefi M, et al. Three-year outcome of endovascular treatment of superficial femoral artery occlusion. Arch Surg 2001;136:221-8.
550. Spence LD, Hartnell GG, Reinking G, et al. Diabetic versus nondiabetic limb-threatening ischemia: outcome of percutaneous iliac intervention. AJR Am J Roentgenol 1999;172:1335-41.
551. Marzelle J, Fichelle JM, Cormier F, et al. Outcome of infrainguinal endovascular revascularization procedures for limb-threatening ischemia. Ann Vasc Surg 1995;9 suppl:S24-31.
552. Bernstein EF, Rhodes GA, Stuart SH, et al. Toe pulse reappearance time in prediction of aortofemoral bypass success. Ann Surg 1981;193:201-5.
553. Bakal CW, Cynamon J, Sprayregen S. Infrapopliteal percutaneous transluminal angioplasty: what we know. Radiology 1996;200:36-43.
554. Berridge DC, Gregson RH, Hopkinson BR, et al. Randomized trial of intra-arterial recombinant tissue plasminogen activator, intravenous recombinant tissue plasminogen activator and intra-arterial streptokinase in peripheral arterial thrombolysis. Br J Surg 1991;78:988-95.
555. Graor RA, Risius B, Young JR, et al. Thrombolysis of peripheral arterial bypass grafts: surgical thrombectomy compared with thrombolysis: a preliminary report. J Vasc Surg 1988;7:347-55.
556. Ouriel K, Kandarpa K, Schuerr DM, et al. Prourokinase versus urokinase for recanalization of peripheral occlusions, safety and efficacy: the PURPOSE trial. J Vasc Interv Radiol 1999;10:1083-91.
557. Mahler F, Schneider E, Hess H; Steering Committee, Study on Local Thrombolysis. Recombinant tissue plasminogen activator versus urokinase for local thrombolysis of femoropopliteal occlusions: a prospective, randomized multicenter trial. J Endovasc Ther 2001;8:638-47.
558. Khosla S, Jain P, Manda R, et al. Acute and long-term results after intra-arterial thrombolysis of occluded lower extremity bypass grafts using recombinant tissue plasminogen activator for acute limb-threatening ischemia. Am J Ther 2003;10:3-6.
559. Ouriel K, Shortell CK, DeWeese JA, et al. A comparison of thrombolytic therapy with operative revascularization in the initial treatment of acute peripheral arterial ischemia. J Vasc Surg 1994;19:1021-30.
560. Results of a prospective randomized trial evaluating surgery versus thrombolysis for ischemia of the lower extremity. The STILE trial. Ann Surg 1994;220:251-66; discussion 266-8.
561. Weaver FA, Comerota AJ, Youngblood M, et al. Surgical revascularization versus thrombolysis for nonembolic lower extremity native artery occlusions: results of a prospective randomized trial. The STILE Investigators. Surgery versus Thrombolysis for Ischemia of the Lower Extremity. J Vasc Surg 1996;24:513-21; discussion 521-3.
562. Ouriel K, Veith FJ, Sasahara AA. A comparison of recombinant urokinase with vascular surgery as initial treatment for acute arterial occlusion of the legs. Thrombolysis or Peripheral Arterial Surgery (TOPAS) Investigators. N Engl J Med 1998;338:1105-11.
563. Diffin DC, Kandarpa K. Assessment of peripheral intraarterial thrombolysis versus surgical revascularization in acute lower-limb ischemia: a review of limb-salvage and mortality statistics. J Vasc Interv Radiol 1996;7:57-63.
564. van Breda A, Katzen BT, Deutsch AS. Urokinase versus streptokinase in local thrombolysis. Radiology 1987;165:109-11.
565. Traughber PD, Cook PS, Micklos TJ, et al. Intraarterial fibrinolytic therapy for popliteal and tibial artery obstruction: comparison of streptokinase and urokinase. AJR Am J Roentgenol 1987;149:453-6.
566. Arepally A, Hofmann LV, Kim HS, et al. Weight-based rt-PA thrombolysis protocol for acute native arterial and bypass graft occlusions. J Vasc Interv Radiol 2002;13:45-50.
567. Swischuk JL, Fox PF, Young K, et al. Transcatheter intraarterial infusion of rt-PA for acute lower limb ischemia: results and complications. J Vasc Interv Radiol 2001;12:423-30.
568. Semba CP, Murphy TP, Bakal CW, et al. Thrombolytic therapy with use of alteplase (rt-PA) in peripheral arterial occlusive disease: review of the clinical literature. The Advisory Panel. J Vasc Interv Radiol 2000;11(2 pt 1):149-61.
569. Shortell CK, Queiroz R, Johansson M, et al. Safety and efficacy of limited-dose tissue plasminogen activator in acute vascular occlusion. J Vasc Surg 2001;34:854-9.
570. Braithwaite BD, Buckenham TM, Galland RB, et al. Prospective randomized trial of high-dose bolus versus low-dose tissue plasminogen activator infusion in the management of acute limb ischaemia. Thrombolysis Study Group. Br J Surg 1997;84:646-50.
571. Ouriel K, Gray B, Clair DG, et al. Complications associated with the use of urokinase and recombinant tissue plasminogen activator for catheter-directed peripheral arterial and venous thrombolysis. J Vasc Interv Radiol 2000;11:295-8.
572. Schweizer J, Altmann E, Stosslein F, et al. Comparison of tissue plasminogen activator and urokinase in the local infiltration thrombolysis of peripheral arterial occlusions. Eur J Radiol 1996;22:129-32.
573. Ouriel K, Katzen B, Mewissen M, et al. Reteplase in the treatment of peripheral arterial and venous occlusions: a pilot study. J Vasc Interv Radiol 2000;11:849-54.
574. Davidian MM, Powell A, Benenati JF, et al. Initial results of reteplase in the treatment of acute lower extremity arterial occlusions. J Vasc Interv Radiol 2000;11:289-94.
575. Castaneda F, Swischuk JL, Li R, et al. Declining-dose study of reteplase treatment for lower extremity arterial occlusions. J Vasc Interv Radiol 2002;13:1093-8.
576. Burkart DJ, Borsa JJ, Anthony JP, et al. Thrombolysis of occluded peripheral arteries and veins with tenecteplase: a pilot study. J Vasc Interv Radiol 2002;13:1099-102.
577. Meyerovitz MF, Goldhaber SZ, Reagan K, et al. Recombinant tissue-type plasminogen activator versus urokinase in peripheral arterial and graft occlusions: a randomized trial. Radiology 1990;175:75-8.
578. Cina CS, Goh RH, Chan J, et al. Intraarterial catheter-directed thrombolysis: urokinase versus tissue plasminogen activator. Ann Vasc Surg 1999;13:571-5.
579. Sugimoto K, Hofmann LV, Razavi MK, et al. The safety, efficacy, and pharmacoeconomics of low-dose alteplase compared with urokinase for catheter-directed thrombolysis of arterial and venous occlusions. J Vasc Surg 2003;37:512-7.
580. Drescher P, McGuckin J, Rilling WS, et al. Catheter-directed thrombolytic therapy in peripheral artery occlusions: combining reteplase and abciximab. AJR Am J Roentgenol 2003;180:1385-91.
581. Burkart DJ, Borsa JJ, Anthony JP, et al. Thrombolysis of acute peripheral arterial and venous occlusions with tenecteplase and eptifibatide: a pilot study. J Vasc Interv Radiol 2003;14:729-33.
582. Duda SH, Tepe G, Luz O, et al. Peripheral artery occlusion: treatment with abciximab plus urokinase versus with urokinase alone—a randomized pilot trial (the PROMPT Study). Platelet Receptor Antibodies in Order to Manage Peripheral Artery

Thrombosis. Radiology 2001;221:689-96.
583. Yoon HC, Miller FJ Jr. Using a peptide inhibitor of the glycoprotein IIb/IIIa platelet receptor: initial experience in patients with acute peripheral arterial occlusions. AJR Am J Roentgenol 2002;178:617-22.
584. Silva JA, Ramee SR, Collins TJ, et al. Rheolytic thrombectomy in the treatment of acute limb-threatening ischemia: immediate results and six-month follow-up of the multicenter AngioJet registry. Possis Peripheral AngioJet Study AngioJet Investigators. Cathet Cardiovasc Diagn 1998;45:386-93.
585. Kasirajan K, Haskal ZJ, Ouriel K. The use of mechanical thrombectomy devices in the management of acute peripheral arterial occlusive disease. J Vasc Interv Radiol 2001;12:405-11.
586. Hopfner W, Vicol C, Bohndorf K, et al. Shredding embolectomy thrombectomy catheter for treatment of acute lower-limb ischemia. Ann Vasc Surg 1999;13:426-35.
587. Muller-Hulsbeck S, Kalinowski M, Heller M, et al. Rheolytic hydrodynamic thrombectomy for percutaneous treatment of acutely occluded infra-aortic native arteries and bypass grafts: midterm follow-up results. Invest Radiol 2000;35:131-40.
588. Kasirajan K, Gray B, Beavers FP, et al. Rheolytic thrombectomy in the management of acute and subacute limb-threatening ischemia. J Vasc Interv Radiol 2001;12:413-21.
589. Wagner HJ, Muller-Hulsbeck S, Pitton MB, et al. Rapid thrombectomy with a hydrodynamic catheter: results from a prospective, multicenter trial. Radiology 1997;205:675-81.
590. Reekers JA, Kromhout JG, Spithoven HG, et al. Arterial thrombosis below the inguinal ligament: percutaneous treatment with a thrombosuction catheter. Radiology 1996;198:49-53.
591. Henry M, Amor M, Henry I, et al. The Hydrolyser thrombectomy catheter: a single-center experience. J Endovasc Surg 1998;5:24-31.
592. Rilinger N, Gorich J, Scharrer-Pamler R, et al. Short-term results with use of the Amplatz thrombectomy device in the treatment of acute lower limb occlusions. J Vasc Interv Radiol 1997;8:343-8.
593. Tadavarthy SM, Murray PD, Inampudi S, et al. Mechanical thrombectomy with the Amplatz device: human experience. J Vasc Interv Radiol 1994;5:715-24.
594. Gorich J, Rilinger N, Sokiranski R, et al. Mechanical thrombolysis of acute occlusion of both the superficial and the deep femoral arteries using a thrombectomy device. AJR Am J Roentgenol 1998;170:1177-80.
594a. Haskal ZJ. Mechanical thrombectomy devices for the treatment of peripheral arterial occlusions. Rev Cardiovasc Med 2002;3 Suppl 2:S45-S52.
595. Schneider JR, Besso SR, Walsh DB, et al. Femorofemoral versus aortobifemoral bypass: outcome and hemodynamic results. J Vasc Surg 1994;19:43-55; discussion 55-7.
596. Hobson RW 2nd, Lynch TG, Jamil Z, et al. Results of revascularization and amputation in severe lower extremity ischemia: a five-year clinical experience. J Vasc Surg 1985;2:174-85.
597. Schina MJ Jr, Atnip RG, Healy DA, et al. Relative risks of limb revascularization and amputation in the modern era. Cardiovasc Surg 1994;2:754-9.
598. Dawson I, Keller BP, Brand R, et al. Late outcomes of limb loss after failed infrainguinal bypass. J Vasc Surg 1995;21:613-22.
599. Moller BN, Solund K, Hansen SL. Wound infection after lower extremity amputation because of ischemia. Arch Orthop Trauma Surg 1985;104:262-4.
600. Cutson TM, Bongiorni DR. Rehabilitation of the older lower limb amputee: a brief review. J Am Geriatr Soc 1996;44:1388-93.
601. Propanolol Aneurysm Trial Investigators. Propranolol for small abdominal aortic aneurysms: results of a randomized trial. J Vasc Surg 2002;35:72-9.
602. Kalman PG, Hosang M, Johnston KW, et al. Unilateral iliac disease: the role of iliofemoral bypass. J Vasc Surg 1987;6:139-43.
603. Ng RL, Gillies TE, Davies AH, et al. Iliofemoral versus femorofemoral bypass: a 6-year audit. Br J Surg 1992;79:1011-3.
604. Naylor AR, Ah-See AK, Engeset J. Axillofemoral bypass as a limb salvage procedure in high risk patients with aortoiliac disease. Br J Surg 1990;77:659-61.
605. Ascer E, Veith FJ, Gupta SK, et al. Comparison of axillounifemoral and axillobifemoral bypass operations. Surgery 1985;97:169-75.
606. Shah DM, Darling RC 3rd, Chang BB, et al. Is long vein bypass from groin to ankle a durable procedure? An analysis of a ten-year experience. J Vasc Surg 1992;15:402-7; discussion 407-8.
607. Pomposelli FB Jr, Marcaccio EJ, Gibbons GW, et al. Dorsalis pedis arterial bypass: durable limb salvage for foot ischemia in patients with diabetes mellitus. J Vasc Surg 1995;21:375-84.
608. Roddy SP, Darling RC 3rd, Ozsvath KJ, et al. Composite sequential arterial reconstruction for limb salvage. J Vasc Surg 2002;36:325-9.
609. Johnson WC, Williford WO; Department of Veterans Affairs Cooperative Study #362. Benefits, morbidity, and mortality associated with long-term administration of oral anticoagulant therapy to patients with peripheral arterial bypass procedures: a prospective randomized study. J Vasc Surg 2002;35:413-21.
610. Hamdan AD, Rayan SS, Hook SC, et al. Bypasses to tibial vessels using polytetrafluoroethylene as the solo conduit in a predominantly diabetic population. Vasc Endovascular Surg 2002;36:59-63.
611. Henke PK, Blackburn S, Proctor MC, et al. Patients undergoing infrainguinal bypass to treat atherosclerotic vascular disease are underprescribed cardioprotective medications: effect on graft patency, limb salvage, and mortality. J Vasc Surg 2004;39:357-65.
612. Holley KE, Hunt JC, Brown AL Jr, et al. Renal artery stenosis: a clinical-pathologic study in normotensive and hypertensive patients. Am J Med 1964;37:14-22.
613. Dustan HP, Humphries AW, Dewolfe VG, et al. Normal arterial pressure in patients with renal arterial stenosis. JAMA 1964;187:1028-9.
614. Scoble JE. The epidemiology and clinical manifestations of atherosclerotic renal disease. In: Novick AC, Scoble JE, Hamilton G, eds. Renal Vascular Disease. London, UK: WB Saunders Co, Ltd; 1996:303-14.
615. Uzu T, Inoue T, Fujii T, et al. Prevalence and predictors of renal artery stenosis in patients with myocardial infarction. Am J Kidney Dis 1997;29:733-8.
616. Wilms G, Marchal G, Peene P, et al. The angiographic incidence of renal artery stenosis in the arteriosclerotic population. Eur J Radiol 1990;10:195-7.
617. Choudhri AH, Cleland JG, Rowlands PC, et al. Unsuspected renal artery stenosis in peripheral vascular disease. BMJ 1990; 301:1197-8.
618. Swartbol P, Thorvinger BO, Parsson H, et al. Renal artery stenosis in patients with peripheral vascular disease and its correlation to hypertension: a retrospective study. Int Angiol 1992;11:195-9.
619. Missouris CG, Papavassiliou MB, Khaw K, et al. High prevalence of carotid artery disease in patients with atheromatous renal artery stenosis. Nephrol Dial Transplant 1998;13:945-8.
620. Hansen KJ, Edwards MS, Craven TE, et al. Prevalence of renovascular disease in the elderly: a population-based study. J Vasc Surg 2002;36:443-51.
621. Harding MB, Smith LR, Himmelstein SI, et al. Renal artery stenosis: prevalence and associated risk factors in patients undergoing

routine cardiac catheterization. J Am Soc Nephrol 1992;2:1608-16.
622. Weber-Mzell D, Kotanko P, Schumacher M, et al. Coronary anatomy predicts presence or absence of renal artery stenosis: a prospective study in patients undergoing cardiac catheterization for suspected coronary artery disease. Eur Heart J 2002;23:1684-91.
623. Jean WJ, al-Bitar I, Zwicke DL, et al. High incidence of renal artery stenosis in patients with coronary artery disease. Cathet Cardiovasc Diagn 1994;32:8-10.
624. Missouris CG, Buckenham T, Cappuccio FP, et al. Renal artery stenosis: a common and important problem in patients with peripheral vascular disease. Am J Med 1994;96:10-4.
625. Olin JW, Melia M, Young JR, et al. Prevalence of atherosclerotic renal artery stenosis in patients with atherosclerosis elsewhere. Am J Med 1990;88(1N):46N-51N.
626. Louie J, Isaacson JA, Zierler RE, et al. Prevalence of carotid and lower extremity arterial disease in patients with renal artery stenosis. Am J Hypertens 1994;7:436-9.
627. Zierler RE, Bergelin RO, Polissar NL, et al. Carotid and lower extremity arterial disease in patients with renal artery atherosclerosis. Arch Intern Med 1998;158:761-7.
628. Rossi GP, Rossi A, Zanin L, et al. Excess prevalence of extracranial carotid artery lesions in renovascular hypertension. Am J Hypertens 1992;5:8-15.
629. Metcalfe W, Reid AW, Geddes CC. Prevalence of angiographic atherosclerotic renal artery disease and its relationship to the anatomical extent of peripheral vascular atherosclerosis. Nephrol Dial Transplant 1999;14:105-8.
630. Valentine RJ, Clagett GP, Miller GL, et al. The coronary risk of unsuspected renal artery stenosis. J Vasc Surg 1993;18:433-9; discussion 439-40.
631. Schwartz CJ, White TA. Stenosis of renal artery: an unselected necropsy study. Br Med J 1964;5422:1415-21.
632. Rimmer JM, Gennari FJ. Atherosclerotic renovascular disease and progressive renal failure. Ann Intern Med 1993;118:712-9.
633. Wollenweber J, Sheps SG, Davis GD. Clinical course of atherosclerotic renovascular disease. Am J Cardiol 1968;21:60-71.
634. Meaney TF, Dustan HP, McCormack LJ. Natural history of renal arterial disease. Radiology 1968;91:881-7.
635. Schreiber MJ, Pohl MA, Novick AC. The natural history of atherosclerotic and fibrous renal artery disease. Urol Clin North Am 1984;11:383-92.
636. Tollefson DF, Ernst CB. Natural history of atherosclerotic renal artery stenosis associated with aortic disease. J Vasc Surg 1991; 14:327-31.
637. Dean RH, Kieffer RW, Smith BM, et al. Renovascular hypertension: anatomic and renal function changes during drug therapy. Arch Surg 1981;116:1408-15.
638. Zierler RE, Bergelin RO, Davidson RC, et al. A prospective study of disease progression in patients with atherosclerotic renal artery stenosis. Am J Hypertens 1996;9:1055-61.
639. Caps MT, Perissinotto C, Zierler RE, et al. Prospective study of atherosclerotic disease progression in the renal artery. Circulation 1998;98:2866-72.
640. Mailloux LU, Napolitano B, Bellucci AG, et al. Renal vascular disease causing end-stage renal disease, incidence, clinical correlates, and outcomes: a 20-year clinical experience. Am J Kidney Dis 1994;24:622-9.
641. Guzman RP, Zierler RE, Isaacson JA, et al. Renal atrophy and arterial stenosis. A prospective study with duplex ultrasound. Hypertension 1994;23:346-50.
642. Caps MT, Zierler RE, Polissar NL, et al. Risk of atrophy in kidneys with atherosclerotic renal artery stenosis. Kidney Int 1998; 53:735-42.
643. Crowley JJ, Santos RM, Peter RH, et al. Progression of renal artery stenosis in patients undergoing cardiac catheterization. Am Heart J 1998;136:913-8.
644. Eggers PW, Connerton R, McMullan M. The Medicare experience with end-stage renal disease: trends in incidence, prevalence, and survival. Health Care Financ Rev 1984;5:69-88.
645. Mailloux LU, Bellucci AG, Mossey RT, et al. Predictors of survival in patients undergoing dialysis. Am J Med 1988;84:855-62.
646. Dorros G, Jaff M, Mathiak L, et al. Four-year follow-up of Palmaz-Schatz stent revascularization as treatment for atherosclerotic renal artery stenosis. Circulation 1998;98:642-7.
647. Wright JR, Shurrab AE, Cheung C, et al. A prospective study of the determinants of renal functional outcome and mortality in atherosclerotic renovascular disease. Am J Kidney Dis 2002; 39:1153-61.
648. Gifford RW Jr, McCormack LJ, Poutasse EF. The atrophic kidney: its role in hypertension. Mayo Clin Proc 1965;40:834-52.
649. Packer M, Lee WH, Medina N, et al. Functional renal insufficiency during long-term therapy with captopril and enalapril in severe chronic heart failure. Ann Intern Med 1987;106:346-54.
650. Textor SC. Renal failure related to angiotensin-converting enzyme inhibitors. Semin Nephrol 1997;17:67-76.
651. Watson ML, Bell GM, Muir AL, et al. Captopril/diuretic combinations in severe renovascular disease: a cautionary note. Lancet 1983;2:404-5.
652. Hricik DE, Browning PJ, Kopelman R, et al. Captopril-induced functional renal insufficiency in patients with bilateral renal-artery stenoses or renal-artery stenosis in a solitary kidney. N Engl J Med 1983;308:373-6.
652a. Bakris GL, Weir MR. Angiotensin converting enzyme inhibitor-associated elevations in serum creatinine. Arch Int Med 2000; 160:685-93.
653. Safian RD, Textor SC. Renal-artery stenosis. N Engl J Med 2001;344:431-42.
654. Luscher TF, Keller HM, Imhof HG, et al. Fibromuscular hyperplasia: extension of the disease and therapeutic outcome: results of the University Hospital Zurich Cooperative Study on Fibromuscular Hyperplasia. Nephron 1986;44 suppl 1:109-14.
655. Archibald GR, Beckmann CF, Libertino JA. Focal renal artery stenosis caused by fibromuscular dysplasia: treatment by percutaneous transluminal angioplasty. AJR Am J Roentgenol 1988;151:593-6.
656. Cluzel P, Raynaud A, Beyssen B, et al. Stenoses of renal branch arteries in fibromuscular dysplasia: results of percutaneous transluminal angioplasty. Radiology 1994;193:227-32.
657. Mounier-Vehier C, Haulon S, Devos P, et al. Renal atrophy outcome after revascularization in fibromuscular dysplasia disease. J Endovasc Ther 2002;9:605-13.
658. Stanley JC, Gewertz BL, Bove EL, et al. Arterial fibrodysplasia: histopathologic character and current etiologic concepts. Arch Surg 1975;110:561-6.
659. Stanley JC, Wakefield TW. Arterial fibrodysplasia. In: Rutherford RB, ed. Vascular Surgery 6th ed. Philadelphia, Pa: Saunders; 2004:387-408.
660. Messina LM, Stanley JC. Renal artery fibrodysplasia and renovascular hypertension. In: Rutherford RB, ed. Vascular Surgery 6th ed. Philadelphia, Pa: Saunders; 2004:1650-64.
661. Mettinger KL. Fibromuscular dysplasia and the brain. II. Current concept of the disease. Stroke 1982;13:53-8.
662. Cloft HJ, Kallmes DF, Kallmes MH, et al. Prevalence of cerebral aneurysms in patients with fibromuscular dysplasia: a reassess-

ment. J Neurosurg 1998;88:436-40.
663. Abud O, Chechile GE, Sole-Balcells F. Aneurysm and arteriovenous malformation. In: Novick AC, Scoble JE, Hamilton G, eds. Renal Vascular Disease. London, UK: WB Saunders Co, Ltd; 1996:35-46.
664. Novick AC. Renal artery aneurysms and arteriovenous malformation. In: Novick AC, Straffon RA, eds. Vascular Problems in Urologic Surgery Philadelphia, Pa: WB Saunders; 1982:189-204.
665. Poutasse EF. Renal artery aneurysms. J Urol 1975;113:443-9.
666. McCready RA, Hyde GL, Bivins BA, et al. Radiation-induced arterial injuries. Surgery 1983;93:306-12.
667. Guthaner DF, Schmitz L. Percutaneous transluminal angioplasty of radiation-induced arterial stenoses. Radiology 1982;144:77-8.
668. Andros G, Schneider PA, Harris RW, et al. Management of arterial occlusive disease following radiation therapy. Cardiovasc Surg 1996;4:135-42.
669. Ingelfinger JR, Newburger JW. Spectrum of renal anomalies in patients with Williams syndrome. J Pediatr 1991;119:771-3.
670. Booth C, Preston R, Clark G, et al. Management of renal vascular disease in neurofibromatosis type 1 and the role of percutaneous transluminal angioplasty. Nephrol Dial Transplant 2002;17:1235-40.
671. Courtel JV, Soto B, Niaudet P, et al. Percutaneous transluminal angioplasty of renal artery stenosis in children. Pediatr Radiol 1998;28:59-63.
672. Tyagi S, Singh B, Kaul UA, et al. Balloon angioplasty for renovascular hypertension in Takayasu's arteritis. Am Heart J 1993; 125(5 pt 1):1386-93.
673. Teoh MK. Takayasu's arteritis with renovascular hypertension: results of surgical treatment. Cardiovasc Surg 1999;7:626-32.
674. Prigent A, Cosgriff P, Gates GF, et al. Consensus report on quality control of quantitative measurements of renal function obtained from the renogram: International Consensus Committee from the Scientific Committee of Radionuclides in Nephrourology. Semin Nucl Med 1999;29:146-59.
675. Nally JV Jr, Clarke HS Jr, Grecos GP, et al. Effect of captopril on 99mTc-diethylenetriaminepentaacetic acid renograms in two-kidney, one clip hypertension. Hypertension 1986;8:685-93.
676. Setaro JF, Saddler MC, Chen CC, et al. Simplified captopril renography in diagnosis and treatment of renal artery stenosis. Hypertension 1991;18:289-98.
677. Dondi M. Captopril renal scintigraphy with 99mTc-mercaptoacetyltriglycine (99mTc-MAG3) for detecting renal artery stenosis. Am J Hypertens 1991;4(12 pt 2):737S-740S.
678. Fommei E, Ghione S, Hilson AJ, et al. Captopril radionuclide test in renovascular hypertension: a European multicentre study. European Multicentre Study Group. Eur J Nucl Med 1993;20: 617-23.
679. Geyskes GG, Oei HY, Puylaert CB, et al. Renography with captopril. Changes in a patient with hypertension and unilateral renal artery stenosis. Arch Intern Med 1986;146:1705-8.
680. Sfakianakis GN, Bourgoignie JJ, Jaffe D, et al. Single-dose captopril scintigraphy in the diagnosis of renovascular hypertension. J Nucl Med 1987;28:1383-92.
681. Erbsloh-Moller B, Dumas A, Roth D, et al. Furosemide-131I-hippuran renography after angiotensin-converting enzyme inhibition for the diagnosis of renovascular hypertension. Am J Med 1991;90:23-9.
682. Mann SJ, Pickering TG, Sos TA, et al. Captopril renography in the diagnosis of renal artery stenosis: accuracy and limitations. Am J Med 1991;90:30-40.
683. Elliott WJ, Martin WB, Murphy MB. Comparison of two noninvasive screening tests for renovascular hypertension. Arch Intern Med 1993;153:755-64.
684. van Jaarsveld BC, Krijnen P, Derkx FH, et al. The place of renal scintigraphy in the diagnosis of renal artery stenosis: fifteen years of clinical experience. Arch Intern Med 1997;157:1226-34.
685. Mittal BR, Kumar P, Arora P, et al. Role of captopril renography in the diagnosis of renovascular hypertension. Am J Kidney Dis 1996;28:209-13.
686. Huot SJ, Hansson JH, Dey H, et al. Utility of captopril renal scans for detecting renal artery stenosis. Arch Intern Med 2002; 162:1981-4.
687. Carman TL, Olin JW. Diagnosis of renal artery stenosis: what is the optimal diagnostic test? Curr Interv Cardiol Rep 2000;2:111-8
688. Olin JW. Role of duplex ultrasonography in screening for significant renal artery disease. Urol Clin North Am 1994;21:215-26.
689. Hoffmann U, Edwards JM, Carter S, et al. Role of duplex scanning for the detection of atherosclerotic renal artery disease. Kidney Int 1991;39:1232-9.
690. Kohler TR, Zierler RE, Martin RL, et al. Noninvasive diagnosis of renal artery stenosis by ultrasonic duplex scanning. J Vasc Surg 1986;4:450-6.
691. Taylor DC, Kettler MD, Moneta GL, et al. Duplex ultrasound scanning in the diagnosis of renal artery stenosis: a prospective evaluation. J Vasc Surg 1988;7:363-9.
692. Wilcox CS. Ischemic nephropathy: noninvasive testing. Semin Nephrol 1996;16:43-52.
693. Carman TL, Olin JW, Czum J. Noninvasive imaging of the renal arteries. Urol Clin North Am 2001;28:815-26.
694. Olin JW, Piedmonte MR, Young JR, et al. The utility of duplex ultrasound scanning of the renal arteries for diagnosing significant renal artery stenosis. Ann Intern Med 1995;122:833-8.
695. Hudspeth DA, Hansen KJ, Reavis SW, et al. Renal duplex sonography after treatment of renovascular disease. J Vasc Surg 1993; 18:381-8; discussion 389-90.
696. Hansen KJ, Tribble RW, Reavis SW, et al. Renal duplex sonography: evaluation of clinical utility. J Vasc Surg 1990;12:227-36.
697. Kim SH, Kim WH, Choi BI, et al. Duplex Doppler US in patients with medical renal disease: resistive index vs serum creatinine level. Clin Radiol 1992;45:85-7.
698. Radermacher J, Chavan A, Bleck J, et al. Use of Doppler ultrasonography to predict the outcome of therapy for renal-artery stenosis. N Engl J Med 2001;344:410-7.
699. Leertouwer TC, Gussenhoven EJ, Bosch JL, et al. Stent placement for renal arterial stenosis: where do we stand? A meta-analysis. Radiology 2000;216:78-85.
700. van de Ven PJ, Kaatee R, Beutler JJ, et al. Arterial stenting and balloon angioplasty in ostial atherosclerotic renovascular disease: a randomised trial. Lancet 1999;353:282-6.
701. Leertouwer TC, Derkx FH, Pattynama PM, et al. Functional effects of renal artery stent placement on treated and contralateral kidneys. Kidney Int 2002;62:574-9.
702. Zeller T, Muller C, Frank U, et al. Stent angioplasty of severe atherosclerotic ostial renal artery stenosis in patients with diabetes mellitus and nephrosclerosis. Catheter Cardiovasc Interv 2003; 58:510-5.
703. Beregi JP, Elkohen M, Deklunder G, et al. Helical CT angiography compared with arteriography in the detection of renal artery stenosis. AJR Am J Roentgenol 1996;167:495-501.
704. Halpern EJ, Rutter CM, Gardiner GA Jr, et al. Comparison of Doppler US and CT angiography for evaluation of renal artery stenosis. Acad Radiol 1998;5:524-32.
705. Johnson PT, Halpern EJ, Kuszyk BS, et al. Renal artery stenosis: CT angiography—comparison of real-time volume-rendering and

maximum intensity projection algorithms. Radiology 1999; 211:337-43.
706. Kim TS, Chung JW, Park JH, et al. Renal artery evaluation: comparison of spiral CT angiography to intra-arterial DSA. J Vasc Interv Radiol 1998;9:553-9.
707. Rubin GD, Dake MD, Napel S, et al. Spiral CT of renal artery stenosis: comparison of three-dimensional rendering techniques. Radiology 1994;190:181-9.
708. Kawashima A, Sandler CM, Ernst RD, et al. CT evaluation of renovascular disease. Radiographics 2000;20:1321-40.
709. Lufft V, Hoogestraat-Lufft L, Fels LM, et al. Contrast media nephropathy: intravenous CT angiography versus intraarterial digital subtraction angiography in renal artery stenosis: a prospective randomized trial. Am J Kidney Dis 2002;40:236-42.
710. Saloner D. Determinants of image appearance in contrast-enhanced magnetic resonance angiography: a review. Invest Radiol 1998;33:488-95.
711. Leung DA, Hoffmann U, Pfammatter T, et al. Magnetic resonance angiography versus duplex sonography for diagnosing renovascular disease. Hypertension 1999;33:726-31.
712. Loubeyre P, Trolliet P, Cahen R, et al. MR angiography of renal artery stenosis: value of the combination of three-dimensional time-of-flight and three-dimensional phase-contrast MR angiography sequences. AJR Am J Roentgenol 1996;167:489-94.
713. Prince MR, Schoenberg SO, Ward JS, et al. Hemodynamically significant atherosclerotic renal artery stenosis: MR angiographic features. Radiology 1997;205:128-36.
714. Hany TF, Debatin JF, Leung DA, et al. Evaluation of the aortoiliac and renal arteries: comparison of breath-hold, contrast-enhanced, three-dimensional MR angiography with conventional catheter angiography. Radiology 1997;204:357-62.
715. Sueyoshi E, Sakamoto I, Matsuoka Y, et al. Aortoiliac and lower extremity arteries: comparison of three-dimensional dynamic contrast-enhanced subtraction MR angiography and conventional angiography. Radiology 1999;210:683-8.
716. Tan KT, van Beek EJ, Brown PW, et al. Magnetic resonance angiography for the diagnosis of renal artery stenosis: a meta-analysis. Clin Radiol 2002;57:617-24.
717. Mitsuzaki K, Yamashita Y, Sakaguchi T, et al. Abdomen, pelvis, and extremities: diagnostic accuracy of dynamic contrast-enhanced turbo MR angiography compared with conventional angiography-initial experience. Radiology 2000;216:909-15.
717a. Rihal, CS, Textor SC, Grill DE, et al. Incidence and prognostic importance of acute renal failure after percutaneous coronary intervention. Circulation 2002;105:2259-64.
717b. Parfrey PS, Griffiths SM, Barrett BJ, et al. Contrast material-induced renal failure in patients with diabetes mellitus, renal insufficiency, or both. A prospective controlled study. N Engl J Med 1989;320:143-9.
718. Rundback JH, Sacks D, Kent KC, et al. Guidelines for the reporting of renal artery revascularization in clinical trials. American Heart Association. Circulation 2002;106:1572-85.
719. Leertouwer TC, Pattynama PM, van den Berg-Huysmans A. Incidental renal artery stenosis in peripheral vascular disease: a case for treatment? Kidney Int 2001;59:1480-3.
720. Rihal CS, Textor SC, Breen JF, et al. Incidental renal artery stenosis among a prospective cohort of hypertensive patients undergoing coronary angiography. Mayo Clin Proc 2002;77:309-16.
721. Rossi GP, Cesari M, Chiesura-Corona M, et al. Renal vein renin measurements accurately identify renovascular hypertension caused by total occlusion of the renal artery. J Hypertens 2002;20:975-84.
722. Hughes JS, Dove HG, Gifford RW Jr, et al. Duration of blood pressure elevation in accurately predicting surgical cure of renovascular hypertension. Am Heart J 1981;101:408-13.
723. Maxwell MH, Rudnick MR, Waks AU. New approaches to the diagnosis of renovascular hypertension. Adv Nephrol Necker Hosp 1985;14:285-304.
724. Plouin PF, Chatellier G, Darne B, et al. Blood pressure outcome of angioplasty in atherosclerotic renal artery stenosis: a randomized trial. Essai Multicentrique Medicaments vs Angioplastie (EMMA) Study Group. Hypertension 1998;31:823-9.
725. Webster J, Marshall F, Abdalla M, et al. Randomised comparison of percutaneous angioplasty vs continued medical therapy for hypertensive patients with atheromatous renal artery stenosis. Scottish and Newcastle Renal Artery Stenosis Collaborative Group. J Hum Hypertens 1998;12:329-35.
726. Nordmann AJ, Woo K, Parkes R, et al. Balloon angioplasty or medical therapy for hypertensive patients with atherosclerotic renal artery stenosis? A meta-analysis of randomized controlled trials. Am J Med 2003;114:44-50.
727. Plouin PF. Stable patients with atherosclerotic renal artery stenosis should be treated first with medical management. Am J Kidney Dis 2003;42:851-7.
728. Hollenberg NK. Medical therapy of renovascular hypertension: efficacy and safety of captopril in 269 patients. Cardiovasc Rev Repl 1983;4:852-76.
729. Vetrovec GW, Landwehr DM, Edwards VL. Incidence of renal artery stenosis in hypertensive patients undergoing coronary angiography. J Interv Cardiol 1989;2:69-76.
730. Conlon PJ, Little MA, Pieper K, et al. Severity of renal vascular disease predicts mortality in patients undergoing coronary angiography. Kidney Int 2001;60:1490-7.
731. Weibull H, Bergqvist D, Bergentz SE, et al. Percutaneous transluminal renal angioplasty versus surgical reconstruction of atherosclerotic renal artery stenosis: a prospective randomized study. J Vasc Surg 1993;18:841-50; discussion 850-2.
732. van Jaarsveld BC, Krijnen P, Pieterman H, et al. The effect of balloon angioplasty on hypertension in atherosclerotic renal-artery stenosis. Dutch Renal Artery Stenosis Intervention Cooperative Study Group. N Engl J Med 2000;342:1007-14.
733. Blum U, Krumme B, Flugel P, et al. Treatment of ostial renal-artery stenoses with vascular endoprostheses after unsuccessful balloon angioplasty. N Engl J Med 1997;336:459-65.
734. Tuttle KR, Chouinard RF, Webber JT, et al. Treatment of atherosclerotic ostial renal artery stenosis with the intravascular stent. Am J Kidney Dis 1998;32:611-22.
735. Henry M, Amor M, Henry I, et al. Stents in the treatment of renal artery stenosis: long-term follow-up. J Endovasc Surg 1999;6:42-51.
736. Rocha-Singh KJ, Mishkel GJ, Katholi RE, et al. Clinical predictors of improved long-term blood pressure control after successful stenting of hypertensive patients with obstructive renal artery atherosclerosis. Catheter Cardiovasc Interv 1999;47:167-72.
737. Dorros G, Jaff M, Jain A, et al. Follow-up of primary Palmaz-Schatz stent placement for atherosclerotic renal artery stenosis. Am J Cardiol 1995;75:1051-5.
738. White CJ, Ramee SR, Collins TJ, et al. Renal artery stent placement: utility in lesions difficult to treat with balloon angioplasty. J Am Coll Cardiol 1997;30:1445-50.
739. Lederman RJ, Mendelsohn FO, Santos R, et al. Primary renal artery stenting: characteristics and outcomes after 363 procedures. Am Heart J 2001;142:314-23.
740. Harjai K, Khosla S, Shaw D, et al. Effect of gender on outcomes following renal artery stent placement for renovascular hyperten-

sion. Cathet Cardiovasc Diagn 1997;42:381-6.
741. Bloch MJ, Trost DA, Whitmer J, et al. Ostial renal artery stent placement in patients 75 years of age or older. Am J Hypertens 2001;14:983-8.
742. Tuttle KR. Ischemic nephropathy. Curr Opin Nephrol Hypertens 2001;10:167-73.
743. Tuttle KR. Toward more rational management of ischemic nephropathy: the need for clinical evidence. Am J Kidney Dis 2000;36:863-5.
744. Airoldi F, Palatresi S, Marana I, et al. Angioplasty of atherosclerotic and fibromuscular renal artery stenosis: time course and predicting factors of the effects on renal function. Am J Hypertens 2000;13:1210-7.
745. Losinno F, Zuccala A, Busato F, et al. Renal artery angioplasty for renovascular hypertension and preservation of renal function: long-term angiographic and clinical follow-up. AJR Am J Roentgenol 1994;162:853-7.
746. Geroulakos G, Abel P. Effect of renal-artery stenting on progression of renovascular renal failure. Lancet 1997;349(9068):1840.
747. Dorros G, Jaff M, Mathiak L, et al. Multicenter Palmaz stent renal artery stenosis revascularization registry report: four-year follow-up of 1,058 successful patients. Catheter Cardiovasc Interv 2002;55:182-8.
748. Ying CY, Tifft CP, Gavras H, et al. Renal revascularization in the azotemic hypertensive patient resistant to therapy. N Engl J Med 1984;311:1070-5.
749. Hirshberg B, Sasson T, Grinblat I, et al. Prolonged renal dysfunction secondary to renal-artery stenosis in the elderly—it is never too late. Nephrol Dial Transplant 1998;13:982-4.
750. Harden PN, MacLeod MJ, Rodger RS, et al. Effect of renal-artery stenting on progression of renovascular renal failure. Lancet 1997;349:1133-6.
751. Watson PS, Hadjipetrou P, Cox SV, et al. Effect of renal artery stenting on renal function and size in patients with atherosclerotic renovascular disease. Circulation 2000;102:1671-7.
752. Rocha-Singh KJ, Ahuja RK, Sung CH, et al. Long-term renal function preservation after renal artery stenting in patients with progressive ischemic nephropathy. Catheter Cardiovasc Interv 2002;57:135-41.
752a. Muray S, Martin M, Amoedo ML, et al. Rapid decline in renal function reflects reversibility and predicts the outcome after angioplasty in renal artery stenosis. Am J Kidney Dis 2002;39:60-6.
752b. Beutler JJ, Van Ampting JM, van de Ven PJ, et al. Long-term effects of arterial stenting on kidney function for patients with ostial atherosclerotic renal artery stenosis and renal insufficiency. J Am Soc Nephrol 2001;12: 1475-81.
753. Krishnamurthi V, Novick AC, Myles JL. Atheroembolic renal disease: effect on morbidity and survival after revascularization for atherosclerotic renal artery stenosis. J Urol 1999;161:1093-6.
754. Scolari F, Tardanico R, Zani R, et al. Cholesterol crystal embolism: a recognizable cause of renal disease. Am J Kidney Dis 2000;36:1089-109.
755. Henry M, Klonaris C, Henry I, et al. Protected renal stenting with the PercuSurge GuardWire device: a pilot study. J Endovasc Ther 2001;8:227-37.
756. Pickering TG, Herman L, Devereux RB, et al. Recurrent pulmonary oedema in hypertension due to bilateral renal artery stenosis: treatment by angioplasty or surgical revascularisation. Lancet 1988;2:551-2.
757. Messina LM, Zelenock GB, Yao KA, et al. Renal revascularization for recurrent pulmonary edema in patients with poorly controlled hypertension and renal insufficiency: a distinct subgroup of patients with arteriosclerotic renal artery occlusive disease. J Vasc Surg 1992;15:73-80; discussion 80-2.
758. Weatherford DA, Freeman MB, Regester RF, et al. Surgical management of flash pulmonary edema secondary to renovascular hypertension. Surg Gynecol Obstet 1997;174:160-3.
759. Mansoor S, Shah A, Scoble JE. 'Flash pulmonary oedema'—a diagnosis for both the cardiologist and the nephrologist? Nephrol Dial Transplant 2001;16:1311-3.
760. Planken II, Rietveld AP. Rapid onset pulmonary edema (flash edema) in renal artery stenosis. Neth J Med 1998;52:116-9.
761. Gray BH, Olin JW, Childs MB, et al. Clinical benefit of renal artery angioplasty with stenting for the control of recurrent and refractory congestive heart failure. Vasc Med 2002;7:275-9.
762. Azizi M, Lavergne T, Day M, et al. Renal artery stenosis and congestive heart failure. Lancet 1993;342(8866):302.
763. Missouris CG, Buckenham T, Vallance PJ, et al. Renal artery stenosis masquerading as congestive heart failure. Lancet 1993; 341:1521-2.
764. Tami LF, McElderry MW, al-Adli NM, et al. Renal artery stenosis presenting as crescendo angina pectoris. Cathet Cardiovasc Diagn 1995;35:252-6.
765. Gross CM, Kramer J, Waigand J, et al. Ostial renal artery stent placement for atherosclerotic renal artery stenosis in patients with coronary artery disease. Cathet Cardiovasc Diagn 1998;45:1-8.
766. Bloch MJ, Trost DW, Pickering TG, et al. Prevention of recurrent pulmonary edema in patients with bilateral renovascular disease through renal artery stent placement. Am J Hypertens 1999;12(1 pt 1):1-7.
767. Khosla S, White CJ, Collins TJ, et al. Effects of renal artery stent implantation in patients with renovascular hypertension presenting with unstable angina or congestive heart failure. Am J Cardiol 1997;80:363-6.
768. Tegtmeyer CJ, Selby JB, Hartwell GD, et al. Results and complications of angioplasty in fibromuscular disease. Circulation 1991;83(2 suppl):I155-61.
769. Brawn LA, Ramsay LE. Is "improvement" real with percutaneous transluminal angioplasty in the management of renovascular hypertension? Lancet 1987;2:1313-6.
770. Cicuto KP, McLean GK, Oleaga JA, et al. Renal artery stenosis: anatomic classification for percutaneous transluminal angioplasty. AJR Am J Roentgenol 1981;137:599-601.
771. Ramsay LE, Waller PC. Blood pressure response to percutaneous transluminal angioplasty for renovascular hypertension: an overview of published series. BMJ 1990;300:569-72.
772. Ives NJ, Wheatley K, Stowe RL, et al. Continuing uncertainty about the value of percutaneous revascularization in atherosclerotic renovascular disease: a meta-analysis of randomized trials. Nephrol Dial Transplant 2003;18:298-304.
773. Sos TA, Pickering TG, Sniderman K, et al. Percutaneous transluminal renal angioplasty in renovascular hypertension due to atheroma or fibromuscular dysplasia. N Engl J Med 1983; 309:274-9.
774. Libertino JA, Beckmann CF. Surgery and percutaneous angioplasty in the management of renovascular hypertension. Urol Clin North Am 1994;21:235-43.
775. Canzanello VJ, Millan VG, Spiegel JE, et al. Percutaneous transluminal renal angioplasty in management of atherosclerotic renovascular hypertension: results in 100 patients. Hypertension 1989;13:163-72.
776. Klinge J, Mali WP, Puijlaert CB, et al. Percutaneous transluminal renal angioplasty: initial and long-term results. Radiology 1989;171:501-6.

777. Plouin PF, Darne B, Chatellier G, et al. Restenosis after a first percutaneous transluminal renal angioplasty. Hypertension 1993;21:89-96.
778. Martin LG, Cork RD, Kaufman SL. Long-term results of angioplasty in 110 patients with renal artery stenosis. J Vasc Interv Radiol 1992;3:619-26.
779. Dorros G, Prince C, Mathiak L. Stenting of a renal artery stenosis achieves better relief of the obstructive lesion than balloon angioplasty. Cathet Cardiovasc Diagn 1993;29:191-8.
780. Isles CG, Robertson S, Hill D. Management of renovascular disease: a review of renal artery stenting in ten studies. QJM 1999;92:159-67.
781. Stanley JC. The evolution of surgery for renovascular occlusive disease. Cardiovasc Surg 1994;2:195-202.
782. Stanley JC. David M. Hume memorial lecture. Surgical treatment of renovascular hypertension. Surg Gynecol Obstet 1997;174: 102-10.
783. van Bockel JH, van Schilfgaarde R, Felthuis W, et al. Long-term results of in situ and extracorporeal surgery for renovascular hypertension caused by fibrodysplasia. J Vasc Surg 1987;6:355-64.
784. Stanley JC, Ernst CB, Fry WJ. Fate of 100 aortorenal vein grafts: characteristics of late graft expansion, aneurysmal dilatation, and stenosis. Surgery 1973;74:931-44.
785. Khauli RB, Novick AC, Ziegelbaum M. Splenorenal bypass in the treatment of renal artery stenosis: experience with sixty-nine cases. J Vasc Surg 1985;2:547-51.
786. Stanley JC, Fry WJ. Renovascular hypertension secondary to arterial fibrodysplasia in adults: criteria for operation and results of surgical therapy. Arch Surg 1975;110:922-8.
787. Novick AC, Straffon RA, Stewart BH, et al. Surgical treatment of renovascular hypertension in the pediatric patient. J Urol 1978; 119:794-9.
788. Berkowitz HD, O'Neill JA Jr. Renovascular hypertension in children. Surgical repair with special reference to the use of reinforced vein grafts. J Vasc Surg 1989;9:46-55.
789. Palmaz JC. The current status of vascular intervention in ischemic nephropathy. J Vasc Interv Radiol 1998;9:539-43.
790. Martin LG, Rees CR, O'Bryant T. Percutaneous angioplasty of the renal arteries. In: Rutherford RB, ed. Vascular Surgery 5th ed. Philadelphia, Pa: WB Saunders; 2000:1611-39.
791. Slonim SM, Dake MD. Radiographic evaluation and treatment of renovascular disease. In: Strandness DE Jr, VanBreda A, eds. Surgical & Interventional Therapy. New York: Churchill Livingstone; 1994:721-41.
792. Hansen KJ, Thomason RB, Craven TE, et al. Surgical management of dialysis-dependent ischemic nephropathy. J Vasc Surg 1995;21:197-209; discussion 209-11.
793. Hansen KJ, Starr SM, Sands RE, et al. Contemporary surgical management of renovascular disease. J Vasc Surg 1992;16:319-30; discussion 330-1.
794. Wong JM, Hansen KJ, Oskin TC, et al. Surgery after failed percutaneous renal artery angioplasty. J Vasc Surg 1999;30:468-82.
795. Cambria RP, Brewster DC, L'Italien G, et al. Simultaneous aortic and renal artery reconstruction: evolution of an eighteen-year experience. J Vasc Surg 1995;21:916-24; discussion 925.
796. Dougherty MJ, Hallett JW Jr, Naessens J, et al. Renal endarterectomy vs. bypass for combined aortic and renal reconstruction: is there a difference in clinical outcome? Ann Vasc Surg 1995;9:87-94.
797. Stoney RJ, Messina LM, Goldstone J, et al. Renal endarterectomy through the transected aorta: a new technique for combined aortorenal atherosclerosis—a preliminary report. J Vasc Surg 1989; 9:224-33. Erratum in: J Vasc Surg 1989;10:19.
798. Stanley JC, Whitehouse WM Jr, Zelenock GB, et al. Reoperation for complications of renal artery reconstructive surgery undertaken for treatment of renovascular hypertension. J Vasc Surg 1985;2:133-44.
799. Hansen KJ, Deitch JS, Oskin TC, et al. Renal artery repair: consequence of operative failures. Ann Surg 1998;227:678-89; discussion 689-90.
800. Whitehouse WM Jr, Kazmers A, Zelenock GB, et al. Chronic total renal artery occlusion: effects of treatment on secondary hypertension and renal function. Surgery 1981;89:753-63.
801. Oskin TC, Hansen KJ, Deitch JS, et al. Chronic renal artery occlusion: nephrectomy versus revascularization. J Vasc Surg 1999; 29:140-9.
802. Novick AC. Surgical correction of renovascular hypertension. Surg Clin North Am 1988;68:1007-25.
803. Cambria RP, Brewster DC, L'Italien GJ, et al. The durability of different reconstructive techniques for atherosclerotic renal artery disease. J Vasc Surg 1994;20:76-85; discussion 86-7.
804. Novick AC, Ziegelbaum M, Vidt DG, et al. Trends in surgical revascularization for renal artery disease: ten years' experience. JAMA 1987;257:498-501.
805. Libertino JA, Bosco PJ, Ying CY, et al. Renal revascularization to preserve and restore renal function. J Urol 1992;147:1485-7.
806. Clair DG, Belkin M, Whittemore AD, et al. Safety and efficacy of transaortic renal endarterectomy as an adjunct to aortic surgery. J Vasc Surg 1995;21:926-33; discussion 934.
807. Xue F, Bettmann MA, Langdon DR, et al. Outcome and cost comparison of percutaneous transluminal renal angioplasty, renal arterial stent placement, and renal arterial bypass grafting. Radiology 1999;212:378-84.
808. Ottinger LW, Austen WG. A study of 136 patients with mesenteric infarction. Surg Gynecol Obstet 1967;124:251-61.
809. Hertzer NR, Beven EG, Humphries AW. Acute intestinal ischemia. Am Surg 1978;44:744-9.
810. Bergan JJ. Recognition and treatment of intestinal ischemia. Surg Clin North Am 1967;47:109-26.
811. Krupski WC, Effeney DJ, Ehrenfeld WK. Spontaneous dissection of the superior mesenteric artery. J Vasc Surg 1985;2:731-4.
812. Wolf EA Jr, Sumner DS, Strandness DE Jr. Disease of the mesenteric circulation in patients with thromboangiitis obliterans. Vasc Surg 1972;6:218-23.
813. Slater H, Elliott DW. Primary mesenteric infarction. Surg Gynecol Obstet 1972;123:309-11.
814. Singh RP, Shah RC, Lee ST. Acute mesenteric vascular occlusion: a review of thirty-two patients. Surgery 1975;78:613-7.
815. Smith JS Jr, Patterson LT. Acute mesenteric infarction. Am Surg 1976;42:562-7.
816. Kairaluoma MI, Karkola P, Heikkinen D, et al. Mesenteric infarction. Surg Gynecol Obstet 1977;133:188-93.
817. Sachs SM, Morton JH, Schwartz SI. Acute mesenteric ischemia. Surgery 1982;92:646-53.
818. Levy PJ, Krausz MM, Manny J. Acute mesenteric ischemia: improved results—a retrospective analysis of ninety-two patients. Surgery 1990;107:372-80.
819. Bulkley GB, Zuidema GD, Hamilton SR, et al. Intraoperative determination of small intestinal viability following ischemic injury: a prospective, controlled trial of two adjuvant methods (Doppler and fluorescein) compared with standard clinical judgment. Ann Surg 1981;193:628-37.
820. Gallego AM, Ramirez P, Rodriguez JM, et al. Role of urokinase in the superior mesenteric artery embolism. Surgery 1996; 120:111-3.

821. McBride KD, Gaines PA. Thrombolysis of a partially occluding superior mesenteric artery thromboembolus by infusion of streptokinase. Cardiovasc Intervent Radiol 1994;17:164-6.
822. Schoenbaum SW, Pena C, Koenigsberg P, et al. Superior mesenteric artery embolism: treatment with intraarterial urokinase. J Vasc Interv Radiol 1992;3:485-90.
823. Boley SJ, Sprayregan S, Siegelman SS, et al. Initial results from an aggressive roentgenological and surgical approach to acute mesenteric ischemia. Surgery 1977;82:848-55.
824. Kawauchi M, Tada Y, Asano K, et al. Angiographic demonstration of mesenteric arterial changes in postcoarctectomy syndrome. Surgery 1985;98:602-4.
825. Gewertz BL, Zarins CK. Postoperative vasospasm after antegrade mesenteric revascularization: a report of three cases. J Vasc Surg 1991;14:382-5.
826. Siegelman SS, Sprayregen S, Boley SJ. Angiographic diagnosis of mesenteric arterial vasoconstriction. Radiology 1974;112:533-42.
827. Ende N. Infarction of the bowel in cardiac failure. N Engl J Med 1958;258:879-81.
828. Greene FL, Ariyan S, Stansel HC Jr. Mesenteric and peripheral vascular ischemia secondary to ergotism. Surgery 1977;81:176-9.
829. Nalbandian H, Sheth N, Dietrich R, et al. Intestinal ischemia caused by cocaine ingestion: report of two cases. Surgery 1985;97:374-6.
830. Cheatham JE Jr, Williams GR, Thompson WM, et al. Coarctation: a review of 80 children and adolescents. Surg Gynecol Obstet 1979;138:889-93.
831. Merhoff GC, Porter JM. Ergot intoxication: historical review and description of unusual clinical manifestations. Ann Surg 1974;180:773-9.
832. Fisher DF Jr, Fry WJ. Collateral mesenteric circulation. Surg Gynecol Obstet 1987;164:487-92.
833. Mikkelsen WP. Intestinal angina: its surgical significance. Surg Gynecol Obstet 1957;94:262-7; discussion, 267-9.
834. Buchardt Hansen HJ. Abdominal angina: results of arterial reconstruction in 12 patients. Acta Chir Scand 1976;142:319-25.
835. Hollier LH, Bernatz PE, Pairolero PC, et al. Surgical management of chronic intestinal ischemia: a reappraisal. Surgery 1981;90:940-6.
836. Johnston KW, Lindsay TF, Walker PM, et al. Mesenteric arterial bypass grafts: early and late results and suggested surgical approach for chronic and acute mesenteric ischemia. Surgery 1995;118:1-7.
837. Moneta GL, Yeager RA, Dalman R, et al. Duplex ultrasound criteria for diagnosis of splanchnic artery stenosis or occlusion. J Vasc Surg 1991;14:511-8; discussion 518-20.
838. Moneta GL, Lee RW, Yeager RA, et al. Mesenteric duplex scanning: a blinded prospective study. J Vasc Surg 1993;17:79-84; discussion 85-6.
839. Zwolak RM, Fillinger MF, Walsh DB, et al. Mesenteric and celiac duplex scanning: a validation study. J Vasc Surg 1998;27:1078-87; discussion 1088.
840. Gentile AT, Moneta GL, Lee RW, et al. Usefulness of fasting and postprandial duplex ultrasound examinations for predicting high-grade superior mesenteric artery stenosis. Surg Gynecol Obstet 1995;169:476-9.
841. Thomas JH, Blake K, Pierce GE, et al. The clinical course of asymptomatic mesenteric arterial stenosis. J Vasc Surg 1998; 27:840-4.
842. Connolly JE, Stemmer EA. Intestinal gangrene as the result of mesenteric arterial steal. Surg Gynecol Obstet 1973;126:197-204.
843. Furrer J, Gruntzig A, Kugelmeier J, et al. Treatment of abdominal angina with percutaneous dilatation of an arteria mesenterica superior stenosis: preliminary communication. Cardiovasc Intervent Radiol 1980;3:43-4.
844. Golden DA, Ring EJ, McLean GK, et al. Percutaneous transluminal angioplasty in the treatment of abdominal angina. AJR Am J Roentgenol 1982;139:247-9.
845. Odurny A, Sniderman KW, Colapinto RF. Intestinal angina: percutaneous transluminal angioplasty of the celiac and superior mesenteric arteries. Radiology 1988;167:59-62.
846. Roberts L Jr, Wertman DA Jr, Mills SR, et al. Transluminal angioplasty of the superior mesenteric artery: an alternative to surgical revascularization. AJR Am J Roentgenol 1983;141:1039-42.
847. Levy PJ, Haskell L, Gordon RL. Percutaneous transluminal angioplasty of splanchnic arteries: an alternative method to elective revascularisation in chronic visceral ischaemia. Eur J Radiol 1987;7:239-42.
848. McShane MD, Proctor A, Spencer P, et al. Mesenteric angioplasty for chronic intestinal ischaemia. Eur J Vasc Surg 1992;6:333-6.
849. Allen RC, Martin GH, Rees CR, et al. Mesenteric angioplasty in the treatment of chronic intestinal ischemia. J Vasc Surg 1996;24:415-21; discussion 421-3.
850. Kasirajan K, O'Hara PJ, Gray BH, et al. Chronic mesenteric ischemia: open surgery versus percutaneous angioplasty and stenting. J Vasc Surg 2001;33:63-71.
850a. Rose SC, Quigley TM, Raker EJ. Revascularization for chronic mesenteric ischemia: comparison off operative arterial bypass grafting and percutaneous transluminal angioplasty. J Vasc Interv Radiol 1995;6:339-49.
850b. Bowser AN. Revascularization for chronic mesenteric ischemia: comparison of endovascular and open surgical intervention (Government Rep. No. CI02-4). University of South Florida, Jan. 17, 2002.
851. Jimenez JG, Huber TS, Ozaki CK, et al. Durability of antegrade synthetic aortomesenteric bypass for chronic mesenteric ischemia. J Vasc Surg 2002;35:1078-84. Erratum in: J Vasc Surg 2002;36:548.
852. Park WM, Cherry KJ Jr, Chua HK, et al. Current results of open revascularization for chronic mesenteric ischemia: a standard for comparison. J Vasc Surg 2002;35:853-9.
853. Cunningham CG, Reilly LM, Rapp JH, et al. Chronic visceral ischemia. Three decades of progress. Ann Surg 1991;214:276-87; discussion 287-8.
854. Kieny R, Batellier J, Kretz JG. Aortic reimplantation of the superior mesenteric artery for atherosclerotic lesions of the visceral arteries: sixty cases. Ann Vasc Surg 1990;4:122-5.
855. Foley MI, Moneta GL, Abou-Zamzam AM Jr, et al. Revascularization of the superior mesenteric artery alone for treatment of intestinal ischemia. J Vasc Surg 2000;32:37-47.
856. Beebe HG, MacFarlane S, Raker EJ. Supraceliac aortomesenteric bypass for intestinal ischemia. J Vasc Surg 1987;5:749-54.
857. Rapp JH, Reilly LM, Qvarfordt PG, et al. Durability of endarterectomy and antegrade grafts in the treatment of chronic visceral ischemia. J Vasc Surg 1986;3:799-806.
858. Moawad J, McKinsey JF, Wyble CW, et al. Current results of surgical therapy for chronic mesenteric ischemia. Arch Surg 1997;132:613-8; discussion 618-9.
859. Ebaugh JL, Garcia ND, Matsumura JS. Screening and surveillance for abdominal aortic aneurysms: who needs it and when. Semin Vasc Surg 2001;14:193-9.
860. Alcorn HG, Wolfson SK Jr, Sutton-Tyrrell K, et al. Risk factors for abdominal aortic aneurysms in older adults enrolled in The Cardiovascular Health Study. Arterioscler Thromb Vasc Biol

1996;16:963-70.
861. Pedersen OM, Aslaksen A, Vik-Mo H. Ultrasound measurement of the luminal diameter of the abdominal aorta and iliac arteries in patients without vascular disease. J Vasc Surg 1993;17:596-601.
862. Lanne T, Sandgren T, Sonesson B. A dynamic view on the diameter of abdominal aortic aneurysms. Eur J Vasc Endovasc Surg 1998;15:308-12.
863. Johnston KW, Rutherford RB, Tilson MD, et al. Suggested standards for reporting on arterial aneurysms. Subcommittee on Reporting Standards for Arterial Aneurysms, Ad Hoc Committee on Reporting Standards, Society for Vascular Surgery and North American Chapter, International Society for Cardiovascular Surgery J Vasc Surg 1991;13:452-8.
864. Pearce WH, Slaughter MS, LeMaire S, et al. Aortic diameter as a function of age, gender, and body surface area. Surgery 1993; 114:691-7.
865. Sandgren T, Sonesson B, Ahlgren AR, et al. Factors predicting the diameter of the popliteal artery in healthy humans. J Vasc Surg 1998;28:284-9.
866. Sonesson B, Lanne T, Hansen F, et al. Infrarenal aortic diameter in the healthy person. Eur J Vasc Surg 1994;8:89-95.
867. Lawrence-Brown MM, Norman PE, Jamrozik K, et al. Initial results of ultrasound screening for aneurysm of the abdominal aorta in Western Australia: relevance for endoluminal treatment of aneurysm disease. Cardiovasc Surg 2001;9:234-40.
868. Bengtsson H, Sonesson B, Bergqvist D. Incidence and prevalence of abdominal aortic aneurysms, estimated by necropsy studies and population screening by ultrasound. Ann N Y Acad Sci 1996;800:1-24.
869. Jamrozik K, Norman PE, Spencer CA, et al. Screening for abdominal aortic aneurysm: lessons from a population-based study. Med J Aust 2000;173:345-50.
870. Lederle FA, Johnson GR, Wilson SE, et al. The aneurysm detection and management study screening program: validation cohort and final results. Aneurysm Detection and Management Veterans Affairs Cooperative Study Investigators. Arch Intern Med 2000;160:1425-30.
871. Singh K, Bonaa KH, Jacobsen BK, et al. Prevalence of and risk factors for abdominal aortic aneurysms in a population-based study: the Tromso Study. Am J Epidemiol 2001;154:236-44.
872. Pleumeekers HJ, Hoes AW, van der Does E, et al. Aneurysms of the abdominal aorta in older adults. The Rotterdam Study. Am J Epidemiol 1995;142:1291-9.
873. Vazquez C, Sakalihasan N, D'Harcour JB, et al. Routine ultrasound screening for abdominal aortic aneurysm among 65- and 75-year-old men in a city of 200,000 inhabitants. Ann Vasc Surg 1998;12:544-9.
874. Boll AP, Verbeek AL, van de Lisdonk EH, et al. High prevalence of abdominal aortic aneurysm in a primary care screening programme. Br J Surg 1998;85:1090-4.
875. Wilmink AB, Quick CR. Epidemiology and potential for prevention of abdominal aortic aneurysm. Br J Surg 1998;85:155-62.
876. Takei H, Ishikawa S, Otaki A, et al. Screening for abdominal aortic aneurysm and occlusive peripheral vascular disease in Japanese residents. Surg Today 1995;25:608-11.
877. Adachi K, Iwasawa T, Ono T. Screening for abdominal aortic aneurysms during a basic medical checkup in residents of a Japanese rural community. Surg Today 2000;30:594-9.
878. Spark JI, Baker JL, Vowden P, et al. Epidemiology of abdominal aortic aneurysms in the Asian community. Br J Surg 2001;88:382-4.
879. Sandgren T, Sonesson B, Ryden-Ahlgren, Lanne T. Arterial dimensions in the lower extremities of patients with abdominal aortic aneurysms—no indications of a generalized dilating diathesis. J Vasc Surg 2001;34:1079-84.
880. Lawrence PF, Wallis C, Dobrin PB, et al. Peripheral aneurysms and arteriomegaly: is there a familial pattern? J Vasc Surg 1998;28:599-605.
881. Verloes A, Sakalihasan N, Koulischer L, et al. Aneurysms of the abdominal aorta: familial and genetic aspects in three hundred thirteen pedigrees. J Vasc Surg 1995;21:646-55.
882. Darling RC 3rd, Brewster DC, Darling RC, et al. Are familial abdominal aortic aneurysms different? J Vasc Surg 1989;10:39-43.
883. Webster MW, Ferrell RE, St Jean PL, et al. Ultrasound screening of first-degree relatives of patients with an abdominal aortic aneurysm. J Vasc Surg 1991;13:9-13; discussion 13-4.
884. Bengtsson H, Sonesson B, Lanne T, et al. Prevalence of abdominal aortic aneurysm in the offspring of patients dying from aneurysm rupture. Br J Surg 1992;79:1142-3.
885. Hirose H, Tilson MD. Abdominal aortic aneurysm as an autoimmune disease. Ann N Y Acad Sci 2001;947:416-8.
886. Lindholt JS, Jorgensen B, Fasting H, et al. Plasma levels of plasmin-antiplasmin-complexes are predictive for small abdominal aortic aneurysms expanding to operation-recommendable sizes. J Vasc Surg 2001;34:611-5.
887. Adams DC, Tulloh BR, Galloway SW, et al. Familial abdominal aortic aneurysm: prevalence and implications for screening. Eur J Vasc Surg 1993;7:709-12.
888. Fitzgerald P, Ramsbottom D, Burke P, et al. Abdominal aortic aneurysm in the Irish population: a familial screening study. Br J Surg 1995;82:483-6.
889. van der Graaf Y, Akkersdijk GJ, Hak E, et al. Results of aortic screening in the brothers of patients who had elective aortic aneurysm repair. Br J Surg 1998;85:778-80.
890. Jaakkola P, Kuivaniemi H, Partanen K, et al. Familial abdominal aortic aneurysms: screening of 71 families. Eur J Surg 1996;162:611-7.
891. Leier CV, Baker PB, Kilman JW, et al. Cardiovascular abnormalities associated with adult polycystic kidney disease. Ann Intern Med 1984;100:683-8.
892. Torra R, Nicolau C, Badenas C, et al. Abdominal aortic aneurysms and autosomal dominant polycystic kidney disease. J Am Soc Nephrol 1996;7:2483-6.
893. McConathy WJ, Alaupovic P, Woolcock N, et al. Lipids and apolipoprotein profiles in men with aneurysmal and stenosing aorto-iliac atherosclerosis. Eur J Vasc Surg 1989;3:511-4.
894. Schillinger M, Domanovits H, Ignatescu M, et al. Lipoprotein (a) in patients with aortic aneurysmal disease. J Vasc Surg 2002;36:25-30.
895. Simons PC, Algra A, Bots ML, et al. Common carotid intima-media thickness in patients with peripheral arterial disease or abdominal aortic aneurysm: the SMART study. Second Manifestations of ARTerial disease. Atherosclerosis 1999;146: 243-8.
896. Davies MJ. Aortic aneurysm formation: lessons from human studies and experimental models. Circulation 1998;98:193-5.
897. Goodall S, Porter KE, Bell PR, et al. Enhanced invasive properties exhibited by smooth muscle cells are associated with elevated production of MMP-2 in patients with aortic aneurysms. Eur J Vasc Endovasc Surg 2002;24:72-80.
898. Reilly JM, Brophy CM, Tilson MD. Characterization of an elastase from aneurysmal aorta which degrades intact aortic elastin. Ann Vasc Surg 1992;6:499-502.
899. Anidjar S, Dobrin PB, Eichorst M, et al. Correlation of inflammatory infiltrate with the enlargement of experimental aortic

aneurysms. J Vasc Surg 1992;16:139-47.
900. Pearce WH, Koch AE. Cellular components and features of immune response in abdominal aortic aneurysms. Ann N Y Acad Sci 1996;800:175-85.
901. Louwrens HD, Kwaan HC, Pearce WH, et al. Plasminogen activator and plasminogen activator inhibitor expression by normal and aneurysmal human aortic smooth muscle cells in culture. Eur J Vasc Endovasc Surg 1995;10:289-93.
902. Sakamaki F, Oya H, Nagaya N, et al. Higher prevalence of obstructive airway disease in patients with thoracic or abdominal aortic aneurysm. J Vasc Surg 2002;36:35-40.
903. Lindholt JS, Heickendorff L, Antonsen S, et al. Natural history of abdominal aortic aneurysm with and without coexisting chronic obstructive pulmonary disease. J Vasc Surg 1998;28:226-33.
904. Yajima N, Masuda M, Miyazaki M, et al. Oxidative stress is involved in the development of experimental abdominal aortic aneurysm: a study of the transcription profile with complementary DNA microarray. J Vasc Surg 2002;36:379-85.
905. Baxter BT, Pearce WH, Waltke EA, et al. Prolonged administration of doxycycline in patients with small asymptomatic abdominal aortic aneurysms: report of a prospective (Phase II) multicenter study. J Vasc Surg 2002;36:1-12.
906. Nagashima H, Aoka Y, Sakomura Y, et al. A 3-hydroxy-3-methylglutaryl coenzyme A reductase inhibitor, cerivastatin, suppresses production of matrix metalloproteinase-9 in human abdominal aortic aneurysm wall. J Vasc Surg 2002;36:158-63.
907. Gsell O. Wandnekrosen der Aorta als selbständige Erkrankung und ihre Beziehung zur Spontanruptur. Virchows Arch Pathol Anat Physiol Klin Med 1928:1-36.
908. Erdheim J. Medionecrosis aortae idiopathica (cystica). Virchows Arch Pathol Anat Physiol Klin Med 1929:454-79.
909. Marfan AB. Un cas de déformation congénital des quatre membres plus prononcée aux extrémitiés caractérisée par l'allongement des os avec un certain degré d'amincissement. Bull Mém Soc Méd Hôp 1896;13:220-6.
910. Jondeau G, Delorme G, Guiti C. [Marfan syndrome] Rev Prat. 2002;52:1089-93.
911. Hollister DW, Godfrey M, Sakai LY, et al. Immunohistologic abnormalities of the microfibrillar-fiber system in the Marfan syndrome. N Engl J Med 1990;323:152-9.
912. Dietz HC, Cutting GR, Pyeritz RE, et al. Marfan syndrome caused by a recurrent de novo missense mutation in the fibrillin gene. Nature 1991;352:337-9.
913. Lee B, Godfrey M, Vitale E, et al. Linkage of Marfan syndrome and a phenotypically related disorder to two different fibrillin genes. Nature 1991;352:330-4.
914. Tsipouras P, Del Mastro R, Sarfarazi M, et al. Genetic linkage of the Marfan syndrome, ectopia lentis, and congenital contractural arachnodactyly to the fibrillin genes on chromosomes 15 and 5. The International Marfan Syndrome Collaborative Study. N Engl J Med 1992;326:905-9.
915. Francke U, Furthmayr H. Marfan's syndrome and other disorders of fibrillin. N Engl J Med 1994;330:1384-5.
916. Kainulainen K, Savolainen A, Palotie A, et al. Marfan syndrome: exclusion of genetic linkage to five genes coding for connective tissue components in the long arm of chromosome 2. Hum Genet 1990;84:233-6.
917. Maslen CL, Corson GM, Maddox BK, et al. Partial sequence of a candidate gene for the Marfan syndrome. Nature 1991;352:334-7.
918. Jeremy RW, Huang H, Hwa J, et al. Relation between age, arterial distensibility, and aortic dilatation in the Marfan syndrome. Am J Cardiol 1994;74:369-73.
919. Pepin M, Schwarze U, Superti-Furga A, et al. Clinical and genetic features of Ehlers-Danlos syndrome type IV, the vascular type. N Engl J Med 2000;342:673-80. Erratum in: N Engl J Med 2001;344:392.
920. Francke U, Berg MA, Tynan K, et al. A Gly1127Ser mutation in an EGF-like domain of the fibrillin-1 gene is a risk factor for ascending aortic aneurysm and dissection. Am J Hum Genet 1995;56:1287-96.
921. Rasmussen TE, Hallett JW Jr. Inflammatory aortic aneurysms: a clinical review with new perspectives in pathogenesis. Ann Surg 1997;225:155-64.
922. Bonamigo TP, Bianco C, Becker M, et al. Inflammatory aneurysms of infra-renal abdominal aorta: a case-control study. Minerva Cardioangiol 2002;50:253-8.
923. Cavallaro A, Sapienza P, di Marzo L, et al. [Inflammatory aneurysm of the abdominal aorta: study of 355 patients with aortic aneurysm] Recenti Prog Med 2001;92:269-73. Italian.
924. Pennell RC, Hollier LH, Lie JT, et al. Inflammatory abdominal aortic aneurysms: a thirty-year J Vasc Surg 1985;2:859-69.
925. Munshi IA, Rhee SW, Pane T, et al. Clostridium septicum mycotic aortic aneurysm. Surg Gynecol Obstet 2002;184:54-5.
926. Fiessinger JN, Paul JF. [Inflammatory and infectious aortitis] Rev Prat. 2002;52:1094-9.
927. Hagino RT, Clagett GP, Valentine RJ. A case of Pott's disease of the spine eroding into the suprarenal aorta. J Vasc Surg 1996;24:482-6.
928. Vammen S, Vorum H, Ostergaard L, et al. Immunoblotting analysis of abdominal aortic aneurysms using antibodies against Chlamydia pneumoniae recombinant MOMP. Eur J Vasc Endovasc Surg 2002;24:81-5.
929. Loehe F, Bittmann I, Weilbach C, et al. Chlamydia pneumoniae in atherosclerotic lesions of patients undergoing vascular surgery. Ann Vasc Surg 2002;16:467-73.
930. Vammen S, Lindholt JS, Ostergaard L, et al. Randomized double-blind controlled trial of roxithromycin for prevention of abdominal aortic aneurysm expansion. Br J Surg 2001;88:1066-72. Erratum in: Br J Surg 2002;89:120-1.
931. Bengtsson H, Nilsson P, Bergqvist D. Natural history of abdominal aortic aneurysm detected by screening. Br J Surg 1993; 80:718-20.
932. Englund R, Hudson P, Hanel K, et al. Expansion rates of small abdominal aortic aneurysms. Aust N Z J Surg 1998;68:21-4.
933. Grimshaw GM, Thompson JM, Hamer JD. A statistical analysis of the growth of small abdominal aortic aneurysms. Eur J Vasc Surg 1994;8:741-6.
934. Santilli SM, Littooy FN, Cambria RA, et al. Expansion rates and outcomes for the 3.0-cm to the 3.9-cm infrarenal abdominal aortic aneurysm. J Vasc Surg 2002;35:666-71.
935. Nevitt MP, Ballard DJ, Hallett JW Jr. Prognosis of abdominal aortic aneurysms. A population-based study. N Engl J Med 1989; 321:1009-14.
936. Cronenwett JL, Sargent SK, Wall MH, et al. Variables that affect the expansion rate and outcome of small abdominal aortic aneurysms. J Vasc Surg 1990;11:260-8; discussion 268-9.
937. Bengtsson H, Bergqvist D, Ekberg O, et al. Expansion pattern and risk of rupture of abdominal aortic aneurysms that were not operated on. Eur J Surg 1993;159:461-7.
938. Taylor LM Jr, Porter JM. Basic data related to clinical decision-making in abdominal aortic aneurysms. Ann Vasc Surg 1987;1:502-4.
939. Hollier LH, Taylor LM, Ochsner J. Recommended indications for operative treatment of abdominal aortic aneurysms: report of a

subcommittee of the Joint Council of the Society for Vascular Surgery and the North American Chapter of the International Society for Cardiovascular Surgery J Vasc Surg 1992;15:1046-56.
940. Hallin A, Bergqvist D, Holmberg L. Literature review of surgical management of abdominal aortic aneurysm. Eur J Vasc Endovasc Surg 2001;22:197-204.
941. Lederle FA, Wilson SE, Johnson GR, et al. Immediate repair compared with surveillance of small abdominal aortic aneurysms. N Engl J Med 2002;346:1437-44.
942. Mealy K, Salman A. The true incidence of ruptured abdominal aortic aneurysms. Eur J Vasc Surg 1988;2:405-8.
943. Johansen K, Kohler TR, Nicholls SC, et al. Ruptured abdominal aortic aneurysm: the Harborview experience. J Vasc Surg 1991;13:240-5; discussion 245-7.
944. Heikkinen M, Salenius J, Zeitlin R, et al. The fate of AAA patients referred electively to vascular surgical unit. Scand J Surg 2002;91:345-52.
945. Szilagyi DE, Smith RF, DeRusso FJ, et al. Contribution of abdominal aortic aneurysmectomy to prolongation of life. Ann Surg 1966;164:678-99.
946. Cronenwett JL, Murphy TF, Zelenock GB, et al. Actuarial analysis of variables associated with rupture of small abdominal aortic aneurysms. Surgery 1985;98:472-83.
947. Powell JT, Brown LC. The natural history of abdominal aortic aneurysms and their risk of rupture. Acta Chir Belg 2001;101:11-6.
948. Chang JB, Stein TA, Liu JP, et al. Risk factors associated with rapid growth of small abdominal aortic aneurysms. Surgery 1997;121:117-22.
949. Axelrod DA, Henke PK, Wakefield TW, et al. Impact of chronic obstructive pulmonary disease on elective and emergency abdominal aortic aneurysm repair. J Vasc Surg 2001;33:72-6.
950. Conway KP, Byrne J, Townsend M, et al. Prognosis of patients turned down for conventional abdominal aortic aneurysm repair in the endovascular and sonographic era: Szilagyi revisited? J Vasc Surg 2001;33:752-7.
951. Watson CJ, Walton J, Shaw E, et al. What is the long-term outcome for patients with very small abdominal aortic aneurysms? Eur J Vasc Endovasc Surg 1997;14:299-304.
952. Brown PM, Pattenden R, Gutelius JR. The selective management of small abdominal aortic aneurysms: the Kingston study. J Vasc Surg 1992;15:21-5; discussion 25-7.
953. Scott RA, Tisi PV, Ashton HA, et al. Abdominal aortic aneurysm rupture rates: a 7-year follow-up of the entire abdominal aortic aneurysm population detected by screening. J Vasc Surg 1998; 28:124-8.
954. Katz DA, Littenberg B, Cronenwett JL. Management of small abdominal aortic aneurysms: early surgery vs watchful waiting. JAMA 1992;268:2678-86.
955. Hertzer NR, Young JR, Beven EG, et al. Late results of coronary bypass in patients with infrarenal aortic aneurysms. The Cleveland Clinic Study. Ann Surg 1987;205:360-7.
956. Perko MJ, Schroeder TV, Olsen PS, et al. Natural history of abdominal aortic aneurysm: a survey of 63 patients treated nonoperatively. Ann Vasc Surg 1993;7:113-6.
957. Galland RB, Whiteley MS, Magee TR. The fate of patients undergoing surveillance of small abdominal aortic aneurysms. Eur J Vasc Endovasc Surg 1998;16:104-9.
958. Jones L, Pressdee DJ, Lamont PM, et al. A phase contrast (PC) rephase/dephase sequence of magnetic resonance angiography (MRA): a new technique for imaging distal run-off in the preoperative evaluation of peripheral vascular disease. Clin Radiol 1998;53:333-7.
959. Biancari F, Ylonen K, Anttila V, et al. Durability of open repair of infrarenal abdominal aortic aneurysm: a 15-year follow-up study. J Vasc Surg 2002;35:87-93.
960. Mortality results for randomised controlled trial of early elective surgery or ultrasonographic surveillance for small abdominal aortic aneurysms. The UK Small Aneurysm Trial Participants. Lancet 1998;352:1649-55.
961. Brown LC, Powell JT. Risk factors for aneurysm rupture in patients kept under ultrasound surveillance. UK Small Aneurysm Trial Participants. Ann Surg 1999;230:289-96; discussion 296-7.
962. Lederle FA, Johnson GR, Wilson SE, et al. Rupture rate of large abdominal aortic aneurysms in patients refusing or unfit for elective repair. JAMA 2002;287:2968-72.
963. United Kingdom Small Aneurysm Trial Participants. Long-term outcomes of immediate repair compared with surveillance of small abdominal aortic aneurysms. N Engl J Med 2002;346:1445-52.
964. Brewster DC, Cronenwett JL, Hallett JW Jr, et al. Guidelines for the treatment of abdominal aortic aneurysms: report of a subcommittee of the Joint Council of the American Association for Vascular Surgery and Society for Vascular Surgery J Vasc Surg 2003;37:1106-17.
965. Krupski WC, Selzman CH, Floridia R, et al. Contemporary management of isolated iliac aneurysms. J Vasc Surg 1998;28:1-11; discussion 11-3.
966. Kasirajan V, Hertzer NR, Beven EG, et al. Management of isolated common iliac artery aneurysms. Cardiovasc Surg 1998;6:171-7.
967. Carpenter JP, Barker CF, Roberts B, et al. Popliteal artery aneurysms: current management and outcome. J Vasc Surg 1994; 19:65-72; discussion 72-3.
968. Varga ZA, Locke-Edmunds JC, Baird RN. A multicenter study of popliteal aneurysms. Joint Vascular Research Group. J Vasc Surg 1994;20:171-7.
969. Vowden P, Wilkinson D, Ausobsky JR, et al. A comparison of three imaging techniques in the assessment of an abdominal aortic aneurysm. J Cardiovasc Surg (Torino) 1989;30:891-6.
970. Muluk SC, Gertler JP, Brewster DC, et al. Presentation and patterns of aortic aneurysms in young patients. J Vasc Surg 1994;20:880-6; discussion 887-8.
971. Kiell CS, Ernst CB. Advances in management of abdominal aortic aneurysm. Adv Surg 1993;26:73-98.
972. Newman AB, Arnold AM, Burke GL, et al. Cardiovascular disease and mortality in older adults with small abdominal aortic aneurysms detected by ultrasonography: the cardiovascular health study. Ann Intern Med 2001;134:182-90.
973. Zarins CK, Harris EJ Jr. Operative repair for aortic aneurysms: the gold standard. J Endovasc Surg 1997;4:232-41.
974. Crawford ES, Cohen ES. Aortic aneurysm: a multifocal disease. Presidential address. Arch Surg 1982;117:1393-400.
975. Bickerstaff LK, Pairolero PC, Hollier LH, et al. Thoracic aortic aneurysms: a population-based study. Surgery 1982;92:1103-8.
976. Pressler V, McNamara JJ. Aneurysm of the thoracic aorta: review of 260 cases. J Thorac Cardiovasc Surg 1985;89:50-4.
977. Lederle FA, Simel DL. The rational clinical examination: does this patient have abdominal aortic aneurysm? JAMA 1999; 281:77-82.
978. May AG, DeWeese JA, Frank I, et al. Surgical treatment of abdominal aortic aneurysms. Surgery 1968;63:711-21.
979. Nichols GB, Schilling PJ. Pseudo-retroperitoneal gas in rupture of aneurysm of abdominal aorta. Am J Roentgenol Radium Ther Nucl Med 1975;125:134-7.
980. JANOWER ML. Ruptured arteriosclerotic aneurysms of the abdominal aorta: roentgenographic findings on plain films. N

Engl J Med 1961;265:12-5.
981. Littooy FN, Steffan G, Greisler HP, et al. Use of sequential B-mode ultrasonography to manage abdominal aortic aneurysms. Arch Surg 1989;124:419-21.
982. Hara AK, Johnson CD, MacCarty RL, et al. Incidental extracolonic findings at CT colonography. Radiology 2000;215:353-7.
983. Flanigan RC, McKay TC, Olson M, et al. Limited efficacy of preoperative computed tomographic scanning for the evaluation of lymph node metastasis in patients before radical prostatectomy. Urology 1996;48:428-32.
984. Aoyagi K, Watanabe N, Yukihiro M, et al. Incidental detection of arterial aneurysms with Tc-99m human serum albumin. Clin Nucl Med 1996;21:485-6.
985. Phillips SM, King D. The role of ultrasound to detect aortic aneurysms in "urological" patients. Eur J Vasc Surg 1993;7:298-300.
986. Howe SF, Taylor RJ, Halloran BG, et al. Management of synchronous renal cell carcinoma and aortic disease. Surg Gynecol Obstet 1995;170:231-4.
987. Kumar A, Pham DH, Meindok H, et al. Diagnosis of bleeding mycotic iliac aneurysm on technetium-99m renal scan. J Nucl Med 1992;33:1548-9.
988. Akkersdijk GJ, Puylaert JB, de Vries AC. Abdominal aortic aneurysm as an incidental finding in abdominal ultrasonography. Br J Surg 1991;78:1261-3.
989. Thompson GT. Incidental findings on gallbladder sonography. Can Assoc Radiol J 1987;38:40-1.
990. Moreno AJ, Brown JM, Spicer MJ, et al. Ruptured abdominal aortic aneurysm identified incidental to bone scintigraphy. Eur J Nucl Med 1983;8:546-8.
991. Hautumm B, Grauel H. Aortic aneurysm in urology. Int Urol Nephrol 1982;14:3-11.
992. Spittell PC, Ehrsam JE, Anderson L, et al. Screening for abdominal aortic aneurysm during transthoracic echocardiography in a hypertensive patient population. J Am Soc Echocardiogr 1997;10:722-7.
993. Derbyshire ND, Lindsell DR, Collin J, et al. Opportunistic screening for abdominal aortic aneurysm. J Med Screen 1994;1:220-2.
994. Wolf YG, Otis SM, Schwend RB, et al. Screening for abdominal aortic aneurysms during lower extremity arterial evaluation in the vascular laboratory. J Vasc Surg 1995;22:417-21; discussion 421-3.
995. Rosch J, Keller FS, Porter JM, et al. Value of angiography in the management of abdominal aortic aneurysm. Cardiovasc Radiol 1978;1:83-94.
996. Bandyk DF. Preoperative imaging of aortic aneurysms: conventional and digital subtraction angiography, computed tomography scanning, and magnetic resonance imaging. Surg Clin North Am 1989;69:721-35.
997. Siegel CL, Cohan RH. CT of abdominal aortic aneurysms. AJR Am J Roentgenol 1994;163:17-29.
998. Turnipseed WD, Acher CW, Detmer DE, et al. Digital subtraction angiography and B-mode ultrasonography for abdominal and peripheral aneurysms. Surgery 1982;92:619-26.
999. Maloney JD, Pairolero PC, Smith SF Jr, et al. Ultrasound evaluation of abdominal aortic aneurysms. Circulation 1977;56(3 suppl):II80-5.
1000. Ellis M, Powell JT, Greenhalgh RM. Limitations of ultrasonography in surveillance of small abdominal aortic aneurysms. Br J Surg 1991;78:614-6.
1001. Andrews SM, Cuming R, Macsweeney ST, et al. Assessment of feasibility for endovascular prosthetic tube correction of aortic aneurysm. Br J Surg 1995;82:917-9.
1002. Diwan A, Sarkar R, Stanley JC, et al. Incidence of femoral and popliteal artery aneurysms in patients with abdominal aortic aneurysms. J Vasc Surg 2000;31:863-9.
1003. Helvie MA, Rubin JM, Silver TM, et al. The distinction between femoral artery pseudoaneurysms and other causes of groin masses: value of duplex Doppler sonography. AJR Am J Roentgenol 1988;150:1177-80.
1004. Bluth EI, Merritt CR, Sullivan MA. Gray-scale ultrasound evaluation of the lower extremities. JAMA 1982;247:3127-9.
1005. Hirsch JH, Thiele BL, Carter SS, et al. Aortic and lower extremity arterial aneurysms. J Clin Ultrasound 1981;9:29-31.
1006. Neiman HL, Yao JS, Silver TM. Gray-scale ultrasound diagnosis of peripheral arterial aneurysms. Radiology 1979;130:413-6.
1007. Collins GJ Jr, Rich NM, Phillips J, et al. Ultrasound diagnosis of popliteal arterial aneurysms. Am Surg 1976;42:853-8.
1008. Atallah C, al Hassan HK, Neglen P. Superficial femoral artery aneurysm—an uncommon site of aneurysm formation. Eur J Vasc Endovasc Surg 1995;10:502-4.
1009. Lindholt JS, Henneberg EW, Fasting H, et al. Hospital based screening of 65-73 year old men for abdominal aortic aneurysms in the county of Viborg, Denmark. J Med Screen 1996;3:43-6.
1010. Pleumeekers HJ, Hoes AW, Hofman A, et al. Selecting subjects for ultrasonographic screening for aneurysms of the abdominal aorta: four different strategies. Int J Epidemiol 1999;28:682-6.
1011. Lindholt JS, Vammen S, Juul S, et al. The validity of ultrasonographic scanning as screening method for abdominal aortic aneurysm. Eur J Vasc Endovasc Surg 1999;17:472-5.
1012. Nasim A, Thompson MM, Sayers RD, et al. Role of magnetic resonance angiography for assessment of abdominal aortic aneurysm before endoluminal repair. Br J Surg 1998;85:641-4.
1013. Taylor SM, Mills JL, Fujitani RM. The juxtarenal abdominal aortic aneurysm: a more common problem than previously realized? Arch Surg 1994;129:734-7.
1014. Tennant WG, Hartnell GG, Baird RN, et al. Radiologic investigation of abdominal aortic aneurysm disease: comparison of three modalities in staging and the detection of inflammatory change. J Vasc Surg 1993;17:703-9.
1015. Lamah M, Darke S. Value of routine computed tomography in the preoperative assessment of abdominal aneurysm replacement. World J Surg 1999;23:1076-80; discussion 1080-1.
1016. Fillinger MF. Imaging of the thoracic and thoracoabdominal aorta. Semin Vasc Surg 2000;13:247-63.
1017. Errington ML, Ferguson JM, Gillespie IN, et al. Complete preoperative imaging assessment of abdominal aortic aneurysm with spiral CT angiography. Clin Radiol 1997;52:369-77.
1018. Rubin GD, Armerding MD, Dake MD, et al. Cost identification of abdominal aortic aneurysm imaging by using time and motion analyses. Radiology 2000;215:63-70.
1019. Galt SW, Pearce WH. Preoperative assessment of abdominal aortic aneurysms: noninvasive imaging versus routine arteriography. Semin Vasc Surg 1995;8:103-7.
1020. Coulam CH, Rubin GD. Acute aortic abnormalities. Semin Roentgenol 2001;36:148-64.
1021. Papanicolaou N, Wittenberg J, Ferrucci JT Jr, et al. Preoperative evaluation of abdominal aortic aneurysms by computed tomography. AJR Am J Roentgenol 1986;146:711-5.
1022. Vicaretti M, Young N, Jenkins J, et al. Helical computed tomography in the assessment of abdominal aortic pathology. Australas Radiol 1997;41:125-31.
1023. Eriksson I, Forsberg JO, Hemmingsson A, et al. Preoperative evaluation of abdominal aortic aneurysms: is there a need for

aortography? Acta Chir Scand 1981;147:533-7.
1024. Broeders IA, Blankensteijn JD. Preoperative imaging of the aortoiliac anatomy in endovascular aneurysm surgery. Semin Vasc Surg 1999;12:306-14.
1025. Ludman CN, Yusuf SW, Whitaker SC, et al. Feasibility of using dynamic contrast-enhanced magnetic resonance angiography as the sole imaging modality prior to endovascular repair of abdominal aortic aneurysms. Eur J Vasc Endovasc Surg 2000;19:524-30.
1026. Hovsepian DM, Siegel BA, Kimbiris G, et al. Tc-99m sulfur colloid scintigraphy for detecting perigraft flow following endovascular aortic aneurysm repair: a feasibility study. Cardiovasc Intervent Radiol 1999;22:447-51.
1027. Hanson SR, Kotze HF, Pieters H, et al. Analysis of indium-111 platelet kinetics and imaging in patients with aortic grafts and abdominal aortic aneurysms. Arteriosclerosis 1990;10:1037-44.
1028. Prince MR, Yucel EK, Kaufman JA, et al. Dynamic gadolinium-enhanced three-dimensional abdominal MR arteriography. J Magn Reson Imaging 1993;3:877-81.
1029. Frayne R, Grist TM, Swan JS, et al. 3D MR DSA: effects of injection protocol and image masking. J Magn Reson Imaging 2000;12:476-87.
1030. Yamashita Y, Mitsuzaki K, Tang Y, et al. Gadolinium-enhanced breath-hold three-dimensional time-of-flight MR angiography of the abdominal and pelvic vessels: the value of ultrafast MP-RAGE sequences. J Magn Reson Imaging 1997;7:623-8.
1031. Thurnher SA, Dorffner R, Thurnher MM, et al. Evaluation of abdominal aortic aneurysm for stent-graft placement: comparison of gadolinium-enhanced MR angiography versus helical CT angiography and digital subtraction angiography. Radiology 1997;205:341-52.
1032. Scott RA, Ashton HA, Kay DN. Abdominal aortic aneurysm in 4237 screened patients: prevalence, development and management over 6 years. Br J Surg 1991;78:1122-5.
1033. Grimshaw GM, Thompson JM. The abnormal aorta: a statistical definition and strategy for monitoring change. Eur J Vasc Endovasc Surg 1995;10:95-100.
1034. Scott RA, Vardulaki KA, Walker NM, et al. The long-term benefits of a single scan for abdominal aortic aneurysm (AAA) at age 65. Eur J Vasc Endovasc Surg 2001;21:535-40.
1035. Cole CW, Hill GB, Millar WJ, et al. Selective screening for abdominal aortic aneurysm. Chronic Dis Can. 1996;17:51-5.
1036. Multicentre Aneurysm Screening Study Group. Multicentre aneurysm screening study (MASS): cost effectiveness analysis of screening for abdominal aortic aneurysms based on four year results from randomised controlled trial. BMJ 2002;325:1135.
1037. Ashton HA, Buxton MJ, Day NE, et al. The Multicentre Aneurysm Screening Study (MASS) into the effect of abdominal aortic aneurysm screening on mortality in men: a randomised controlled trial. Lancet 2002;360:1531-9.
1038. Connelly JB, Hill GB, Millar WJ. The detection and management of abdominal aortic aneurysm: a cost-effectiveness analysis. Clin Invest Med 2002;25:127-33.
1039. Soisalon-Soininen S, Rissanen P, Pentikainen T, et al. Cost-effectiveness of screening for familial abdominal aortic aneurysms. Vasa 2001;30:262-70.
1040. Lee TY, Korn P, Heller JA, et al. The cost-effectiveness of a "quick-screen" program for abdominal aortic aneurysms. Surgery 2002;132:399-407.
1041. Fleming C, Whitlock EP, Beil TL, et al. Screening for abdominal aortic aneurysm: a best-evidence systematic review for the U.S. Preventive Services Task Force. Ann Intern Med 2005;142:203-11.
1042. Meenan RT, Fleming C, Whitlock EP, et al. Cost-Effectiveness Analyses of Population-Based Screening for Abdominal Aortic Aneurysm. Evidence Synthesis. AHRQ Publication No. 05-0569-C, February 2005. Agency for Healthcare Research and Quality, Rockville, Md. Available at: http://www.ahrq.gov/clinic/uspstf05/aaascr/aaacost.htm. Accessed July 16, 2005.
1043. Brophy C, Tilson JE, Tilson MD. Propranolol delays the formation of aneurysms in the male blotchy mouse. J Surg Res 1988; 44:687-9.
1044. Ricci MA, Slaiby JM, Gadowski GR, et al. Effects of hypertension and propranolol upon aneurysm expansion in the Anidjar/Dobrin aneurysm model. Ann N Y Acad Sci 1996; 800:89-96.
1045. Leach SD, Toole AL, Stern H, et al. Effect of beta-adrenergic blockade on the growth rate of abdominal aortic aneurysms. Arch Surg 1988;123:606-9.
1046. Gadowski GR, Pilcher DB, Ricci MA. Abdominal aortic aneurysm expansion rate: effect of size and beta-adrenergic blockade. J Vasc Surg 1994;19:727-31.
1047. Lindholt JS, Henneberg EW, Juul S, et al. Impaired results of a randomised double blinded clinical trial of propranolol versus placebo on the expansion rate of small abdominal aortic aneurysms. Int Angiol 1999;18:52-7.
1048. Shores J, Berger KR, Murphy EA, et al. Progression of aortic dilatation and the benefit of long-term beta-adrenergic blockade in Marfan's syndrome. N Engl J Med 1994;330:1335-41.
1049. Kertai MD, Boersma E, Westerhout CM, et al. A combination of statins and beta-blockers is independently associated with a reduction in the incidence of perioperative mortality and nonfatal myocardial infarction in patients undergoing abdominal aortic aneurysm surgery. Eur J Vasc Endovasc Surg 2004;28:343-52.
1050. Fleisher LA, Eagle KA. Clinical practice: lowering cardiac risk in noncardiac surgery. N Engl J Med 2001;345:1677-82.
1051. Auerbach AD, Goldman L. Beta-blockers and reduction of cardiac events in noncardiac surgery: scientific JAMA 2002; 287:1435-44.
1052. Cook TA, Galland RB. A prospective study to define the optimum rescreening interval for small abdominal aortic aneurysm. Cardiovasc Surg 1996;4:441-4.
1053. Finlayson SR, Birkmeyer JD, Fillinger MF, et al. Should endovascular surgery lower the threshold for repair of abdominal aortic aneurysms? J Vasc Surg 1999;29:973-85.
1054. Thompson RW. Detection and management of small aortic aneurysms. N Engl J Med 2002;346:1484-6.
1055. d'Audiffret A, Santilli S, Tretinyak A, et al. Fate of the ectatic infrarenal aorta: expansion rates and outcomes. Ann Vasc Surg 2002;16:534-6.
1056. Hallett JW Jr, Naessens JM, Ballard DJ. Early and late outcome of surgical repair for small abdominal aortic aneurysms: a population-based analysis. J Vasc Surg 1993;18:684-91.
1057. Koskas F, Kieffer E. Long-term survival after elective repair of infrarenal abdominal aortic aneurysm: results of a prospective multicentric study. Association for Academic Research in Vascular Surgery (AURC). Ann Vasc Surg 1997;11:473-81.
1058. Aune S. Risk factors and operative results of patients aged less than 66 years operated on for asymptomatic abdominal aortic aneurysm. Eur J Vasc Endovasc Surg 2001;22:240-3.
1059. Brady AR, Fowkes FG, Thompson SG, et al. Aortic aneurysm diameter and risk of cardiovascular mortality. Arterioscler Thromb Vasc Biol 2001;21:1203-7.
1060. Starr JE, Hertzer NR, Mascha EJ, et al. Influence of gender on cardiac risk and survival in patients with infrarenal aortic aneurysms. J Vasc Surg 1996;23:870-80.

1061. Crawford ES, Saleh SA, Babb JW 3rd, et al. Infrarenal abdominal aortic aneurysm: factors influencing survival after operation performed over a 25-year period. Ann Surg 1981;193:699-709.
1062. Hollier LH, Plate G, O'Brien PC, et al. Late survival after abdominal aortic aneurysm repair: influence of coronary artery disease. J Vasc Surg 1984;1:290-9.
1063. Reigel MM, Hollier LH, Kazmier FJ, et al. Late survival in abdominal aortic aneurysm patients: the role of selective myocardial revascularization on the basis of clinical symptoms. J Vasc Surg 1987;5:222-7.
1064. Glance LG. Selective preoperative cardiac screening improves five-year survival in patients undergoing major vascular surgery: a cost-effectiveness analysis. J Cardiothorac Vasc Anesth 1999;13:265-71.
1065. Golden MA, Whittemore AD, Donaldson MC, et al. Selective evaluation and management of coronary artery disease in patients undergoing repair of abdominal aortic aneurysms: a 16-year experience. Ann Surg 1990;212:415-20; discussion 420-3.
1066. Lachapelle K, Graham AM, Symes JF. Does the clinical evaluation of the cardiac status predict outcome in patients with abdominal aortic aneurysms? J Vasc Surg 1992;15:964-70; discussion 970-1.
1067. Suggs WD, Smith RB 3rd, Weintraub WS, et al. Selective screening for coronary artery disease in patients undergoing elective repair of abdominal aortic aneurysms. J Vasc Surg 1993;18:349-55; discussion 355-7.
1068. Hertzer NR, Mascha EJ, Karafa MT, et al. Open infrarenal abdominal aortic aneurysm repair: the Cleveland Clinic experience from 1989 to 1998. J Vasc Surg 2002;35:1145-54.
1069. McFalls EO, Ward HB, Moritz TE, et al. Coronary-artery revascularization before elective major vascular surgery. N Engl J Med 2004;351:2795-804. Erratum in: N Engl J Med 2005; 95:19.
1070. Darling RC 3rd, Cordero JA Jr, Chang BB, et al. Advances in the surgical repair of ruptured abdominal aortic aneurysms. Cardiovasc Surg 1996;4:720-3.
1071. Sicard GA, Reilly JM, Rubin BG, et al. Transabdominal versus retroperitoneal incision for abdominal aortic surgery: report of a prospective randomized trial. J Vasc Surg 1995;21:174-81; discussion 181-3.
1072. Cambria RP, Brewster DC, Abbott WM, et al. Transperitoneal versus retroperitoneal approach for aortic reconstruction: a randomized prospective study. J Vasc Surg 1990;11:314-24; discussion 324-5.
1073. Sieunarine K, Lawrence-Brown MM, Goodman MA. Comparison of transperitoneal and retroperitoneal approaches for infrarenal aortic surgery: early and late results. Cardiovasc Surg 1997;5:71-6.
1074. Blankensteijn JD, Lindenburg FP, Van der Graaf Y, et al. Influence of study design on reported mortality and morbidity rates after abdominal aortic aneurysm repair. Br J Surg 1998;85:1624-30.
1075. Lawrence PF, Gazak C, Bhirangi L, et al. The epidemiology of surgically repaired aneurysms in the United States. J Vasc Surg 1999;30:632-40.
1076. Heller JA, Weinberg A, Arons R, et al. Two decades of abdominal aortic aneurysm repair: have we made any progress? J Vasc Surg 2000;32:1091-100.
1077. Huber TS, Wang JG, Derrow AE, et al. Experience in the United States with intact abdominal aortic aneurysm repair. J Vasc Surg 2001;33:304-10; discussion 310-1.
1078. Dimick JB, Stanley JC, Axelrod DA, et al. Variation in death rate after abdominal aortic aneurysmectomy in the United States: impact of hospital volume, gender, and age. Ann Surg 2002; 235:579-85.
1079. Lloyd WE, Paty PS, Darling RC 3rd, et al. Results of 1000 consecutive elective abdominal aortic aneurysm repairs. Cardiovasc Surg 1996;4:724-6.
1080. Menard MT, Chew DK, Chan RK, et al. Outcome in patients at high risk after open surgical repair of abdominal aortic aneurysm. J Vasc Surg 2003;37:285-92.
1081. Ernst CB. Abdominal aortic aneurysm. N Engl J Med 1993; 328:1167-72.
1082. Johnston KW, Scobie TK. Multicenter prospective study of nonruptured abdominal aortic aneurysms. I. Population and operative management. J Vasc Surg 1988;7:69-81.
1083. Richardson JD, Main KA. Repair of abdominal aortic aneurysms. A statewide experience. Arch Surg 1991;126:614-6.
1084. Hannan EL, Kilburn H Jr, O'Donnell JF, et al. A longitudinal analysis of the relationship between in-hospital mortality in New York State and the volume of abdominal aortic aneurysm surgeries performed. Health Serv Res. 1992;27:517-42.
1085. Johnston KW. Nonruptured abdominal aortic aneurysm: six-year follow-up results from the multicenter prospective Canadian aneurysm study. Canadian Society for Vascular Surgery Aneurysm Study Group. J Vasc Surg 1994;20:163-70.
1086. Katz DJ, Stanley JC, Zelenock GB. Operative mortality rates for intact and ruptured abdominal aortic aneurysms in Michigan: an eleven-year statewide experience. J Vasc Surg 1994;19:804-15; discussion 816-7.
1087. Kazmers A, Jacobs L, Perkins A, et al. Abdominal aortic aneurysm repair in Veterans Affairs medical centers. J Vasc Surg 1996;23:191-200.
1088. Wen SW, Simunovic M, Williams JI, et al. Hospital volume, calendar age, and short term outcomes in patients undergoing repair of abdominal aortic aneurysms: the Ontario experience, 1988-92. J Epidemiol Community Health 1996;50:207-13.
1089. Kantonen I, Lepantalo M, Salenius JP, et al. Mortality in abdominal aortic aneurysm surgery—the effect of hospital volume, patient mix and surgeon's case load. Eur J Vasc Endovasc Surg 1997;14:375-9.
1090. Bradbury AW, Adam DJ, Makhdoomi KR, et al. A 21-year experience of abdominal aortic aneurysm operations in Edinburgh. Br J Surg 1998;85:645-7.
1091. Manheim LM, Sohn MW, Feinglass J, et al. Hospital vascular surgery volume and procedure mortality rates in California,982-1994. J Vasc Surg 1998;28:45-56; discussion 56-8.
1092. Dardik A, Lin JW, Gordon TA, et al. Results of elective abdominal aortic aneurysm repair in the 1990s: a population-based analysis of 2335 cases. J Vasc Surg 1999;30:985-95.
1093. Pearce WH, Parker MA, Feinglass J, et al. The importance of surgeon volume and training in outcomes for vascular surgical procedures. J Vasc Surg 1999;29:768-76; discussion 777-8.
1094. Sollano JA, Gelijns AC, Moskowitz AJ, et al. Volume-outcome relationships in cardiovascular operations: New York State, 1990-1995. J Thorac Cardiovasc Surg 1999;117:419-28; discussion 428-30.
1095. Kazmers A, Perkins AJ, Jacobs LA. Aneurysm rupture is independently associated with increased late mortality in those surviving abdominal aortic aneurysm repair. J Surg Res 2001;95:50-3.
1096. Huber TS, Seeger JM. Dartmouth Atlas of Vascular Health Care review: impact of hospital volume, surgeon volume, and training on outcome. J Vasc Surg 2001;34:751-6.
1097. Panneton JM, Lassonde J, Laurendeau F. Ruptured abdominal aortic aneurysm: impact of comorbidity and postoperative com-

plications on outcome. Ann Vasc Surg 1995;9:535-41.
1098. Seiwert AJ, Elmore JR, Youkey JR, et al. Samuels Award. Ruptured abdominal aortic aneurysm repair: the financial analysis. Surg Gynecol Obstet 1995;170:91-6.
1099. Barry MC, Burke PE, Sheehan S, et al. An "all comers" policy for ruptured abdominal aortic aneurysms: how can results be improved? Eur J Surg 1998;164:263-70.
1100. Noel AA, Gloviczki P, Cherry KJ Jr, et al. Ruptured abdominal aortic aneurysms: the excessive mortality rate of conventional repair. J Vasc Surg 2001;34:41-6.
1101. Hertzer NR, Avellone JC, Farrell CJ, et al. The risk of vascular surgery in a metropolitan community: with observations on surgeon experience and hospital size. J Vasc Surg 1984;1:13-21.
1102. Johnston KW. Ruptured abdominal aortic aneurysm: six-year follow-up results of a multicenter prospective study. Canadian Society for Vascular Surgery Aneurysm Study Group. J Vasc Surg 1994;19:888-900.
1103. Amundsen S, Skjaerven R, Trippestad A, et al. Abdominal aortic aneurysms—a study of factors influencing postoperative mortality. Norwegian Aortic Aneurysm Trial. Eur J Vasc Surg 1989;3:405-9.
1104. Gloviczki P, Pairolero PC, Mucha P Jr, et al. Ruptured abdominal aortic aneurysms: repair should not be denied. J Vasc Surg 1992;15:851-7; discussion 857-9.
1105. Halpern VJ, Kline RG, D'Angelo AJ, et al. Factors that affect the survival rate of patients with ruptured abdominal aortic aneurysms. J Vasc Surg 1997;26:939-45; discussion 945-8.
1106. Steyerberg EW, Kievit J, de Mol Van Otterloo JC, et al. Perioperative mortality of elective abdominal aortic aneurysm surgery: a clinical prediction rule based on literature and individual patient data. Arch Intern Med 1995;155:1998-2004.
1107. Brady AR, Fowkes FG, Greenhalgh RM, et al. Risk factors for postoperative death following elective surgical repair of abdominal aortic aneurysm: results from the UK Small Aneurysm Trial. On behalf of the UK Small Aneurysm Trial participants. Br J Surg 2000;87:742-9.
1108. Kazmers A, Perkins AJ, Jacobs LA. Outcomes after abdominal aortic aneurysm repair in those > or =80 years of age: recent Veterans Affairs experience. Ann Vasc Surg 1998;12:106-12.
1109. O'Hara PJ, Hertzer NR, Krajewski LP, et al. Ten-year experience with abdominal aortic aneurysm repair in octogenarians: early results and late outcome. J Vasc Surg 1995;21:830-7; discussion 837-8.
1110. Harris KA, Ameli FM, Lally M, et al. Abdominal aortic aneurysm resection in patients more than 80 years old. Surg Gynecol Obstet 1986;162:536-8.
1111. Collins TC, Johnson M, Daley J, et al. Preoperative risk factors for 30-day mortality after elective surgery for vascular disease in Department of Veterans Affairs hospitals: is race important? J Vasc Surg 2001;34:634-40.
1112. Shackley P, Slack R, Booth A, et al. Is there a positive volume-outcome relationship in peripheral vascular surgery? Results of a systematic Eur J Vasc Endovasc Surg 2000;20:326-35.
1113. Amundsen S, Skjaerven R, Trippestad A, et al. Abdominal aortic aneurysms: is there an association between surgical volume, surgical experience, hospital type and operative mortality? Members of the Norwegian Abdominal Aortic Aneurysm Trial. Acta Chir Scand 1990;156:323-7; discussion 327-8.
1114. Soisalon-Soininen S, Salo JA, Takkunen O, et al. Comparison of long-term survival after repair of ruptured and non-ruptured abdominal aortic aneurysm. Vasa 1995;24:42-8.
1115. Cho JS, Gloviczki P, Martelli E, et al. Long-term survival and late complications after repair of ruptured abdominal aortic aneurysms. J Vasc Surg 1998;27:813-9; discussion 819-20.
1116. Feinglass J, Cowper D, Dunlop D, et al. Late survival risk factors for abdominal aortic aneurysm repair: experience from fourteen Department of Veterans Affairs hospitals. Surgery 1995;118:16-24.
1117. Stonebridge PA, Callam MJ, Bradbury AW, et al. Comparison of long-term survival after successful repair of ruptured and non-ruptured abdominal aortic aneurysm. Br J Surg 1993;80:585-6.
1118. Norman PE, Semmens JB, Lawrence-Brown MM. Long-term relative survival following surgery for abdominal aortic aneurysm: a review. Cardiovasc Surg 2001;9:219-24.
1119. Evans SM, Adam DJ, Brittenden J, et al. Vascular Surgical Society of Great Britain and Ireland: long-term survival following repair of ruptured abdominal aortic aneurysm in patients over 75 years of age. Br J Surg 1999;86:696.
1120. Hallett JW Jr, Marshall DM, Petterson TM, et al. Graft-related complications after abdominal aortic aneurysm repair: reassurance from a 36-year population-based experience. J Vasc Surg 1997;25:277-84; discussion 285-6.
1121. Crawford ES, Beckett WC, Greer MS. Juxtarenal infrarenal abdominal aortic aneurysm: special diagnostic and therapeutic considerations. Ann Surg 1986;203:661-70.
1122. Ayari R, Paraskevas N, Rosset E, et al. Juxtarenal aneurysm: comparative study with infrarenal abdominal aortic aneurysm and proposition of a new classification. Eur J Vasc Endovasc Surg 2001;22:169-74.
1123. Faggioli G, Stella A, Freyrie A, et al. Early and long-term results in the surgical treatment of juxtarenal and pararenal aortic aneurysms. Eur J Vasc Endovasc Surg 1998;15:205-11.
1124. Qvarfordt PG, Stoney RJ, Reilly LM, et al. Management of pararenal aneurysms of the abdominal aorta. J Vasc Surg 1986;3:84-93.
1125. Nypaver TJ, Shepard AD, Reddy DJ, et al. Repair of pararenal abdominal aortic aneurysms: an analysis of operative management. Arch Surg 1993;128:803-11; discussion 811-3.
1126. Jean-Claude JM, Reilly LM, Stoney RJ, et al. Pararenal aortic aneurysms: the future of open aortic aneurysm repair. J Vasc Surg 1999;29:902-12.
1127. Anagnostopoulos PV, Shepard AD, Pipinos II, et al. Factors affecting outcome in proximal abdominal aortic aneurysm repair. Ann Vasc Surg 2001;15:511-9.
1128. Cox GS, O'Hara PJ, Hertzer NR, et al. Thoracoabdominal aneurysm repair: a representative experience. J Vasc Surg 1992; 15:780-7; discussion 787-8.
1129. Svensson LG, Crawford ES, Hess KR, et al. Experience with 1509 patients undergoing thoracoabdominal aortic operations. J Vasc Surg 1993;17:357-68; discussion 368-70.
1130. Coselli JS, LeMaire SA, Buket S, et al. Subsequent proximal aortic operations in 123 patients with previous infrarenal abdominal aortic aneurysm surgery. J Vasc Surg 1995;22:59-67.
1131. Schwartz LB, Belkin M, Donaldson MC, et al. Improvement in results of repair of type IV thoracoabdominal aortic aneurysms. J Vasc Surg 1996;24:74-81.
1132. Dunning PG, Dudgill S, Brown AS, et al. Vascular Surgical Society of Great Britain and Ireland: total abdominal approach for repair of type IV thoracoabdominal aortic aneurysm. Br J Surg 1999;86:696.
1133. Martin GH, O'Hara PJ, Hertzer NR, et al. Surgical repair of aneurysms involving the suprarenal, visceral, and lower thoracic aortic segments: early results and late outcome. J Vasc Surg 2000;31:851-62.
1134. Parodi JC, Palmaz JC, Barone HD. Transfemoral intraluminal graft implantation for abdominal aortic aneurysms. Ann Vasc

Surg 1991;5:491-9.
1135. Anderson PL, Arons RR, Moskowitz AJ, et al. A statewide experience with endovascular abdominal aortic aneurysm repair: rapid diffusion with excellent early results. J Vasc Surg 2004;39:10-9.
1136. Jacobs TS, Won J, Gravereaux EC, et al. Mechanical failure of prosthetic human implants: a 10-year experience with aortic stent graft devices. J Vasc Surg 2003;37:16-26.
1137. Zarins CK; AneuRx Clinical Investigators. The US AneuRx Clinical Trial: 6-year clinical update 2002. J Vasc Surg 2003; 37:904-8.
1138. Dillavou ED, Muluk SC, Rhee RY, et al. Does hostile neck anatomy preclude successful endovascular aortic aneurysm repair? J Vasc Surg 2003;38:657-63.
1139. Arko FR, Filis KA, Seidel SA, et al. How many patients with infrarenal aneurysms are candidates for endovascular repair? The Northern California experience. J Endovasc Ther 2004;11:33-40.
1140. Carpenter JP, Baum RA, Barker CF, et al. Impact of exclusion criteria on patient selection for endovascular abdominal aortic aneurysm repair. J Vasc Surg 2001;34:1050-4.
1141. Becker GJ, Kovacs M, Mathison MN, et al. Risk stratification and outcomes of transluminal endografting for abdominal aortic aneurysm: 7-year experience and long-term follow-up. J Vasc Interv Radiol 2001;12:1033-46.
1142. Mathison M, Becker GJ, Katzen BT, et al. The influence of female gender on the outcome of endovascular abdominal aortic aneurysm repair. J Vasc Interv Radiol 2001;12:1047-51.
1143. Wolf YG, Arko FR, Hill BB, et al. Gender differences in endovascular abdominal aortic aneurysm repair with the AneuRx stent graft. J Vasc Surg 2002;35:882-6.
1144. Veith FJ, Baum RA, Ohki T, et al. Nature and significance of endoleaks and endotension: summary of opinions expressed at an international conference. J Vasc Surg 2002;35:1029-35.
1145. White RA, Donayre C, Walot I, et al. Abdominal aortic aneurysm rupture following endoluminal graft deployment: report of a predictable event. J Endovasc Ther 2000;7:257-62.
1146. Abraham CZ, Chuter TA, Reilly LM, et al. Abdominal aortic aneurysm repair with the Zenith stent graft: short to midterm results. J Vasc Surg 2002;36:217-24; discussion 224-5.
1147. Zarins CK, Wolf YG, Lee WA, et al. Will endovascular repair replace open surgery for abdominal aortic aneurysm repair? Ann Surg 2000;232:501-7.
1148. Zarins CK, White RA, Moll FL, et al. The AneuRx stent graft: four-year results and worldwide experience 2000. J Vasc Surg 2001;33(2 suppl):S135-45. Erratum in: J Vasc Surg 2001; 33:1318.
1149. Sapirstein W, Chandeysson P, Wentz C. The Food and Drug Administration approval of endovascular grafts for abdominal aortic aneurysm: an 18-month retrospective. J Vasc Surg 2001;34:180-3.
1150. Harris PL, Buth J. An update on the important findings from the EUROSTAR EVAR registry. Vascular. 2004;12:33-8.
1151. Steinmetz E, Rubin BG, Sanchez LA, et al. Type II endoleak after endovascular abdominal aortic aneurysm repair: a conservative approach with selective intervention is safe and cost-effective. J Vasc Surg 2004;39:306-13.
1152. Stelter W, Umscheid T, Ziegler P. Three-year experience with modular stent-graft devices for endovascular AAA treatment. J Endovasc Surg 1997;4:362-9.
1153. Amesur NB, Zajko AB, Orons PD, et al. Endovascular treatment of iliac limb stenoses or occlusions in 31 patients treated with the Ancure endograft. J Vasc Interv Radiol 2000;11:421-8.
1154. Baum RA, Shetty SK, Carpenter JP, et al. Limb kinking in supported and unsupported abdominal aortic stent-grafts. J Vasc Interv Radiol 2000;11:1165-71.
1155. Fairman RM, Baum RA, Carpenter JP, et al. Limb interventions in patients undergoing treatment with an unsupported bifurcated aortic endograft system: a review of the Phase II EVT Trial. J Vasc Surg 2002;36:118-26.
1156. Greenberg RK, Lawrence-Brown M, Bhandari G, et al. An update of the Zenith endovascular graft for abdominal aortic aneurysms: initial implantation and mid-term follow-up data. J Vasc Surg 2001;33(2 suppl):S157-64.
1157. Conners MS 3rd, Sternbergh WC 3rd, Carter G, et al. Endograft migration one to four years after endovascular abdominal aortic aneurysm repair with the AneuRx device: a cautionary note. J Vasc Surg 2002;36:476-84.
1158. Makaroun MS, Deaton DH. Is proximal aortic neck dilatation after endovascular aneurysm exclusion a cause for concern? J Vasc Surg 2001;33(2 suppl):S39-45.
1159. Matsumura JS, Chaikof EL. Continued expansion of aortic necks after endovascular repair of abdominal aortic aneurysms. EVT Investigators. EndoVascular Technologies, Inc. J Vasc Surg 1998;28:422-30; discussion 430-1.
1160. de Virgilio C, Bui H, Donayre C, et al. Endovascular vs open abdominal aortic aneurysm repair: a comparison of cardiac morbidity and mortality. Arch Surg 1999;134:947-50; discussion 950-1.
1161. Aziz IN, Lee JT, Kopchok GE, et al. Cardiac risk stratification in patients undergoing endoluminal graft repair of abdominal aortic aneurysm: a single-institution experience with 365 patients. J Vasc Surg 2003;38:56-60.
1162. Cuypers PW, Gardien M, Buth J, et al. Cardiac response and complications during endovascular repair of abdominal aortic aneurysms: a concurrent comparison with open surgery. J Vasc Surg 2001;33:353-60.
1163. Buth J, Laheij RJ. Early complications and endoleaks after endovascular abdominal aortic aneurysm repair: report of a multicenter study. J Vasc Surg 2000;31(1 pt 1):134-46.
1164. Chuter TA, Reilly LM, Faruqi RM, et al. Endovascular aneurysm repair in high-risk patients. J Vasc Surg 2000;31(1 pt 1):122-33.
1165. May J, White GH, Waugh R, et al. Improved survival after endoluminal repair with second-generation prostheses compared with open repair in the treatment of abdominal aortic aneurysms: a 5-year concurrent comparison using life table method. J Vasc Surg 2001;33(2 suppl):S21-6.
1166. Buth J, van Marrewijk CJ, Harris PL, et al. Outcome of endovascular abdominal aortic aneurysm repair in patients with conditions considered unfit for an open procedure: a report on the EUROSTAR experience. J Vasc Surg 2002;35:211-21.
1167. Blum U, Voshage G, Beyersdorf F, et al. Two-center German experience with aortic endografting. J Endovasc Surg 1997; 4:137-46.
1168. May J, White GH, Yu W, et al. Endovascular grafting for abdominal aortic aneurysms: changing incidence and indication for conversion to open operation. Cardiovasc Surg 1998;6:194-7.
1169. Amesur NB, Zajko AB, Orons PD, et al. Embolotherapy of persistent endoleaks after endovascular repair of abdominal aortic aneurysm with the Ancure-endovascular technologies endograft system. J Vasc Interv Radiol 1999;10:1175-82.
1170. Becquemin J, Bourriez A, D'Audiffret A, et al. Mid-term results of endovascular versus open repair for abdominal aortic aneurysm in patients anatomically suitable for endovascular

repair. Eur J Vasc Endovasc Surg 2000;19:656-61.
1171. Zarins CK, White RA, Fogarty TJ. Aneurysm rupture after endovascular repair using the AneuRx stent graft. J Vasc Surg 2000;31:960-70.
1172. Blum U, Hauer M, Pfammatter T, et al. Percutaneous endoprosthesis for treatment of aortic aneurysms. World J Surg 2001;25:347-52; discussion 353-4.
1173. Fairman RM, Velazquez O, Baum R, et al. Endovascular repair of aortic aneurysms: critical events and adjunctive procedures. J Vasc Surg 2001;33:1226-32.
1174. Holzenbein TJ, Kretschmer G, Thurnher S, et al. Midterm durability of abdominal aortic aneurysm endograft repair: a word of caution. J Vasc Surg 2001;33(2 suppl):S46-54.
1175. Howell MH, Strickman N, Mortazavi A, et al. Preliminary results of endovascular abdominal aortic aneurysm exclusion with the AneuRx stent-graft. J Am Coll Cardiol 2001;38:1040-6.
1176. Sicard GA, Rubin BG, Sanchez LA, et al. Endoluminal graft repair for abdominal aortic aneurysms in high-risk patients and octogenarians: is it better than open repair? Ann Surg 2001; 234:427-35; discussion 435-7.
1177. Dattilo JB, Brewster DC, Fan CM, et al. Clinical failures of endovascular abdominal aortic aneurysm repair: incidence, causes, and management. J Vasc Surg 2002;35:1137-44.
1178. Sampram ES, Karafa MT, Mascha EJ, et al. Nature, frequency, and predictors of secondary procedures after endovascular repair of abdominal aortic aneurysm. J Vasc Surg 2003;37:930-7.
1179. Ouriel K, Greenberg RK, Clair DG, et al. Endovascular aneurysm repair: gender-specific results. J Vasc Surg 2003; 38:93-8.
1180. Shames ML, Sanchez LA, Rubin BG, et al. Delayed complications after endovascular AAA repair in women. J Endovasc Ther 2003;10:10-5.
1181. Moore WS, Rutherford RB. Transfemoral endovascular repair of abdominal aortic aneurysm: results of the North American EVT phase 1 trial. EVT Investigators. J Vasc Surg 1996;23:543-53.
1182. Coppi G, Pacchioni R, Moratto R, et al. Experience with the Stentor endograft at four Italian centers. J Endovasc Surg 1998;5:206-15.
1183. Becquemin JP, Lapie V, Favre JP, et al. Mid-term results of a second generation bifurcated endovascular graft for abdominal aortic aneurysm repair: the French Vanguard trial. J Vasc Surg 1999;30:209-18.
1184. Zarins CK, White RA, Schwarten D, et al. AneuRx stent graft versus open surgical repair of abdominal aortic aneurysms: multicenter prospective clinical trial. J Vasc Surg 1999;29:292-305; discussion 306-8.
1185. Zarins CK, White RA, Hodgson KJ, et al. Endoleak as a predictor of outcome after endovascular aneurysm repair: AneuRx multicenter clinical trial. J Vasc Surg 2000;32:90-107.
1186. Beebe HG, Cronenwett JL, Katzen BT, et al. Results of an aortic endograft trial: impact of device failure beyond 12 months. J Vasc Surg 2001;33(2 suppl):S55-63.
1187. Faries PL, Brener BJ, Connelly TL, et al. A multicenter experience with the Talent endovascular graft for the treatment of abdominal aortic aneurysms. J Vasc Surg 2002;35:1123-8.
1188. Matsumura JS, Brewster DC, Makaroun MS, et al. A multicenter controlled clinical trial of open versus endovascular treatment of abdominal aortic aneurysm. J Vasc Surg 2003;37:262-71.
1189. Harris PL, Vallabhaneni SR, Desgranges P, et al. Incidence and risk factors of late rupture, conversion, and death after endovascular repair of infrarenal aortic aneurysms: the EUROSTAR experience. European Collaborators on Stent/graft techniques for aortic aneurysm repair. J Vasc Surg 2000;32:739-49.
1190. Vallabhaneni SR, Harris PL. Lessons learnt from the EUROSTAR registry on endovascular repair of abdominal aortic aneurysm repair. Eur J Radiol 2001;39:34-41.
1191. Peppelenbosch N, Buth J, Harris PL, et al. Diameter of abdominal aortic aneurysm and outcome of endovascular aneurysm repair: does size matter? A report from EUROSTAR. J Vasc Surg 2004;39:288-97.
1192. Riambau V, Laheij RJ, Garcia-Madrid C, et al. The association between co-morbidity and mortality after abdominal aortic aneurysm endografting in patients ineligible for elective open surgery. Eur J Vasc Endovasc Surg 2001;22:265-70.
1193. Walker SR, Macierewicz J, MacSweeney ST, et al. Mortality rates following endovascular repair of abdominal aortic aneurysms. J Endovasc Surg 1999;6:233-8.
1194. Birch SE, Stary DR, Scott AR. Cost of endovascular versus open surgical repair of abdominal aortic aneurysms. Aust N Z J Surg 2000;70:660-6.
1195. Clair DG, Gray B, O'hara PJ, et al. An evaluation of the costs to health care institutions of endovascular aortic aneurysm repair. J Vasc Surg 2000;32:148-52.
1196. Bosch JL, Lester JS, McMahon PM, et al. Hospital costs for elective endovascular and surgical repairs of infrarenal abdominal aortic aneurysms. Radiology 2001;220:492-7.
1197. Sternbergh WC 3rd, Money SR. Hospital cost of endovascular versus open repair of abdominal aortic aneurysms: a multicenter study. J Vasc Surg 2000;31:237-44.
1198. Carpenter JP, Baum RA, Barker CF, et al. Durability of benefits of endovascular versus conventional abdominal aortic aneurysm repair. J Vasc Surg 2002;35:222-8.
1199. Bertges DJ, Zwolak RM, Deaton DH, et al. Current hospital costs and medicare reimbursement for endovascular abdominal aortic aneurysm repair. J Vasc Surg 2003;37:272-9.
1200. Arko FR, Hill BB, Reeves TR, et al. Early and late functional outcome assessments following endovascular and open aneurysm repair. J Endovasc Ther 2003;10:2-9.
1201. Schermerhorn ML, Finlayson SR, Fillinger MF, et al. Life expectancy after endovascular versus open abdominal aortic aneurysm repair: results of a decision analysis model on the basis of data from EUROSTAR. J Vasc Surg 2002;36:1112-20.
1202. Cuypers P, Buth J, Harris PL, et al. Realistic expectations for patients with stent-graft treatment of abdominal aortic aneurysms: results of a European multicentre registry. Eur J Vasc Endovasc Surg 1999;17:507-16.
1203. Ohki T, Veith FJ, Shaw P, et al. Increasing incidence of midterm and long-term complications after endovascular graft repair of abdominal aortic aneurysms: a note of caution based on a 9-year experience. Ann Surg 2001;234:323-34; discussion 334-5.
1204. Ouriel K, Clair DG, Greenberg RK, et al. Endovascular repair of abdominal aortic aneurysms: device-specific outcome. J Vasc Surg 2003;37:991-8.
1205. Cuypers PW, Laheij RJ, Buth J. Which factors increase the risk of conversion to open surgery following endovascular abdominal aortic aneurysm repair? The EUROSTAR collaborators. Eur J Vasc Endovasc Surg 2000;20:183-9.
1206. Laheij RJ, Buth J, Harris PL, et al. Need for secondary interventions after endovascular repair of abdominal aortic aneurysms: intermediate-term follow-up results of a European collaborative registry (EUROSTAR). Br J Surg 2000;87:1666-73.
1207. Conner MS 3rd, Sternbergh WC 3rd, Carter G, et al. Secondary procedures after endovascular aortic aneurysm repair. J Vasc Surg 2002;36:992-6.

1208. Ayerdi J, McLafferty RB, Markwell SJ, et al. Indications and outcomes of AneuRx Phase III trial versus use of commercial AneuRx stent graft. J Vasc Surg 2003;37:739-43.
1209. Sternbergh WC, Nordness PJ, York JW, et al. Endo-exuberance to endo-reality: trends in the management of 431 AAA repairs between 1996 and 2002. J Endovasc Ther 2003;10:418-23.
1210. Zarins CK, Bloch DA, Crabtree T, et al. Aneurysm enlargement following endovascular aneurysm repair: AneuRx clinical trial. J Vasc Surg 2004;39:109-17.
1211. Laheij RJ, van Marrewijk CJ; EUROSTAR Group. The evolving technique of endovascular stenting of abdominal aortic aneurysm; time for reappraisal. Eur J Vasc Endovasc Surg 2001; 22:436-42.
1212. Ouriel K, Srivastava SD, Sarac TP, et al. Disparate outcome after endovascular treatment of small versus large abdominal aortic aneurysm. J Vasc Surg 2003;37:1206-12.
1213. Scheinert D, Schroder M, Steinkamp H, et al. Treatment of iliac artery aneurysms by percutaneous implantation of stent grafts. Circulation 2000;102(19 suppl 3):III253-8.
1214. Hausegger KA, Mendel H, Tiessenhausen K, et al. Endoluminal treatment of infrarenal aortic aneurysms: clinical experience with the Talent stent-graft system. J Vasc Interv Radiol 1999; 10:267-74.
1215. Howell MH, Zaqqa M, Villareal RP, et al. Endovascular exclusion of abdominal aortic aneurysms: initial experience with stent-grafts in cardiology practice. Tex Heart Inst J 2000; 27:136-45.
1216. Criado FJ, Wilson EP, Fairman RM, et al. Update on the Talent aortic stent-graft: a preliminary report from United States phase I and II trials. J Vasc Surg 2001;33(2 suppl):S146-9.
1217. Valentine RJ, Decaprio JD, Castillo JM, et al. Watchful waiting in cases of small abdominal aortic aneurysms: appropriate for all patients? J Vasc Surg 2000;32:441-8; discussion 448-50.
1218. Zarins CK, Shaver DM, Arko FR, et al. Introduction of endovascular aneurysm repair into community practice: initial results with a new Food and Drug Administration-approved device. J Vasc Surg 2002;36:226-32; discussion 232-3.
1219. Trastek VF, Pairolero PC, Joyce JW, et al. Splenic artery aneurysms. Surgery 1982;91:694-9.
1220. Cohen JR, Shamash FS. Ruptured renal artery aneurysms during pregnancy. J Vasc Surg 1987;6:51-9.
1221. Ohta M, Hashizume M, Tanoue K, et al. Splenic hyperkinetic state and splenic artery aneurysm in portal hypertension. Hepatogastroenterology 1992;39:529-32.
1222. Kobori L, van der Kolk MJ, de Jong KP, et al. Splenic artery aneurysms in liver transplant patients. Liver Transplant Group. J Hepatol 1997;27:890-3.
1223. Lee PC, Rhee RY, Gordon RY, et al. Management of splenic artery aneurysms: the significance of portal and essential hypertension. J Am Coll Surg 1999;189:483-90.
1224. Carmeci C, McClenathan J. Visceral artery aneurysms as seen in a community hospital. Surg Gynecol Obstet 2000;179:486-9.
1225. Carr SC, Mahvi DM, Hoch JR, et al. Visceral artery aneurysm rupture. J Vasc Surg 2001;33:806-11.
1226. Stone WM, Abbas M, Cherry KJ, et al. Superior mesenteric artery aneurysms: is presence an indication for intervention? J Vasc Surg 2002;36:234-7; discussion 237.
1227. Tham G, Ekelund L, Herrlin K, et al. Renal artery aneurysms: natural history and prognosis. Ann Surg 1983;197:348-52.
1228. Henriksson C, Bjorkerud S, Nilson AE, et al. Natural history of renal artery aneurysm elucidated by repeated angiography and pathoanatomical studies. Eur Urol 1985;11:244-8.
1229. Hallett JW Jr. Splenic artery aneurysms. Semin Vasc Surg 1995; 8:321-6.
1230. Kasirajan K, Greenberg RK, Clair D, et al. Endovascular management of visceral artery aneurysm. J Endovasc Ther 2001; 8:150-5.
1231. Angelakis EJ, Bair WE, Barone JE, et al. Splenic artery aneurysm rupture during pregnancy. Obstet Gynecol Surv 1993;48:145-8.
1232. Salam TA, Lumsden AB, Martin LG, et al. Nonoperative management of visceral aneurysms and pseudoaneurysms. Surg Gynecol Obstet 1992;164:215-9.
1233. Carr SC, Pearce WH, Vogelzang RL, et al. Current management of visceral artery aneurysms. Surgery 1996;120:627-33; discussion 633-4.
1234. Sandgren T, Sonesson B, Ahlgren R, et al. The diameter of the common femoral artery in healthy human: influence of sex, age, and body size. J Vasc Surg 1999;29:503-10.
1235. Graham LM, Zelenock GB, Whitehouse WM Jr, et al. Clinical significance of arteriosclerotic femoral artery aneurysms. Arch Surg 1980;115:502-7.
1236. Whitehouse WM Jr, Wakefield TW, Graham LM, et al. Limb-threatening potential of arteriosclerotic popliteal artery aneurysms. Surgery 1983;93:694-9.
1237. MacSweeney ST, Skidmore C, Turner RJ, et al. Unravelling the familial tendency to aneurysmal disease: popliteal aneurysm, hypertension and fibrillin genotype. Eur J Vasc Endovasc Surg 1996;12:162-6.
1238. Lawrence PF, Lorenzo-Rivero S, Lyon JL. The incidence of iliac, femoral, and popliteal artery aneurysms in hospitalized patients. J Vasc Surg 1995;22:409-15; discussion 415-6.
1239. van Keulen CJ, van de Akker E, Pals G, et al. The role of type III collagen in the development of familial abdominal aortic aneurysms. Eur J Vasc Endovasc Surg 1999;18:65-70.
1240. Lanne T, Hansen F, Mangell P, et al. Differences in mechanical properties of the common carotid artery and abdominal aorta in healthy males. J Vasc Surg 1994;20:218-25.
1241. Makita S, Ohira A, Tachieda R, et al. Dilation and reduced distensibility of carotid artery in patients with abdominal aortic aneurysms. Am Heart J 2000;140:297-302.
1242. Tilson MD, Dang C. Generalized arteriomegaly: a possible predisposition to the formation of abdominal aortic aneurysms. Arch Surg 1981;116:1030-2.
1243. Ward AS. Aortic aneurysmal disease: a generalized dilating diathesis. Arch Surg 1992;127:990-1.
1244. Callum KG, Lea Thomas M, Browse NL. A definition of arteriomegaly and the size of arteries supplying the lower limbs. Br J Surg 1983;70:524-9.
1245. Duffy ST, Colgan MP, Sultan S, et al. Popliteal aneurysms: a 10-year experience. Eur J Vasc Endovasc Surg 1998;16:218-22.
1246. Taurino M, Calisti A, Grossi R, et al. Outcome after early treatment of popliteal artery aneurysms. Int Angiol 1998;17:28-33.
1247. Baxter BT, McGee GS, Flinn WR, et al. Distal embolization as a presenting symptom of aortic aneurysms. Surg Gynecol Obstet 1990;160:197-201.
1248. Gifford RW Jr, Hines EA Jr, Janes JM. An analysis and follow-up study of one hundred popliteal aneurysms. Surgery 1953;33:284-93. 9
1249. Dawson I, Sie RB, van Bockel JH. Atherosclerotic popliteal aneurysm. Br J Surg 1997;84:293-9.
1250. Dawson I, van Bockel JH, Brand R, et al. Popliteal artery aneurysms. Long-term follow-up of aneurysmal disease and results of surgical treatment. J Vasc Surg 1991;13:398-407.

1251. Dawson I, Sie R, van Baalen JM, et al. Asymptomatic popliteal aneurysm: elective operation versus conservative follow-up. Br J Surg 1994;81:1504-7.
1252. Lowell RC, Gloviczki P, Hallett JW Jr, et al. Popliteal artery aneurysms: the risk of nonoperative management. Ann Vasc Surg 1994;8:14-23.
1253. Schroder A, Gohlke J, Gross-Fengels W, et al. [Popliteal aneurysms—surgical management versus conservative procedure] Langenbecks Arch Chir Suppl Kongressbd 1996;113:857-63.
1254. Roggo A, Brunner U, Ottinger LW, et al. The continuing challenge of aneurysms of the popliteal artery. Surg Gynecol Obstet 1993;177:565-72.
1255. Szilagyi DE, Schwartz RL, Reddy DJ. Popliteal arterial aneurysms: their natural history and management. Arch Surg 1981;116:724-8.
1256. Poirier NC, Verdant A, Page A. [Popliteal aneurysm: surgical treatment is mandatory before complications occur] Ann Chir 1996;50:613-8.
1257. Stiegler H, Mendler G, Baumann G. Prospective study of 36 patients with 46 popliteal artery aneurysms with non-surgical treatment. Vasa 2002;31:43-6.
1258. Jivegard L, Holm J, Bergqvist D, et al. Acute lower limb ischemia: failure of anticoagulant treatment to improve one-month results of arterial thromboembolectomy: a prospective randomized multi-center study. Surgery 1991;109:610-6.
1259. Jarrett F, Makaroun MS, Rhee RY, et al. Superficial femoral artery aneurysms: an unusual entity? J Vasc Surg 2002;36:571-4.
1260. Cutler BS, Darling RC. Surgical management of arteriosclerotic femoral aneurysms. Surgery 1973;74:764-73.
1261. Roseman JM, Wyche D. True aneurysm of the profunda femoris artery. Literature review, differential diagnosis, management. J Cardiovasc Surg (Torino) 1987;28:701-5.
1262. Levi N, Schroeder TV. Blood transfusion requirement in surgery for femoral artery aneurysms. J Cardiovasc Surg (Torino) 1997; 38:661-3.
1263. Levi N, Schroeder TV. Arteriosclerotic femoral artery aneurysms: a short review. J Cardiovasc Surg (Torino) 1997; 38:335-8.
1264. Defraigne JO, Limet R. [An unusual presentation of an aortic abdominal aneurysm, source of diagnostic errors: chronic rupture] Rev Med Liege 1997;52:535-40.
1265. Farina C, Cavallaro A, Schultz RD, et al. Popliteal aneurysms. Surg Gynecol Obstet 1989;169:7-13.
1266. Anton GE, Hertzer NR, Beven EG, et al. Surgical management of popliteal aneurysms. Trends in presentation, treatment, and results from 1952 to 1984. J Vasc Surg 1986;3:125-34.
1267. Cole CW, Thijssen AM, Barber GG, et al. Popliteal aneurysms: an index of generalized vascular disease. Can J Surg 1989;32:65-8.
1268. Inahara T, Toledo AC. Complications and treatment of popliteal aneurysms. Surgery 1978;84:775-83.
1268a. Lilly MP, Flinn WR, McCarthy WJ, III, et al. The effect of distal arterial anatomy on the success of popliteal aneurysm repair. J Vasc Surg 1988;7:653-60.
1269. Reilly MK, Abbott WM, Darling RC. Aggressive surgical management of popliteal artery aneurysms. Surg Gynecol Obstet 1983;145:498-502.
1270. Schellack J, Smith RB 3rd, Perdue GD. Nonoperative management of selected popliteal aneurysms. Arch Surg 1987;122:372-5.
1271. Towne JB, Thompson JE, Patman DD, et al. Progression of popliteal aneurysmal disease following popliteal aneurysm resection with graft: a twenty year experience. Surgery 1976; 80:426-32.
1272. Graham L. Femoral and popliteal aneurysms. In: Rotherford RB, ed. Vascular Surgery. 5th ed. Philadelphia, Pa: WB Saunders; 2000:1345-56.
1273. Adiseshiah M, Bailey DA. Aneurysms of the femoral artery. Br J Surg 1977;64:174-6.
1274. Baird RJ, Gurry JF, Kellam J, et al. Arteriosclerotic femoral artery aneurysms. Can Med Assoc J 1977;117:1306-7.
1275. Sapienza P, Mingoli A, Feldhaus RJ, et al. Femoral artery aneurysms: long-term follow-up and results of surgical treatment. Cardiovasc Surg 1996;4:181-84.
1276. Feld R, Patton GM, Carabasi RA, et al. Treatment of iatrogenic femoral artery injuries with ultrasound-guided compression. J Vasc Surg 1992;16:832-40.
1277. Fellmeth BD, Roberts AC, Bookstein JJ, et al. Postangiographic femoral artery injuries: nonsurgical repair with US-guided compression. Radiology 1991;178:671-5.
1278. Johns JP, Pupa LE Jr, Bailey SR. Spontaneous thrombosis of iatrogenic femoral artery pseudoaneurysms: documentation with color Doppler and two-dimensional ultrasonography. J Vasc Surg 1991;14:24-9.
1279. Kazmers A, Meeker C, Nofz K, et al. Nonoperative therapy for postcatheterization femoral artery pseudoaneurysms. Am Surg 1997;63:199-204.
1280. Kresowik TF, Khoury MD, Miller BV, et al. A prospective study of the incidence and natural history of femoral vascular complications after percutaneous transluminal coronary angioplasty. J Vasc Surg 1991;13:328-33; discussion 333-5.
1281. Samuels D, Orron DE, Kessler A, et al. Femoral artery pseudoaneurysm: Doppler sonographic features predictive for spontaneous thrombosis. J Clin Ultrasound 1997;25:497-500.
1282. Schaub F, Theiss W, Busch R, et al. Management of 219 consecutive cases of postcatheterization pseudoaneurysm. J Am Coll Cardiol 1997;30:670-5.
1283. Toursarkissian B, Allen BT, Petrinec D, et al. Spontaneous closure of selected iatrogenic pseudoaneurysms and arteriovenous fistulae. J Vasc Surg 1997;25:803-8; discussion 808-9.
1284. Weatherford DA, Taylor SM, Langan EM, et al. Ultrasound-guided compression for the treatment of iatrogenic femoral pseudoaneurysms. South Med J 1997;90:223-6.
1285. Chatterjee T, Do DD, Mahler F, et al. A prospective, randomized evaluation of nonsurgical closure of femoral pseudoaneurysm by compression device with or without ultrasound guidance. Catheter Cardiovasc Interv 1999;47:304-9.
1286. Coghlan JG, Cowell R, Jepson N, et al. Simplified method for compression of femoral false aneurysms. Eur Heart J 1995; 16:1589-92.
1287. Cox GS, Young JR, Gray BR, et al. Ultrasound-guided compression repair of postcatheterization pseudoaneurysms: results of treatment in one hundred cases. J Vasc Surg 1994;19:683-6.
1288. Dean SM, Olin JW, Piedmonte M, et al. Ultrasound-guided compression closure of postcatheterization pseudoaneurysms during concurrent anticoagulation: a review of seventy-seven patients. J Vasc Surg 1996;23:28-34, discussion 34-5.
1289. Hajarizadeh H, LaRosa CR, Cardullo P, et al. Ultrasound-guided compression of iatrogenic femoral pseudoaneurysm failure, recurrence, and long-term results. J Vasc Surg 1995;22:425-30; discussion 430-3.
1290. Hertz SM, Brener BJ. Ultrasound-guided pseudoaneurysm compression: efficacy after coronary stenting and angioplasty. J Vasc Surg 1997;26:913-6; discussion 916-8.

1291. Kumins NH, Landau DS, Montalvo J, et al. Expanded indications for the treatment of postcatheterization femoral pseudoaneurysms with ultrasound-guided compression. Surg Gynecol Obstet 1998;176:131-6.
1292. Langella RL, Schneider JR, Golan JF. Color duplex-guided compression therapy for postcatheterization pseudoaneurysms in a community hospital. Ann Vasc Surg 1996;10:27-35.
1293. Paulson EK, Kliewer MA, Hertzberg BS, et al. Ultrasonographically guided manual compression of femoral artery injuries. J Ultrasound Med 1995;14:653-9.
1294. Perkins JM, Gordon AC, Magee TR, et al. Duplex-guided compression of femoral artery false aneurysms reduces the need for surgery. Ann R Coll Surg Engl 1996;78:473-5.
1295. Sorrell KA, Feinberg RL, Wheeler JR, et al. Color-flow duplex-directed manual occlusion of femoral false aneurysms. J Vasc Surg 1993;17:571-7.
1296. Steinkamp HJ, Werk M, Felix R. Treatment of postinterventional pseudoaneurysms by ultrasound-guided compression. Invest Radiol 2000;35:186-92.
1297. Edgerton JR, Moore DO, Nichols D, et al. Obliteration of femoral artery pseudoaneurysm by thrombin injection. Ann Thorac Surg 2002;74:S1413-5.
1298. Olsen DM, Rodriguez JA, Vranic M, et al. A prospective study of ultrasound scan-guided thrombin injection of femoral pseudoaneurysm: a trend toward minimal medication. J Vasc Surg 2002;36:779-82.
1299. La Perna L, Olin JW, Goines D, et al. Ultrasound-guided thrombin injection for the treatment of postcatheterization pseudoaneurysms. Circulation 2000;102:2391-5.
1300. Mohler ER III, Mitchell ME, Carpenter JP, et al. Therapeutic thrombin injection of pseudoaneurysms: a multicenter experience. Vasc Med 2001;6:241-4.
1301. Friedman SG, Pellerito JS, Scher L, et al. Ultrasound-guided thrombin injection is the treatment of choice for femoral pseudoaneurysms. Arch Surg 2002;137:462-4.
1302. Lonn L, Olmarker A, Geterud K, et al. Treatment of femoral pseudoaneurysms. Percutaneous US-guided thrombin injection versus US-guided compression. Acta Radiol 2002;43:396-400.
1303. Hughes MJ, McCall JM, Nott DM, et al. Treatment of iatrogenic femoral artery pseudoaneurysms using ultrasound-guided injection of thrombin. Clin Radiol 2000;55:749-51.
1304. Kang SS, Labropoulos N, Mansour MA, et al. Expanded indications for ultrasound-guided thrombin injection of pseudoaneurysms. J Vasc Surg 2000;31:289-98.
1305. Liau CS, Ho FM, Chen MF, et al. Treatment of iatrogenic femoral artery pseudoaneurysm with percutaneous thrombin injection. J Vasc Surg 1997;26:18-23.
1306. Reeder SB, Widlus DM, Lazinger M. Low-dose thrombin injection to treat iatrogenic femoral artery pseudoaneurysms. AJR Am J Roentgenol 2001;177:595-8.
1307. Sackett WR, Taylor SM, Coffey CB, et al. Ultrasound-guided thrombin injection of iatrogenic femoral pseudoaneurysms: a prospective analysis. Am Surg 2000;66:937-40; discussion 940-2.
1308. Taylor BS, Rhee RY, Muluk S, et al. Thrombin injection versus compression of femoral artery pseudoaneurysms. J Vasc Surg 1999;30:1052-9.